



Natural Infection of a Great Egret (*Casmerodius albus*) with Eastern Equine Encephalitis Virus

Authors: Gottdenker, Nicole L., Howerth, Elizabeth W., and Mead, Daniel G.

Source: Journal of Wildlife Diseases, 39(3) : 702-706

Published By: Wildlife Disease Association

URL: <https://doi.org/10.7589/0090-3558-39.3.702>

BioOne Complete (complete.BioOne.org) is a full-text database of 200 subscribed and open-access titles in the biological, ecological, and environmental sciences published by nonprofit societies, associations, museums, institutions, and presses.

Your use of this PDF, the BioOne Complete website, and all posted and associated content indicates your acceptance of BioOne's Terms of Use, available at www.bioone.org/terms-of-use.

Usage of BioOne Complete content is strictly limited to personal, educational, and non - commercial use. Commercial inquiries or rights and permissions requests should be directed to the individual publisher as copyright holder.

BioOne sees sustainable scholarly publishing as an inherently collaborative enterprise connecting authors, nonprofit publishers, academic institutions, research libraries, and research funders in the common goal of maximizing access to critical research.

Natural Infection of a Great Egret (*Casmerodius albus*) with Eastern Equine Encephalitis Virus

Nicole L. Gottdenker,¹ Elizabeth W. Howerth,^{1,2} and Daniel G. Mead¹ ¹ Southeastern Cooperative Wildlife Disease Study, College of Veterinary Medicine, The University of Georgia, Athens, Georgia 30602-7393, USA; ² Corresponding author (email: ehowerth@vet.uga.edu)

ABSTRACT: In July 2001, a great egret (*Casmerodius albus*) was found dead in Charlton County, Georgia (USA) and submitted to the Southeastern Cooperative Wildlife Disease Study (The University of Georgia, Athens, Georgia). Histopathologic findings included severe hepatic necrosis and necrosis of sheathed arterioles. Eastern equine encephalitis (EEE) virus was isolated from brain and heart using Vero cells and was identified using a standard micro-neutralization test and reverse transcription polymerase chain reaction (rtPCR). Streptavidin-biotin alkaline phosphatase immunohistochemistry using mouse anti-EEE virus monoclonal antibody demonstrated EEE antigen within cells of the sheathed arterioles and scattered mononuclear cells in the splenic parenchyma. To the authors' knowledge, this is the first description of natural infection and pathologic effects of EEE virus infection in a great egret.

Key words: Alphavirus, *Casmerodius albus*, eastern equine encephalitis virus, *Togaviridae*, egret, immunohistochemistry, hepatitis, splenitis.

Eastern equine encephalitis (EEE), caused by an alphavirus in the family *Togaviridae*, is an important vector-borne disease of birds, horses, and humans. The virus occurs in North America, Central America and the Caribbean, and South America. In temperate regions, EEE virus transmission peaks in late summer and early autumn, but in tropical and subtropical regions, transmission can occur at any time during the year (Komar et al., 1999; Weaver et al., 1999). *Culiseta melanura*, an ornithophilic mosquito, is the primary vector of EEE virus in North America, and the virus is maintained in a bird and mosquito cycle. Sporadic epizootics can result in disease in birds, horses, and humans (Morris, 1988; Gibbs and Tsai, 1994; Komar et al., 1999; Weaver et al., 1999). Birds, such as wading birds that roost near wetland breeding sites for *C. melanura*, may be particularly important for viral maintenance (Komar et al., 1999).

In birds, EEE virus can infect and cause disease and/or death in turkeys, and introduced species such as ring-necked pheasants (*Phasianus colchicus*), rock doves (*Columba livia*), emus (*Dromaius novaehollandiae*), ostriches, chukar partridges (*Alectoris chukar*), and house sparrows (*Passer domesticus*) (Karstad et al., 1959; Williams et al., 1971; Morris, 1988; Brown et al., 1993). Many species of free-ranging Ciconiiformes, including great blue herons (*Ardea herodias*), roseate spoonbills (*Ajaja ajaja*), great egrets (*Casmerodius albus*), little blue herons (*Egretta caerulea*), wood storks (*Mycteria americana*), and cattle egrets (*Bubuleus ibis*), have been reported to be seropositive or infected with EEE virus (Kissling et al., 1954; Favorite, 1960; Bigler et al., 1975; Spalding et al., 1994). In general, EEE virus is not believed to be highly pathogenic in birds native to North America. However, EEE virus has caused mortality in native birds representing the orders Gruidae and Icteridae (Kissling et al., 1954; Dein et al., 1986; Spalding et al., 1994; McClean et al., 1995). The following report describes the diagnosis and pathologic features of natural eastern equine encephalitis virus infection in a great egret.

A great egret from Charlton County, Georgia (USA; 30°52'N, 82°15'W) was submitted in July, 2001 to the Southeastern Cooperative Wildlife Disease Study (University of Georgia, Athens, Georgia), for West Nile virus (WNV) testing. A gross necropsy was performed and representative samples from brain, liver, heart, lungs, trachea, spleen, kidney, skeletal muscle, adrenal glands, gastrointestinal tract, and integument were preserved in 10% buffered formalin for histopathologic and immunohistochemical analysis. Samples of

brain and heart were collected in BA-1 (Hanks M-199 salts, 0.05M Tris pH 7.6, 1% bovine serum albumin, 0.35 g/l sodium bicarbonate, 100 units/ml penicillin, 100 mg/ml streptomycin, 1 mg/ml Fungizone) media for virus isolation (Langevin et al., 2001).

For immunohistochemistry, 3 μ m paraffin sections were deparaffinized and rehydrated. Sections were incubated with Protease 2 (Ventana, Tucson, Arizona, USA) for 3 min at room temperature for antigen retrieval and then blocked for 8 min at room temperature with Universal Blocking Reagent (BioGenex, San Ramon, California, USA). Sections were then incubated with either a mouse anti-eastern equine encephalitis virus monoclonal antibody (1:100 dilution) (Chemicon International, Temecula, California), or rabbit anti-WNV antibody (1:500) (BioReliance, Rockville, Maryland, USA), or mouse or rabbit negative control serum (Dako, Carpinteria, California), for 1 hr at room temperature. A streptavidin-biotin alkaline phosphatase kit (BioGenex) was used for detection. Sections were incubated with biotinylated supersensitive mouse or rabbit link, depending on the primary antibody, for 20 min at room temperature, followed by supersensitive avidin label for 20 min, and then fast red (Dako) was applied as the chromagen. Sections were counterstained with hematoxylin. The positive control was EEE virus infected cell culture that was formalin fixed, pelleted and enrobed in agar, and then embedded in paraffin. The positive control for WNV was formalin fixed, paraffin embedded tissue from a WNV positive bird. For negative controls, duplicate sections were incubated with mouse or rabbit negative control serum (Dako) in place of the anti-EEE virus or anti-WNV virus antibodies, respectively.

Sections of brain and heart were macerated in BA-1 media for virus isolation. The mixture was clarified by light centrifugation and the resulting supernatant fluid was used as the cell culture inoculum. A 0.1 ml portion from each sample was

inoculated onto separate wells of a 12 well plate with confluent 2 day old Vero cell culture monolayers and incubated at 37 C in 5% CO₂ atmosphere. Cell culture monolayers were examined daily for evidence of cytopathic effects. Cytopathic effects were evident for both samples within 24 hr. Aliquots (0.5 ml) of each sample were filtered through 2 μ m syringe filters, and filtrates were inoculated onto 2 day old Vero cells and re-incubated. Cytopathic effects were again observed within 24 hr. The samples were plaque purified and the virus was identified as EEE virus by a standard micro-neutralization test (National Veterinary Services Laboratory, 1981) using EEE virus specific antiserum and by reverse transcription polymerase chain reaction using EEE viral RNA specific primers (Huang et al., 2001). Samples tested negative for WNV using reverse transcription polymerase chain reaction with WNV RNA specific primers.

Gross findings in this bird included multifocal pallor of the heart, mild pericardial effusion, cerebral reddening, and a shrunken liver. Histologic lesions were apparent in the liver, spleen, and lungs. There was necrotizing inflammation in over 75% of the liver, consisting of dissociation of hepatic cords, including rounding of hepatocytes, nuclear pyknosis and loss of nuclei of many hepatocytes, increased cytoplasmic eosinophilia and granularity of many hepatocytes with nuclear pyknosis, and multifocal apoptotic hepatocytes (Fig. 1). Inflammatory infiltrates were randomly distributed throughout the parenchyma and consisted of moderate numbers of heterophils, lymphocytes, and few histiocytes. There were few hemosiderin-laden macrophages within hepatic sinusoids. In the spleen, sheathed arterioles were markedly expanded by pale eosinophilic homogenous to fibrillar material, and nuclei were pyknotic (Fig. 2). There were also random infiltrates of moderate numbers of heterophils in the splenic parenchyma. The lung had diffuse, severe congestion and multifocal parabronchial

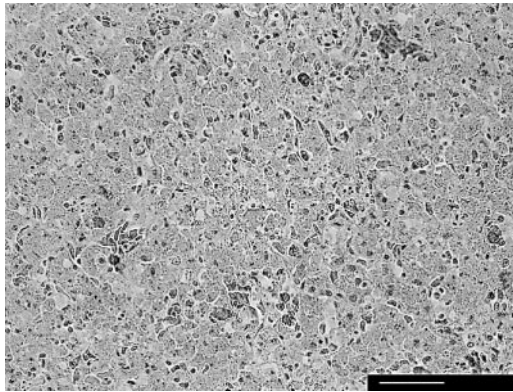


FIGURE 1. Photomicrograph of great egret liver with dissociation of hepatocytes, hepatic necrosis, and multifocal apoptotic hepatocytes. Bar=40 μ m. HE stain.

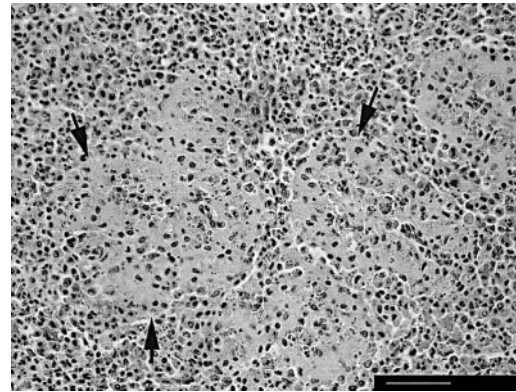


FIGURE 2. Photomicrograph of great egret spleen demonstrating cellular necrosis of periarteriolar sheaths. Bar=40 μ m. HE stain.

hemorrhage. Multifocal, mild hemorrhage was present in the brain. Positive immunohistochemical staining for EEE antigen was present in the spleen only. There was intense cytoplasmic staining of cells of the sheathed arterioles and scattered mononuclear cells in the splenic parenchyma (Fig. 3). Brain, spleen, heart, kidney, lung, intestine, and liver tissue did not stain for WNV antigen by immunohistochemistry.

Differential diagnoses for the gross and histopathologic findings in this bird included EEE, western equine encephalitis (WEE), Venezuelan equine encephalitis (VEE), WNV infection, Newcastle disease, and avian influenza. Based on viral isolation, PCR, histopathology, and immunohistochemistry, EEE was determined to be the cause of this egret's lesions.

Although many birds may become infected with the EEE virus (Karstad et al., 1959; Stamm, 1963), there is marked species variation in disease-related mortality (Komar et al., 1999). In natural infections, EEE virus causes relatively high mortality in whooping cranes (*Grus americana*). In 1984, an epizootic of EEE virus killed seven of 39 whooping cranes at the Patuxent Wildlife Research Center in Maryland (Dein et al., 1986; Pagac et al., 1992). Most experimentally infected glossy ibises (*Plegadis falcinellus*) and snowy egrets

(*Egretta thula*), became viremic, with high mortality in infected ibises (McLean et al., 1995). When bobwhite quail (*Colinus virginianus*) and white-throated sparrows (*Zonotrichia albicollis*) were experimentally infected, they had a high survival rate, whereas red-winged blackbirds (*Agelaius phoeniceus*), house sparrows, cowbirds (*Molothrus ather*), and grackles (*Quiscalus quiscula*) had relatively higher mortality (Williams et al., 1971). Experimental infections of starlings (*Sturnus vulgaris*) and robins (*Turdus migratorius*) with EEE virus demonstrated that mortality corre-

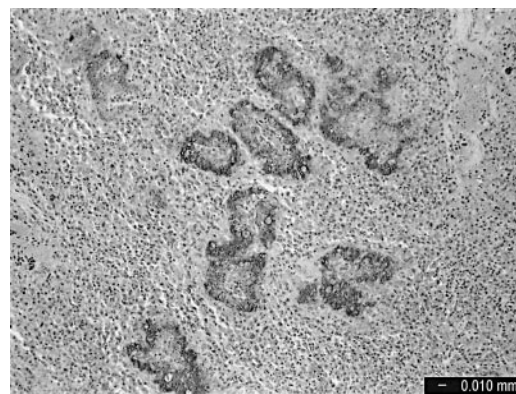


FIGURE 3. Photomicrograph of a section of a great egret spleen with intense staining of the splenic arteriolar sheaths for EEE viral antigen. Immunohistochemistry for EEE virus, streptavidin-biotin alkaline phosphatase method with fast red chromagen. Bar=0.010 mm.

sponded with peak viremia and that starlings seemed more susceptible to EEE-related death (Komar et al., 1999).

Histopathologic features of EEE virus infection also vary among species. In some avian species infected with EEE virus, neuropathology is the most significant finding. In ring-necked pheasants, infection with EEE virus causes nonsuppurative encephalitis with vasculitis as well as meningitis (Williams et al., 2000). Chukar partridges also develop encephalitis when infected with EEE virus (Ranck, 1965). Neurologic lesions caused by EEE virus are inconsistently seen in chickens (Guy et al., 1994b). However, in this great egret, there were no neurologic lesions.

Visceral lesions in the relative absence of neurologic pathology as seen in this case are also commonly reported in other avian species. Eastern equine encephalitis virus infection in emus causes multiple organ hemorrhage, hepatocellular necrosis, lymphoid necrosis, and necrotizing vasculitis in the spleen, with necrosis of endothelial cells (Tully et al., 1992; Veazey et al., 1994). Whooping cranes with EEE virus infection develop necrosis of the spleen, liver, lung, intestines, kidney, adrenal gland, lung, and gonads in the absence of neurologic lesions (Dein et al., 1986). Domestic turkeys experimentally infected with EEE exhibit lymphocyte necrosis and depletion in bursa, thymus, spleen, and acinar pancreatic necrosis but no central nervous system lesions (Ficken et al., 1993; Guy et al., 1993). Severe myocardial necrosis, hepatitis, and lymphoid necrosis, with lymphoid depletion in the thymus, spleen, and bursa fabricius were observed in broiler chickens experimentally infected with EEE virus (Guy et al., 1994a). Additional lesions reported to occur in birds with EEE viral infection, but not seen in this great egret, include hemorrhagic enterocolitis in emus (Brown et al., 1993) and myocarditis in broiler chickens (Guy et al., 1994a) and chukar partridges (Ranck et al., 1965).

In this great egret, positive staining for

EEE viral antigen in the spleen correlated with necrosis of sheathed arterioles. However, areas of hepatocellular necrosis and inflammation did not stain positively for viral antigen. Thus, hepatic necrosis may have been due to secondary release of chemokines or cytokines, such as tumor necrosis factor by infected cells in the spleen, rather than a direct result of viral infection (Decker, 1993; Schmauder-Chock et al., 1994; Okuaki et al., 1996).

Explanations for apparent species differences in pathologic manifestations of EEE virus infection include: genetic differences in susceptibility to infection and immunologic response to viral infection, naïveté to viral infection in non-native birds, exposure to different viral strains varying in pathogenicity, differences in exposure to infected mosquito vectors due to variations in habitat use and behavioral ecology, and variations in weather conditions at different sites that either favor or minimize probabilities of infection. Further serologic and pathologic surveillance is necessary to elucidate causes for and manifestations of EEE virus infection in wild birds.

Work was supported primarily by the Georgia Department of Human Resources, Division of Public Health (427-93-25328). Further support was provided by the Federal Aid to Wildlife Restoration Act (50 Stat. 917) and through sponsorship from fish and wildlife agencies in Alabama, Arkansas, Florida, Georgia, Kansas, Kentucky, Louisiana, Maryland, Mississippi, Missouri, North Carolina, Oklahoma, Puerto Rico, South Carolina, Tennessee, Virginia, and West Virginia.

LITERATURE CITED

- BIGLER, W. J., E. LASSING, E. BUFF, A. L. LEWIS, AND L. HOFF. 1975. Arbovirus surveillance in Florida: Wild vertebrate studies 1965–1974. *Journal of Wildlife Diseases* 11: 348–356.
- BROWN, T. P., W. ROBERTS, AND R. K. PAGE. 1993. Acute hemorrhagic enterocolitis in ratites: Isolation of eastern equine encephalomyelitis virus and reproduction of the disease in ostriches and turkey poults. *Avian Diseases* 37: 602–605.

- DECKER, K. 1993. Mechanisms and mediators in hepatic necrosis. *Gastroenterologia Japonica* 28: 20–25.
- DEIN, F. J., J. W. CARPENTER, G. C. CLARK, R. J. MONTALI, C. L. CRABBS, T. F. TSAI, AND D. E. DOCHERTY. 1986. Mortality of captive whooping cranes caused by eastern equine encephalitis virus. *Journal of the American Veterinary Medical Association*. 189: 1006–1010.
- FAVORITE, F. G. 1960. Some evidence of local origin of EEE virus in Florida. *Mosquito News* 20: 87–92.
- FICKEN, M. D., D. P. WAGES, J. S. GUY, J. A. QUINN, AND W. H. EMORY. 1993. High mortality of domestic turkeys associated with highlands J virus and eastern equine encephalitis virus infections. *Avian Diseases* 37: 585–590.
- GIBBS, E. P. J., AND T. F. TSAI. 1994. Eastern encephalitis. In *Handbook of zoonoses*, 2nd Edition, Section B. Viral, G. W. Beran (ed.). CRC Press Inc., Boca Raton, Florida, pp. 11–24.
- GUY, J. S., M. D. FICKEN, J. H. BARNES, D. P. WAGES, AND L. G. SMITH. 1993. Experimental infection of young turkeys with eastern equine encephalitis virus and highlands J virus. *Avian Diseases* 37: 389–395.
- , J. H. BARNES, AND L. G. SMITH. 1994a. Experimental infection of young broiler chickens with eastern equine encephalitis virus and highlands J virus. *Avian Diseases* 38: 572–582.
- , ———, M. D. FICKEN, L. G. SMITH, W. H. EMORY, AND D. P. WAGES. 1994b. Decreased egg production in turkeys experimentally infected eastern equine encephalitis virus or highlands J virus. *Avian Diseases* 38: 563–71.
- HUANG, C., B. SLATER, W. CAMPBELL, J. HOWARD, AND D. WHITE. 2001. Detection of arboviral RNA directly from mosquito homogenates by reverse-transcription-polymerase chain reaction. *Journal of Virological Methods* 94: 121–128.
- KARSTAD, L., J. SPALATIN, AND R. B. HANSON. 1959. Experimental infections of wild birds with the viruses of eastern equine encephalitis, Newcastle disease, and vesicular stomatitis. *Journal of Infectious Diseases* 105: 188–195.
- KISSLING, R. E., R. W. CHAMBERLAIN, R. K. SIKES, AND M. E. EIDSON. 1954. Studies on the North American arthropod-borne encephalitides. II. Eastern equine encephalitis studies in wild birds. *The American Journal of Hygiene* 60: 251–265.
- KOMAR, N., D. J. DOHM, M. J. TURRELL, AND A. SPIELMAN. 1999. Eastern equine encephalitis virus in birds: Relative competence of European starlings (*Sturnus vulgaris*). *American Journal of Tropical Medicine and Hygiene* 60: 387–391.
- LANGEVIN, S. A., M. BUNNING, B. DAVIS, AND N. KOMAR. 2001. Experimental infection of chickens as candidate sentinels for West Nile virus. *Emerging Infectious Diseases* 7: 726–729.
- MCLEAN, R. G., W. J. CRANS, D. F. CACCAMISE, J. MCNELLY, L. J. KIRK, C. J. MITCHEL, AND C. H. CALISHER. 1995. Experimental infection of wading birds with eastern equine encephalitis virus. *Journal of Wildlife Diseases* 31: 502–508.
- MORRIS, C. D. 1988. Eastern equine encephalitis. In *The arboviruses: Epidemiology and ecology*, Vol. III, T. P. Monath (ed.). CRC Press, Boca Raton, Florida, pp. 1–20.
- OKUAKI, Y., H. MIYAZAKI, M. ZENIYA, T. ISHIKAWA, Y. OHKAWA, S. TSUNO, M. SAKAGUCHI, M. HARA, AND H. TAKAHASHI. 1996. Splenectomy-reduced hepatic injury induced by ischemia/reperfusion in the rat. *Liver* 16: 188–194.
- PAGAC, B. B., M. J. TURELL, AND G. H. OLSEN. 1992. Eastern equine encephalomyelitis virus and *Culiseta melanura* activity at the Patuxent Wildlife Research Center, 1985–1990. *Journal of the American Mosquito Control Association* 8: 328–330.
- RANCK, F. M., J. H. GAINER, J. E. HANLEY, AND S. L. NELSON. 1965. Natural outbreak of eastern and western encephalitis in pen-raised chukars in Florida. *Avian Diseases* 9: 8–20.
- SCHMAUDER-CHOCK, E. A., S. P. CHOCK, AND M. L. PATCHEN. 1994. Ultrastructural localization of tumor necrosis factor-alpha. *Histochemical Journal* 26: 142–151.
- SPALDING, M. G., R. G. MCLEAN, J. H. BURGESS, AND L. J. KIRK. 1994. Arboviruses in water birds (*Ciconiiformes*, *Pelecaniformes*) from Florida. *Journal of Wildlife Diseases* 30: 216–221.
- STAMM, D. D. 1963. Susceptibility of bird populations to eastern, western, and St. Louis encephalitis viruses. In *Proceedings of the XIII International Ornithological Congress*, C. G. Sibley (ed.). Australian Academy of Science, Canberra, pp. 591–603.
- TULLY, T. N., S. M. SHANE, R. P. POSTON, J. J. ENGLAND, C. C. VICE, D. Y. CHO, AND B. PANIGRAHY. 1992. Eastern equine encephalitis in a flock of emus (*Dromaius novaehollandiae*). *Avian Diseases* 36: 808–812.
- VEAZEY, R. S., C. C. VICE, D. Y. CHO, T. N. TULLY, JR., AND S. M. SHANE. 1994. Pathology of eastern equine encephalitis in emus. *Veterinary Pathology* 31: 111–115.
- WEAVER, S. C., A. M. POWERS, A. C. BRAULT, AND A. D. T. BARRETT. 1999. Molecular epidemiological studies of veterinary arboviral encephalitides. *The Veterinary Journal* 157: 122–138.
- WILLIAMS, J. E., O. P. YOUNG, D. M. WATTS, AND T. J. REED. 1971. Wild birds as eastern (EEE) and western (WEE) equine encephalitis sentinels. *Journal of Wildlife Diseases* 7: 188–194.
- WILLIAMS, S. M., R. M. FULTON, J. S. PATTERSON, AND W. M. REED. 2000. Diagnosis of eastern equine encephalitis by immunohistochemistry in two flocks of Michigan ring-neck pheasants. *Avian Diseases*: 1012–1016.

Received for publication 25 November 2002.