

AEROSOL EXPOSURE OF WHITE-TAILED DEER (ODOCOILEUS VIRGINIANUS) TO MYCOBACTERIUM BOVIS

Authors: Palmer, Mitchell V., Waters, W. Ray, and Whipple, Diana L.

Source: Journal of Wildlife Diseases, 39(4) : 817-823

Published By: Wildlife Disease Association

URL: <https://doi.org/10.7589/0090-3558-39.4.817>

BioOne Complete (complete.BioOne.org) is a full-text database of 200 subscribed and open-access titles in the biological, ecological, and environmental sciences published by nonprofit societies, associations, museums, institutions, and presses.

Your use of this PDF, the BioOne Complete website, and all posted and associated content indicates your acceptance of BioOne's Terms of Use, available at www.bioone.org/terms-of-use.

Usage of BioOne Complete content is strictly limited to personal, educational, and non - commercial use. Commercial inquiries or rights and permissions requests should be directed to the individual publisher as copyright holder.

BioOne sees sustainable scholarly publishing as an inherently collaborative enterprise connecting authors, nonprofit publishers, academic institutions, research libraries, and research funders in the common goal of maximizing access to critical research.

AEROSOL EXPOSURE OF WHITE-TAILED DEER (*ODOCOILEUS VIRGINIANUS*) TO *MYCOBACTERIUM BOVIS*

Mitchell V. Palmer,^{1,2} W. Ray Waters,¹ and Diana L. Whipple¹

¹Bacterial Diseases of Livestock Research Unit, National Animal Disease Center, Agricultural Research Service, United States Department of Agriculture, 2300 Dayton Avenue, Ames, Iowa, 50010, USA

²Corresponding author (email: mpalmer@nadc.ars.usda.gov)

ABSTRACT: Tuberculosis due to *Mycobacterium bovis* affects both captive and free-ranging Cervidae in the United States. Various animal models have been developed to study tuberculosis of both humans and animals. Generally, tuberculosis is transmitted by aerosol and oral routes. Models of aerosol exposure of large animals to *M. bovis* are uncommon. In order to develop a reliable method of aerosol exposure of white-tailed deer (*Odocoileus virginianus*) to *M. bovis*, 12 healthy white-tailed deer, aged 8–10 mo, were infected by aerosol exposure to 2×10^5 to 1×10^6 colony forming units (CFU) (high dose, $n=4$) of *M. bovis* or 6×10^2 to 1.6×10^3 CFU (low dose, $n=8$) of *M. bovis*. Tuberculous lesions were more widely disseminated in deer receiving the high dose, while lesions in deer receiving the low dose were more focused on the lungs and associated lymph nodes (tracheobronchial and mediastinal). Aerosol delivery of *M. bovis* to white-tailed deer results in a reliable manner of experimental infection that may be useful for studies of disease pathogenesis, immune response, mycobacterial shedding, and vaccine efficacy.

Key words: Aerosol, *Mycobacterium bovis*, *Odocoileus virginianus*, tuberculosis, white-tailed deer.

INTRODUCTION

Tuberculosis due to *Mycobacterium bovis* in captive Cervidae was identified as an important disease in the USA in 1990 and prompted addition of captive Cervidae to the United States Department of Agriculture Uniform Methods and Rules (UM&R; United States Department of Agriculture, 1999) for its eradication. In 1994 a free-ranging white-tailed deer (*Odocoileus virginianus*) in Michigan (USA) was diagnosed with tuberculosis due to *M. bovis* (Schmitt et al., 1997). Subsequent surveys conducted by the Michigan Department of Natural Resources and Michigan State University Animal Health Diagnostic Laboratory (Lansing, Michigan) identified a focus of *M. bovis* infection in free-ranging white-tailed deer in northeast Michigan (Schmitt et al., 1997; O'Brien et al., 2001). Tuberculosis in both captive and free-ranging Cervidae represents a serious challenge to eradication of *M. bovis* infection from the USA. Other countries with wildlife reservoirs of tuberculosis such as New Zealand and Great Britain have been unable to eradicate *M. bovis*. Little is known concerning pathogenesis and trans-

mission of tuberculosis in white-tailed deer. Development of diagnostic tests, vaccines, or other tools that may be used in disease control programs will require improved understanding of tuberculosis in white-tailed deer.

Various animal models have been developed to study human and animal tuberculosis (Buchan and Griffin, 1990; Dannenburg, 1994; McMurray, 1994; Orme and Collins, 1994; Palmer et al., 1999). Routes of experimental infection of laboratory animals include intravenous, intranasal, intratracheal, intratonsillar, oral, and aerosol. The primary means of transmission of *Mycobacterium tuberculosis* in humans is by aerosol and thus results in pulmonary lesions. Human infection with *M. bovis* can result in pulmonary lesions indistinguishable from those caused by *M. tuberculosis*; however in humans, *M. bovis* often results in non-pulmonary lesions, such as cervical lymphadenitis, due to oral exposure through consumption of milk containing *M. bovis* (Grange and Yates, 1994).

It is generally accepted that deer become infected with *M. bovis* by either oral or respiratory routes. To simulate natural

disease, experimental infection of deer has been done by intratonsillar and oral routes (Buchan and Griffin, 1990; Palmer et al., 1999, 2002a). Although aerosol delivery has been used in small animal models of tuberculosis, due to obvious limitations and obstacles, experimental aerosol delivery of *M. bovis* to large animals has only recently been reported (Palmer et al., 2002b). Objectives of this study were to develop and characterize a model of aerosol exposure of deer to *M. bovis* and to compare distribution of lesions to those reported in naturally infected white-tailed deer.

MATERIALS AND METHODS

Animals

Twelve, healthy, white-tailed deer (females and castrated males) 8–10 mo of age, were obtained from a tuberculosis free research herd at the National Animal Disease Center (Ames, Iowa, USA) and randomly assigned to one of two groups. One group (high dose, $n=4$) was infected with 2×10^5 to 1×10^6 colony forming units (CFU) of *M. bovis* strain 1315, originally isolated in 1995 from the medial retropharyngeal lymph node of a hunter-killed white-tailed deer in Michigan. The other group (low dose, $n=8$) was infected with 6×10^2 to 1.6×10^3 CFU of *M. bovis* strain 1315. Challenge inoculum consisted of mid-log-phase *M. bovis* grown in Middlebrook's 7H9 media supplemented with 10% oleic acid-albumin-dextrose complex (OADC, Difco, Detroit, Michigan) plus 0.05% Tween 80 (Sigma Chemical Co., St. Louis, Missouri, USA) as described (Bolin et al., 1997). To harvest tubercle bacilli from the culture media, bacteria were pelleted by centrifugation at $750 \times G$, washed twice with phosphate-buffered saline solution (PBS, 0.01 M, pH 7.2), and diluted to the appropriate density for use as inoculum in 2 ml of PBS. Inoculum was sonicated for 5 sec prior to nebulization to disperse clumps of bacteria. Enumeration of bacilli was by serial dilution plate counting on Middlebrook's 7H11 selective media (Becton Dickinson, Cockeysville, Maryland, USA).

Experimental infection

For aerosol exposure, deer were chemically restrained by intramuscular injection of a combination of xylazine (2 mg/kg; Mobay Corporation, Shawnee, Kansas, USA) and ketamine (6 mg/kg; Fort Dodge Laboratories, Fort

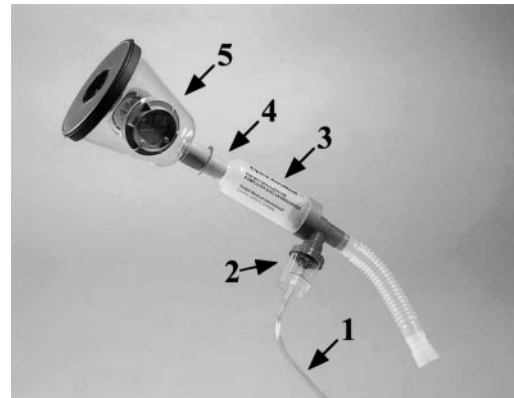


FIGURE 1. Aerosol delivery apparatus used to deliver *M. bovis* to white-tailed deer. Hose (1) is attached to tank of compressed air used to aerosolize inoculum within a jet nebulizer (2). Aerosolized inoculum passes into holding chamber (3) until inhaled through one-way valve (4) into mask that is tightly sealed around muzzle using a rubber gasket (5).

Dodge, Iowa). After infection, the effects of xylazine were reversed by intravenous injection of tolazoline (4 mg/kg; Lloyd Laboratories, Shenandoah, Iowa). The nebulization apparatus consisted of a compressed air tank and commercially available aerosol delivery system (Fig. 1) (Equine Aeromask, Trudell Medical, London, Ontario, Canada) comprised of a jet nebulizer (Whisper Jet, Marquest Medical Products, Englewood, Colorado, USA), holding chamber, and mask. According to the manufacturer, in studies using 0.9% saline, the Whisper Jet nebulizer produces a particle size with a mass median aerodynamic diameter of $1.91 \mu\text{m}$ with an output of 0.24 ml/min at a flow rate of 8 l per min (lpm) and 3.5 kg per cm^2 . A separate study comparing the nebulization of albuterol by various brands of nebulizers, found that at a flow rate of 2.0 lpm the Whisper Jet nebulizer produced a particle with approximately $5 \mu\text{m}$ diameter (Hess et al., 1996). Compressed air (1.75 kg/cm^2) was used to jet nebulize inoculum (2 ml *M. bovis* in PBS) directly into the holding chamber. Upon inspiration, the nebulized inoculum was inhaled through a one way valve into the mask and directly into the nostrils. A rubber gasket sealed the mask securely to the muzzle preventing leakage of inoculum around the mask. Expired air exited through one-way valves on the sides of the mask. The nebulization process continued until all of the inoculum, a 1 ml PBS wash of the inoculum tube, and an additional 2 ml PBS were delivered (approximately 12 min). Experimental infection was done inside a bio-safety level 3 (BL-3) building with personnel

wearing appropriate personal protective equipment, including full-face respirators with HEPA filtered canisters to prevent exposure to aerosolized *M. bovis*. The BL-3 animal housing had negative air pressure as compared to the outside. Airflow was adjusted to produce 11.4 air changes per hr and designed such as to prevent air exchange between rooms. Deer were housed four per pen (11 m²) according to treatment group in facilities approved by the Association for the Assessment and Accreditation of Laboratory Animal Care International (AAALAC). No clinical parameters (e.g., blood values, body weight, etc.) were routinely monitored. Deer were observed twice daily by animal care or veterinary staff when the animal's general appearance and feed consumption were subjectively evaluated. A protocol detailing procedures and animal care was approved by the Institutional Animal Care and Use Committee (IACUC) prior to the beginning of the experiment.

Sample collection

Eighty days after infection, deer in the high dose group were euthanized by intravenous injection of sodium pentobarbital due to poor condition, weight loss, rough hair coat, infrequent coughing, anorexia, and reluctance to rise when approached. One hundred and eight days after infection, all deer in the low dose group were also euthanized as scheduled in the experimental protocol. Clinical signs such as those described above in deer receiving the high dose of inoculum were not seen in deer receiving the low dose of inoculum. A thorough postmortem examination was done on each animal and the following tissues collected for bacteriologic isolation of *M. bovis* and microscopic analysis: palatine tonsil; mandibular, parotid, medial retropharyngeal, tracheobronchial, mediastinal, mesenteric, and hepatic lymph nodes; lung; and liver. Tissues were processed for isolation of *M. bovis* as previously described (Palmer et al., 1999). Isolates of *M. bovis* were identified by colony morphology, growth, and biochemical characteristics as well as a DNA probe specific for mycobacteria in the *M. tuberculosis* complex (AccuProbe; Gen-Probe Inc., San Diego, California, USA). Tissues collected for microscopic examination were fixed by immersion in 10% neutral buffered formalin, processed by routine methods to paraffin wax and sectioned (5 µm). Sections were stained with hematoxylin and eosin (HE) for microscopic examination. Adjacent sections were cut from samples containing lesions suggestive of tuberculosis and stained by the Ziehl-

Neelsen technique for visualization of acid-fast bacteria.

Tuberculin skin testing

Ninety days after infection, all deer in the low dose group were tested for exposure to *M. bovis* by the comparative cervical test (CCT) for Cervidae (United States Department of Agriculture, 1999). Briefly, hair was clipped from two sites on the right side of the midcervical region and thickness of the skin at each site was measured. One-tenth ml (0.4 mg/ml) of *M. avium* purified protein derivative (PPD; National Veterinary Services Laboratories, Ames, Iowa) was injected intradermally in the uppermost site and 0.1 ml (1 mg/ml) of *M. bovis* PPD (National Veterinary Services Laboratories) was injected into the lower site. Seventy-two hours after injection, test sites were observed, palpated, and induration measured to the nearest 0.5 mm using calipers. Results were interpreted by plotting measurements of changes in skin thickness at both the *M. bovis* PPD and *M. avium* PPD injection sites on a scattergram for interpretation of the CCT for Cervidae (USDA, 1999). Results of the CCT were used to classify deer as negative, suspect, or reactor.

RESULTS

Due to their poor condition, deer in the high dose group were euthanized prior to scheduled intradermal tuberculin skin testing; therefore no skin test results are available for these deer. Ninety days after infection, six of eight low dose deer were classified as reactors and two of eight were classified as negative for exposure to *M. bovis* using the comparative cervical skin test.

Tuberculous lesions were more disseminated, involving a greater number of tissues in deer infected with the high inoculum dose. In the high dose group the most commonly affected tissues were the medial retropharyngeal, tracheobronchial, mediastinal, hepatic, and mesenteric lymph nodes and lung (Table 1). Mandibular and parotid lymph nodes, palatine tonsils, and liver were other common sites of involvement.

In the low dose group the most commonly affected tissues were the lung and tracheobronchial, mediastinal, and medial retropharyngeal lymph nodes. Gross or

TABLE 1. Summary of gross, microscopic, and bacteriologic findings from white-tailed deer infected by aerosol with a low (6×10^2 to 1.6×10^3 colony forming units [CFU]) or high dose (2×10^5 to 1×10^6 CFU) of *M. bovis* strain 1315. Data represent the total out of four or eight deer in the high and low dose groups, respectively, that had gross (G) or microscopic (M) lesions or from which *M. bovis* was isolated (B).

Tissue	High dose			Low dose		
	G	M	B	G	M	B
Tonsil	— ^a	1/4	2/4	1/8	—	3/8
Mandibular LN ^b	2/4	3/4	3/4	1/8	—	—
Parotid LN	1/4	1/4	3/4	2/8	1/8	2/8
Med retropharyngeal LN	4/4	4/4	4/4	1/8	1/8	3/8
Tracheobronchial LN	4/4	4/4	4/4	3/8	3/8	3/8
Mediastinal LN	4/4	4/4	4/4	5/8	4/8	3/8
Lung	4/4	4/4	4/4	4/8	3/8	3/8
Liver	1/4	2/4	3/4	1/8	1/8	1/8
Hepatic LN	2/4	3/4	3/4	2/8	2/8	1/8
Mesenteric LN	4/4	4/4	4/4	2/8	1/8	3/8

^a — = no gross or microscopic lesion or no *M. bovis* isolated from any animal within the group.

^b LN = lymph node.

microscopic lesions were most common in the lung and associated lymph nodes (tracheobronchial or mediastinal). Two of the three deer with medial retropharyngeal involvement were identified as infected through bacteriologic isolation of *M. bovis*; yet no gross or microscopic lesions were seen.

In all deer from the high dose group, lungs were grossly characterized by disseminated variably sized granulomas present on the pleural surface of all lobes and extending deep throughout the parenchyma. Lesions in the medial retropharyngeal lymph nodes consisted of mild to moderate lymphadenomegaly with multifocal to coalescent caseonecrotic granulomas effacing the cortex and less commonly the medulla of the lymph node. On cut surface granulomas were gritty and contained cen-

tral caseonecrotic material. Lesions in other lymph nodes were grossly similar to those seen in the medial retropharyngeal lymph node.

In contrast, two of eight deer in the low dose group did not have lesions in any tissue and *M. bovis* was not isolated from any tissue collected. One of eight deer had disseminated lesions similar to those seen in deer from the high dose group. The remaining five of eight deer in the low dose group had lung lesions characterized by multiple (<10) variably sized granulomas (≥ 1 cm) most commonly involving the caudal lung lobes (Table 2). Lesions were present both on the pleural surface as well as deep within the pulmonary parenchyma (Fig. 2). Medial retropharyngeal lymph node lesions were uncommon in deer from the low dose group where only one of eight deer had lesions similar to those seen in deer from the high dose group. Lesions in tracheobronchial and mediastinal lymph nodes from the low dose group consisted of moderate lymphadenomegaly with multifocal to coalescent caseonecrotic granulomas.

Microscopic lesions were similar regardless of inoculum dose and consisted of focal, multifocal, or coalescent caseonecrotic granulomas composed of central areas of

TABLE 2. Lobar distribution of lung lesions in white-tailed deer infected by aerosol with a low dose (6×10^2 to 1.6×10^3 colony forming units) of *Mycobacterium bovis* strain 1315.

Lobe	Number of animals
Left cranial	1/6
Left caudal	5/6
Right cranial	1/6
Right middle/caudal	5/6
Accessory	0/6




FIGURE 2. Lung from a white-tailed deer that received low dose (6×10^2 to 1.6×10^3 colony forming units) of *M. bovis* strain 1315 by aerosol exposure. Note multiple small coalescent granulomas near lung margin (between arrows).

necrosis with some neutrophils, surrounded by epithelioid macrophages, Langhans' type multinucleated giant cells, and lymphocytes. In some cases, the central core of necrotic debris was mineralized. Acid fast bacteria were seen in low numbers within multinucleated giant cells or extracellularly among cellular debris within the caseonecrotic core. Granulomas often were surrounded by low numbers of fibroblasts and small amounts of collagen. Within the lung many granulomas were found adjacent to or surrounding bronchi or bronchioles that contained variable amounts of intraluminal granulomatous to pyogranulomatous infiltrate (Fig. 3).

DISCUSSION

The droplet nuclei mechanism of infection with *M. tuberculosis* has shown that tiny residues, $<5 \mu\text{m}$, of evaporated droplets (droplet nuclei) can be generated by talking, coughing, or even singing. Such nuclei remain airborne for prolonged periods while larger droplets settle out within short distances of their source. Once inhaled, infectious droplet nuclei reach the pulmonary alveoli while droplets $>5 \mu\text{m}$

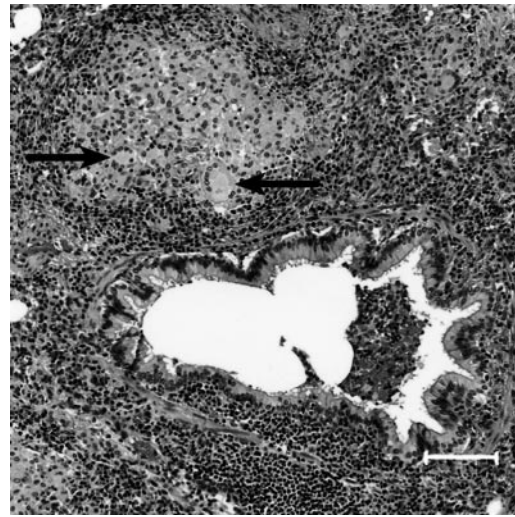


FIGURE 3. Photomicrograph of section of lung from a white-tailed deer that received low dose (6×10^2 to 1.6×10^3 colony forming units) of *M. bovis* strain 1315 by aerosol exposure. Note bronchiole with intraluminal exudate and adjacent granuloma with multinucleated giant cells (arrows). HE. Bar=100 μm .

are removed in the upper respiratory passages (Wells et al., 1948; Loudon and Roberts, 1967, 1968). The Equine Aeromask system used in the present study is designed for aerosol delivery of pharmaceutical agents to large animals but is easily adapted for the delivery of microbes. Recently, aerosol delivery of *M. bovis* to cattle was reported using a similar apparatus (Palmer et al., 2002b). Aerosol delivery of infectious agents to deer has not been reported previously. Adaptation of small laboratory animal aerosol delivery systems for use in large animals such as deer would likely prove more difficult.

The apparatus described in the present study provides a reliable method of aerosol delivery of *M. bovis* to deer. All but two of the deer in this study developed tuberculous lesions after aerosol exposure to *M. bovis*. *Mycobacterium bovis* was not isolated from these deer; moreover no tuberculin skin test reaction, indicative of exposure to *M. bovis* was seen, suggesting that the delivery method did not adequately deliver the inoculum in these cases. In

all other deer, distribution of lesions suggests the aerosol generated by the nebulizer was composed of droplets of diameter less than 5 μm which reached the pulmonary alveoli. This was especially evident in deer receiving the low dose of inoculum where lesions were focused on the lung and associated lymph nodes.

More severe disease, characterized by wider dissemination of lesions, with higher inoculum dosages has also been seen in other animal models of tuberculosis (Converse et al., 1996; Chambers et al., 2001; Palmer et al., 2002b). Unlike animal models of human tuberculosis using mice, rabbits, and guinea pigs, the model described herein uses the animal of interest as the experimental animal. Extrapolation between species that may differ in immune response, lesion development, or susceptibility to infection is therefore, not necessary.

Several surveys of hunter-killed deer have described the distribution of lesions in tuberculous white-tailed deer. In naturally infected deer, lesions have been reported most commonly in the medial retropharyngeal lymph nodes (Schmitt et al., 1997; Palmer et al., 2000; O'Brien et al., 2001). The most common extracranial sites for lesion development are reported to be the lungs, pulmonary lymph nodes, and costal pleura. Medial retropharyngeal lymph nodes were commonly involved only in deer receiving the high dose of inoculum. Deer receiving the low dose of inoculum did not commonly have lesions in the medial retropharyngeal lymph nodes. The different pattern of lesion distribution in deer infected through aerosol exposure to *M. bovis* suggests that the aerosol route of transmission may not be a primary means of exposure of white-tailed deer to *M. bovis* in natural infection. Cranial lymph nodes were the most common site of *M. bovis* isolation in white-tailed deer fawns orally inoculated with a low dose of *M. bovis* (Palmer et al., 2002a). Interestingly, deer experimentally inoculated using the intratonsillar route routinely

develop lesions in the medial retropharyngeal lymph nodes, suggesting an important role for the tonsils in natural infection (Palmer et al., 1999). The role of the tonsils in tuberculosis of other ruminant species has previously been highlighted (Lugton, 1999). A predilection for lesion development in the caudal lung lobes, similar to that seen in the present study, has previously been reported in white-tailed deer naturally or experimentally infected with *M. bovis* (Palmer et al., 1999; O'Brien et al., 2001). The reason for such a predilection is unclear, but could be due to mechanical factors such as the directness of the airways in the caudal lung lobes or momentum of inspired droplets that carries them to caudal lung lobes. A definitive reason for such a predilection has not been found. Moreover, the effect of an immobilizing agent such as xylazine in the present study, with known ventilatory depressant effects, on lesion distribution is unknown.

The method of aerosol delivery described above represents a reliable method of experimental infection of deer with *M. bovis*. This method could serve as a useful challenge model to evaluate disease pathogenesis, immune response, mycobacterial shedding, and vaccine efficacy. Likewise, it would be useful for the study of other respiratory pathogens of deer where aerosol exposure is critical.

ACKNOWLEDGEMENTS

The authors thank R. Lyon, J. Mentele, T. Rahner, S. Zimmerman, N. Heley-Lehman, and R. Cook for technical assistance and W. Varland, D. Ewing, and N. Lyon, for animal care.

Mention of trade names or commercial products is solely for the purpose of providing specific information and does not imply recommendation or endorsement by the United States Department of Agriculture.

LITERATURE CITED

- BOLIN, C. A., D. L. WHIPPLE, K. V. KHANNA, J. M. RISDAHL, P. K. PETERSON, AND T. W. MOLITOR. 1997. Infection of swine with *Mycobacterium*

- bovis* as a model of human tuberculosis. *Journal of Infectious Diseases* 176: 1559–1566.
- BUCHAN, G. S., AND J. F. T. GRIFFIN. 1990. Tuberculosis in domesticated deer (*Cervus elaphus*): A large animal model for human tuberculosis. *Journal of Comparative Pathology* 103: 11–22.
- CHAMBERS, M. A., A. WILLIAMS, D. GAVIER-WIDEN, A. WHELAN, C. HUGHES, G. HALL, M. S. LEVER, P. D. MARSH, AND R. G. HEWINSON. 2001. A guinea pig model of low-dose *Mycobacterium bovis* aerogenic infection. *Veterinary Microbiology* 80: 213–226.
- CONVERSE, P. J., A. M. DANNENBURG, J. E. ESTEP, K. SUGISAKE, Y. ABE, B. H. SCHOFIELD, AND L. M. PITT. 1996. Cavitory tuberculosis produced in rabbits by aerosolized virulent tubercle bacilli. *Infection and Immunity* 64: 4776–4787.
- DANNENBURG, A. M. 1994. Rabbit model of tuberculosis. *In Tuberculosis: Pathogenesis, protection and control*, B. R. Bloom (ed.). ASM Press, Washington, D.C., pp. 149–156.
- GRANGE, J. M., AND M. D. YATES. 1994. Zoonotic aspects of *Mycobacterium bovis* infection. *Veterinary Microbiology* 40: 137–151.
- HESS, D., D. FISHER, P. WILLIAMS, S. POOLER, AND R. M. KACMAREK. 1996. Medication nebulizer performance: Effect of diluent volume, nebulizer flow and nebulizer brand. *Chest* 110: 498–505.
- LOUDON, R. G., AND R. M. ROBERTS. 1967. Droplet expulsion from the respiratory tract. *American Review of Respiratory Diseases* 95: 435–442.
- , AND ———. 1968. Singing and the dissemination of tuberculosis. *American Review of Respiratory Diseases* 98: 297–300.
- LUGTON, I. W. 1999. Mucosa-associated lymphoid tissues as sites for uptake, carriage and excretion of tubercle bacilli and other pathogenic mycobacteria. *Immunology and Cell Biology* 77: 364–372.
- MCMURRAY, D. N. 1994. Guinea pig model of tuberculosis. *In Tuberculosis: Pathogenesis, protection and control*, B. R. Bloom (ed.). ASM Press, Washington, D.C., pp. 135–147.
- O'BRIEN, D. J., S. D. FITZGERALD, T. J. LYON, K. L. BUTLER, J. S. FIERKE, K. R. CLARKE, S. M. SCHMITT, T. M. COOLEY, AND D. E. BERRY. 2001. Tuberculous lesions in free-ranging white-tailed deer in Michigan. *Journal of Wildlife Diseases* 37: 608–613.
- ORME, I. M., AND F. M. COLLINS. 1994. Mouse model of tuberculosis. *In Tuberculosis: Pathogenesis, protection and control*, B. R. Bloom (ed.). ASM Press, Washington, D.C., pp. 113–134.
- PALMER, M. V., D. L. WHIPPLE, AND S. C. OLSEN. 1999. Development of a model of natural infection with *Mycobacterium bovis* in white-tailed deer. *Journal of Wildlife Diseases* 35: 450–457.
- , ———, J. B. PAYEUR, D. P. ALT, K. J. ESCH, C. S. BRUNING-FANN, AND J. B. KANEENE. 2000. Naturally occurring tuberculosis in white-tailed deer. *Journal of the American Veterinary Medical Association* 216: 1921–1924.
- , W. R. WATERS, AND D. L. WHIPPLE. 2002a. Milk containing *Mycobacterium bovis* as a source of infection for white-tailed deer fawns (*Odocoileus virginianus*). *Tuberculosis* 82: 161–165.
- , ———, AND ———. 2002b. Aerosol delivery of virulent *Mycobacterium bovis* to cattle. *Tuberculosis* 82: 275–282.
- SCHMITT, S. M., S. D. FITZGERALD, T. M. COOLEY, C. S. BRUNING-FANN, L. SULLIVAN, D. BERRY, T. CARLSON, R. B. MINNIS, J. B. PAYEUR, AND J. SIKARSKIE. 1997. Bovine tuberculosis in free-ranging white-tailed deer from Michigan. *Journal of Wildlife Diseases* 33: 749–758.
- UNITED STATES DEPARTMENT OF AGRICULTURE. 1999. Bovine tuberculosis eradication uniform methods and rules, Animal and Plant Health Inspection Service, Veterinary Services, U.S. Government Printing Office, Washington, D.C., 21 pp.
- WELLS, W. F., H. L. RATCLIFFE, AND C. CRUMB. 1948. On the mechanisms of droplet nuclei infection. II. Quantitative experimental air-borne tuberculosis in rabbits. *American Journal of Hygiene* 47: 11–28.

Received for publication 6 February 2003.