



## Epizootiology of Hemorrhagic Disease in Mule Deer in Central Arizona

Authors: Dubay, Shelli A., deVos, James C., Noon, Ted H., and Boe, Sue

Source: Journal of Wildlife Diseases, 40(1) : 119-124

Published By: Wildlife Disease Association

URL: <https://doi.org/10.7589/0090-3558-40.1.119>

---

BioOne Complete ([complete.BioOne.org](https://complete.BioOne.org)) is a full-text database of 200 subscribed and open-access titles in the biological, ecological, and environmental sciences published by nonprofit societies, associations, museums, institutions, and presses.

Your use of this PDF, the BioOne Complete website, and all posted and associated content indicates your acceptance of BioOne's Terms of Use, available at [www.bioone.org/terms-of-use](https://www.bioone.org/terms-of-use).

Usage of BioOne Complete content is strictly limited to personal, educational, and non - commercial use. Commercial inquiries or rights and permissions requests should be directed to the individual publisher as copyright holder.

---

BioOne sees sustainable scholarly publishing as an inherently collaborative enterprise connecting authors, nonprofit publishers, academic institutions, research libraries, and research funders in the common goal of maximizing access to critical research.

## Epizootiology of Hemorrhagic Disease in Mule Deer in Central Arizona

Shelli A. Dubay,<sup>1,3</sup> James C. deVos, Jr.,<sup>1</sup> Ted H. Noon,<sup>2</sup> and Sue Boe<sup>1</sup> <sup>1</sup>Arizona Game and Fish Department, 2221 W. Greenway Rd., Phoenix, Arizona 85023, USA; <sup>2</sup>Arizona Veterinary Diagnostic Laboratory, 2831 N. Freeway, Tucson, Arizona 85705, USA; <sup>3</sup>Corresponding author (email: sdubay@gf.state.az.us)

**ABSTRACT:** We report two male mule deer (*Odocoileus hemionus*) mortalities that occurred near Prescott, Arizona (USA) in September 2001. Necropsy lesions were compatible with those described for hemorrhagic disease (HD). Bluetongue (BTV) and epizootic hemorrhagic disease (EHDV) viral RNA were identified in tissues from one deer and EHDV viral RNA was identified in the other via reverse transcription-polymerase chain reaction (RT-PCR). Virus isolation attempts were unsuccessful in both cases. To determine geographic range and viral serotypes involved, we collected blood samples from healthy hunter-harvested male mule deer in three game management units near Prescott in October 2001. Forty-one blood samples were collected and antibodies against EHDV and/or BTV were found in 21/41 (51%) samples as determined by agar immunodiffusion. Serum neutralization test results suggest that multiple EHDV and BTV serotypes are present in Arizona.

**Key words:** Arizona, bluetongue, epizootic hemorrhagic disease, *Odocoileus hemionus*, mule deer.

Hemorrhagic disease (HD) has been documented in several free-ranging ruminants, including white-tailed deer (*Odocoileus virginianus*), mule deer (*Odocoileus hemionus*), and pronghorn (*Antilocapra americana*) (Thorne, 1982; Gibbs and Greiner, 1989). Clinical signs of HD in white-tailed deer may include rapid death or death after 5–7 days of illness in which clinical signs of weakness, dehydration, cessation of feeding, and salivation may be observed. Prominent lesions in affected animals are hemorrhage and edema of varying extent (Thorne, 1982). Hemorrhagic disease is caused by two antigenically related viral groups, epizootic hemorrhagic disease virus (EHDV) and bluetongue virus (BTV), and significant population effects have been documented after epizootics of HD in pronghorn and deer (Karstad et al., 1961; Karstad and Trainer,

1967; Roughton, 1975; Thorne et al., 1988; Nettles and Stallknecht, 1992). In the United States, two EHDV serotypes (serotypes 1 and 2) and five BTV serotypes (serotypes 2, 10, 11, 13, and 17) have been identified from infected animals (Pearson et al., 1992a). Both viral types can infect animals simultaneously (Prestwood et al., 1974; Thomas et al., 1974). Biting midges of the genus *Culicoides* are the principal vectors for EHDV and BTV (Foster et al., 1977; Tabachnick, 1996). In Arizona, few HD cases have been identified in free-ranging wildlife, but antibody presence has been documented in cattle, deer, and pronghorn (Metcalf et al., 1981; Heffelfinger et al., 1999). The first documented cases of HD in free-ranging deer in Arizona occurred in 1993 (Noon et al., 2002b). Noon et al. (2002a) also reported HD in a free-ranging bighorn sheep (*Ovis canadensis*) in Arizona in 1995. Our goal was to determine the viral serotypes active in the area of fall 2001 deer mortalities near Prescott, Arizona, USA (112°27'52"N, 34°32'37"W) and to attempt to determine the geographic areas where exposure to these pathogens occurred.

On 6 September 2001, an adult male mule deer with antlers in velvet was found in game management unit (GMU) 17B in Strickland Wash near Prescott, Arizona (112°40'36"N, 34°36'03"W, 1,440 m). Habitat consists of pinyon pine (*Pinus edulis*) and juniper (*Juniperus* spp.) woodland. The deer was near a drainage by a ranch residence and was lethargic, emaciated, ataxic, indifferent to people, and found where another dead deer had been seen approximately 1 wk earlier. An opaque discharge drained from the mouth and nose. Ranch employees captured the animal and held it

for approximately 8 hr. Arizona Game and Fish Department (AGFD) personnel administered Telazol (Fort Dodge Animal Health, Fort Dodge, Iowa, USA) in an attempt to anesthetize the animal. The deer died approximately 30 min later. The carcass was submitted to the Arizona Veterinary Diagnostic Laboratory (AZVDL) for necropsy (case #01-5851) on 7 September 2001.

At necropsy, the deer had patches of alopecia on the trunk and few skin abrasions on the hind legs. The carcass was underweight with minimal subcutaneous fat. A few small hemorrhages were present in the papillary muscles of the left ventricle of the heart and there was a hemorrhage at the base of the aorta. Locally extensive hemorrhages were located in semimembranosus/tendinosis musculature of the left hind leg.

Microscopically, multifocal, intramuscular hemorrhage was present in papillary muscles of the heart. In adrenal glands, there was severe, diffuse, hemorrhage and necrosis of cortex. In skeletal muscles from the left hind limb, there was intramuscular hemorrhage and a few sarcocysts. Kidney had a moderate to severe pyelonephritis.

Spleen tissue was submitted to the National Veterinary Services Laboratory (NVSL) in Ames, Iowa, USA, for virus isolation and reverse transcription-polymerase chain reaction (RT-PCR) testing for hemorrhagic disease viruses (Pearson et al., 1992b; Katz et al., 1993; Wilson, 1994; Eaton, 1996; Johnson et al., 2000). Reverse transcription-polymerase chain reaction testing detected both EHDV and BTV viral RNA. Virus isolation was negative.

The second mule deer was found on 28 September 2001 and was an adult buck with antlers in velvet. This deer was found dead in the Glassford Hill urban area near Prescott (GMU 19A, 112°23'32"N, 34°34'25"W, 1,830 m). The deer had been dead approximately 4–6 hr and was found within 135 m of a dirt cattle tank containing water. Vegetation consisted of juniper

(*Juniperus* spp.) cut reclaimed grassland and ornamental plants for landscaping. Cliffrose (*Cowania mexicana*) and mountain mahogany (*Cercocarpus ledifolius*) were also present in the area. Soil marks around the carcass indicated that it had thrashed its legs prior to death. Bloody, watery fluid drained from the anus and mouth. Opaque discharge was evident around the mouth and nose. The carcass was submitted to AZVDL for necropsy (case #01-6334) the same day.

At necropsy, the lungs were diffusely discolored dark red and exuded fluid when excised. Considerable froth was present in the lumen of the trachea. Dark red discoloration suggestive of hemorrhage was present in the cortices of both adrenal glands and along the margins of the mucosal folds of the abomasum.

Microscopically, there was diffuse congestion of the microvasculature and alveolar flooding with eosinophilic fluid in lung. Fibrin strands were evident in alveolar lumens. In spleen, there was diffuse congestion of red pulp and hemorrhages in some lymphoid follicles. Hemorrhage was apparent in some glomerular tufts in kidney. In adrenal gland, there was severe congestion, hemorrhage, and multifocal necrosis of cortex. In abomasum, there was severe, multifocal mucosal necrosis and hemorrhage associated with severe infiltrates of neutrophils. In sections of heart, there were subendocardial and epicardial hemorrhages. *Salmonella arizona* 50:R-Z was cultured from liver tissue. A few salmonella-like organisms were also isolated from intestine.

Lung and spleen tissue were submitted to NVSL for virus isolation and RT-PCR testing for hemorrhagic disease viruses according to methodology cited previously. Reverse transcription-polymerase chain reaction testing was reported as positive for EHDV viral RNA. Virus isolation attempts were negative.

Following these deer mortalities, we sent out 800 mailers to mule deer hunters within three GMUs in central Arizona to

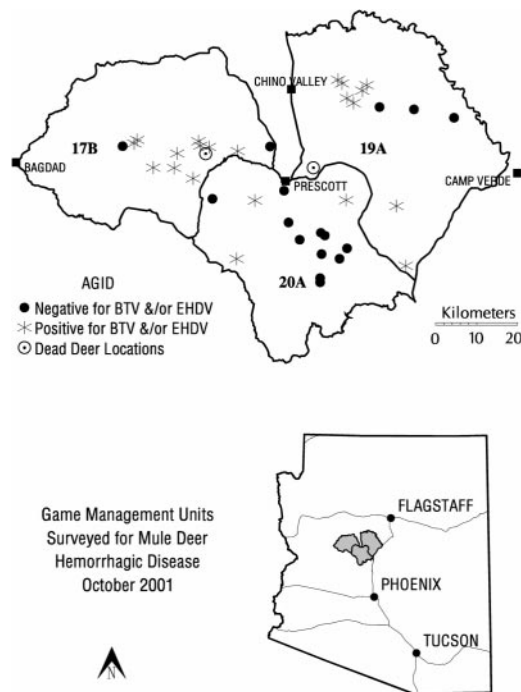


FIGURE 1. Mule deer harvest locations showing exposure to hemorrhagic disease viruses in three game management units in Arizona.

acquire blood samples from hunter-harvested animals in October 2001 (Fig. 1). Each mailer contained a 50ml Falcon centrifuge tube (VWR Scientific, Brisbane, California, USA) for blood collection, a map of the appropriate GMU, instructions on how to collect the blood sample, and a list of collection stations for blood samples. Hunters were asked to record kill location on the map provided. Once the samples were delivered to AGFD personnel, the tubes were labeled with date, GMU, and a unique identification number and centrifuged in a Dynac Model 420101 centrifuge (Becton Dickinson, Sparks, Maryland, USA) at 1,500×G for 15 min or until serum was easily separated from the clot. Sterile disposable syringes were used to draw off serum. Sera were placed in sterile 50 ml Falcon centrifuge tubes and refrigerated until sent to AZVDL. Sera were tested for antibodies against BTV and EHDV with the agar gel immunodiffusion (AGID) method (Pearson and Jochim,

1979). The AGID does not reliably differentiate between BTV and EHDV antibody due to cross-reactions (Stallknecht et al., 1991). To identify serotypes involved, AGID-positive sera were referred to NVSL for serum neutralization (SN) testing (Eaton, 1996). Due to cross-reactivity on SN tests, a SN dilution of 1:20 or higher was considered evidence of exposure to a specific serotype (Stallknecht et al., 1996). Titers of 1:80 or higher for 50% of the AGID-positive sera were considered evidence of viral activity in the Prescott area. Harvest locations of most deer were mapped by GMU, and geographic trends in exposure were compared with known mapped locations of roads, elevation, water availability, and habitat type. A *t*-test (Zar, 1999) was calculated on the means of potential habitat characteristics in order to determine if kill sites where seropositive animals were harvested differed from sites where seronegative animals were harvested.

A total of 41 serum samples from male mule deer was collected from three GMUs near Prescott in October 2001 (Table 1); 21 (51%) were positive for BTV and/or EHDV antibody via AGID. From GMU 17B, 10/12 (83%) samples were positive, 8/12 (67%) samples from 19A were positive, and 3/17 (18%) samples from 20A were positive. All 21 AGID-positive samples were positive for SN antibody at  $\geq 1:20$  serum dilution for at least one viral serotype. A titer of 1:20 or higher for EHDV type 2 was found in 16/21 (76%) of the samples, and antibody titers of 1:20 or higher for EHDV type 1 were detected in 4/21 (19%) of the samples. Bluetongue virus type 13 antibody at 1:20 or higher was detected in 19/21 (90%), BTV type 11 antibody was found in 17/21 (81%), BTV type 10 antibody was found in 15/21 (71%), BTV type 2 antibody was detected in 12/21 (57%) of the samples, and BTV type 17 antibody was found in 1 of 21 (5%). Antibody titers of 1:80 or higher were found for each serotype (Table 1), but >50% of the AGID-positive samples

TABLE 1. Number of positive serum samples (percentage) for hemorrhagic disease viruses by titer for mule deer in three game management units (GMUs) in Arizona.

Serotype	GMU 17B (n = 10)				GMU 19A (n = 8)				GMU 20A (n = 3)			
	0	1:20	1:40	1:80+	0	1:20	1:40	1:80+	0	1:20	1:40	1:80+
EHDV 1	9 (90)	1 (10)	0 (0)	0 (0)	7 (88)	1 (13)	0 (0)	0 (0)	1 (33)	1 (33)	0 (0)	1 (33)
EHDV 2	4 (40)	1 (10)	2 (20)	2 (20)	1 (13)	0 (0)	1 (13)	6 (75)	0 (0)	0 (0)	1 (33)	2 (67)
BTV 2	6 (60)	2 (20)	2 (20)	0 (0)	2 (26)	3 (39)	1 (13)	2 (26)	1 (33)	1 (33)	0 (0)	1 (33)
BTV 10	5 (50)	3 (30)	0 (0)	2 (20)	1 (13)	2 (26)	1 (13)	4 (52)	0 (0)	0 (0)	0 (0)	3 (100)
BTV 11	3 (30)	1 (10)	3 (30)	3 (30)	1 (13)	1 (13)	0 (0)	6 (75)	0 (0)	1 (33)	0 (0)	2 (67)
BTV 13	1 (10)	1 (10)	1 (10)	7 (70)	1 (13)	1 (13)	2 (26)	4 (52)	0 (0)	0 (0)	2 (67)	1 (33)
BTV 17	0 (0)	0 (0)	0 (0)	0 (0)	8 (100)	0 (0)	0 (0)	0 (0)	2 (67)	0 (0)	0 (0)	1 (33)

had titers of 1:80 or higher for only EHDV 2, BTV 10, BTV 11, and BTV 13 in all GMUs combined. Perhaps cross-reactivity is responsible for some of the lower titers in EHD 1, BTV 2, and BTV 17 from sera obtained in the Prescott area.

Harvest locations were plotted for 37 kill locations because location data were not obtained for four animals. When the locations and AGID results from all animals were plotted on a map, interesting patterns emerged (Fig. 1); GMU 20A, which is located between GMUs 19A and 17B, had only 3/17 (18%) positive samples. Several EHDV- and BTV-negative animals were harvested from the center of the unit (Fig. 1), suggesting that two foci of disease could have been present, but low sample sizes prevent a definitive evaluation of this hypothesis. The Bradshaw Mountain Range runs north-south through the central part of GMU 20A, and therefore we calculated mean elevation for kill site locations of deer that were AGID-positive and compared that with the mean elevation of negative animals in all GMUs. A *t*-test showed that seronegative animals were harvested from significantly higher elevations (mean = 1,759 m ± 88 m SE) than seropositive deer (mean = 1,542 m ± 38 m SE; *P* = 0.01). All other habitat characteristics were not significant. Similar elevation and habitat trends have been observed in Georgia and Texas (USA) (Stallknecht et al., 1995, 1996). In this study, increasing elevation seemed to be associated with decreased amounts of water thought

to be suitable for the breeding of *Culicoides* sp. Given the low sample sizes in this study, additional investigations of the correlation between elevation and HD exposure are warranted.

Many deer had high SN antibody titers against EHDV serotype 2 and BTV serotypes 10, 11, and 13. It is possible these serotypes of hemorrhagic disease viruses are enzootically stable in Arizona. Specifically, a relationship may exist where vectors, viruses, and appropriate hosts are nearly always present in the environment with frequent exposure to infection resulting with a generally high level of immunity within the cervid population and a low incidence of clinically apparent disease (Stallknecht et al., 1996). In Arizona, antibodies against both EHDV and BTV viral groups are frequently detected in healthy animals but only a few clinically ill animals have been found (Heffelfinger et al., 1999; Noon et al., 2002a, b).

Several hypotheses have been proposed for the low incidence of HD despite a high antibody prevalence in Texas (Stallknecht et al., 1996), that might also apply to Arizona (Noon et al., 2002a, b). First, lack of detection and routine examination of ill animals may have played a role in the apparent low incidence of HD cases in the past in Arizona. Second, Arizona deer could be resistant to HD viruses; Gaydos (2001) found that white-tailed deer fawns from Pennsylvania (USA) were highly susceptible to EHDV viruses, while deer from Texas showed mild clinical signs after

exposure. Experimentally infected deer from Pennsylvania, where HD is not enzootic, had 100% mortality when inoculated with EHDV serotype 1. Fawns from Texas, where HD may be enzootically stable, showed only mild clinical symptoms when inoculated with the same virus. Gaydos (2001) concluded that innate resistance could play a role in the epizootiology of clinical HD in white-tailed deer in North America.

High rates of exposure may result in most does transferring temporary passive antibody to their exposed offspring, reducing the likelihood of widespread severe disease among juvenile or young adult deer. Gaydos et al. (2002) investigated maternal antibody presence in white-tailed deer fawns in Texas by comparing results from fawns that were housed indoors from 2 wk after birth with fawns that remained outside for the duration of the study. They found that maternal antibodies against HD viruses were present in fawns until approximately 17 wk of age. In addition, fawns housed outside were naturally exposed to HD viruses before 18 wk of age; viruses were isolated from 10% of these individuals but clinical disease was not observed. It was believed that maternal antibodies conferred partial immunity to young animals in Texas where HD viruses may be enzootically stable.

The presence of BTV and EHDV in deer habitat has implications for the translocation of susceptible wild ungulates from nonenzootic sites. Knowing exposure history of the recipient and source populations is crucial to increase the chances of a successful translocation event. Translocating naive animals into an area where HD viruses are enzootically stable could pose risks to the naive individuals.

More information on the epizootiology of HD viruses in Arizona is needed. Specifically, additional studies of innate resistance in Arizona mule deer populations are warranted. Data concerning vector competence and seasonality, geographic distribution of exposure, and climate ef-

fects such as drought in the arid southwestern United States are also needed. The role that drought conditions and subsequent nutritional stressors play in HD case numbers is also of concern, especially in Arizona where precipitation levels vary greatly from year to year. Drought may force stressed animals to congregate around few remaining water sources, where HD exposure may be intense.

The authors thank E. Gardner, S. Poppenberger, and D. Buckley for delivering carcasses for necropsy and O. Halferty for assistance with necropsies. D. Stallknecht made comments on an earlier draft of this manuscript. Funding was provided by State Trust Grant W-78-R.

#### LITERATURE CITED

- EATON, B. 1996. Bluetongue. *In* Office International des Epizooties, Manual of standards for diagnostic tests and vaccines, 3rd Edition, OIE Standards commission (eds.). OIE Press, Paris, France, pp. 109–118.
- FOSTER, N. M., R. D. BRECKON, A. J. LUEDKE, R. H. JONES, AND H. E. METCALF. 1977. Transmission of two strains of epizootic hemorrhagic disease virus in deer by *Culicoides variipennis*. *Journal of Wildlife Diseases* 13: 9–16.
- GAYDOS, J. K. 2001. Evaluation of white-tailed deer host resistance factors to epizootic hemorrhagic disease viruses. PhD Dissertation, University of Georgia, Athens, Georgia, 147 pp.
- , D. E. STALLKNECHT, D. KAVANAUGH, R. J. OLSON, AND E. R. FUCHS. 2002. Dynamics of maternal antibodies to hemorrhagic disease viruses (*Reoviridae: Orbivirus*) in white-tailed deer. *Journal of Wildlife Diseases* 38: 253–257.
- GIBBS, E. P. J., AND E. C. GREINER. 1989. Bluetongue and epizootic hemorrhagic disease. *In* The arboviruses: Epidemiology and ecology, Vol. 2. T. P. Monath (ed.). CRC Press, Inc., Boca Raton, Florida, pp. 30–70.
- HELLFINGER, J. R., R. J. OLDING, T. H. NOON, M. R. SHUPE, AND D. P. BETZER. 1999. Copper/selenium levels and occurrence of bluetongue virus in Arizona pronghorn. *Proceedings of the Pronghorn Antelope Workshop* 18: 32–42.
- JOHNSON, D. J., W. C. WILSON, AND P. S. PAUL. 2000. Validation of a reverse transcriptase multiplex PCR test for the serotype determination of U.S. isolates of bluetongue virus. *Veterinary Microbiology* 76: 105–115.
- KARSTAD, L., AND D. O. TRAINER. 1967. Histopathology of experimental bluetongue disease of

- white-tailed deer. *The Canadian Veterinary Journal* 8: 247–254.
- , A. WINTER, AND D. O. TRAINER. 1961. Pathology of epizootic hemorrhagic disease of deer. *Journal of Veterinary Research* 22: 227–234.
- KATZ, J. B., G. A. GUSTAFSON, A. D. ALSTAD, K. A. ADLER, AND K. M. MOSER. 1993. Colorimetric diagnosis of prolonged bluetongue viremia in sheep, using an enzyme-linked oligonucleotide sorbent assay of amplified viral nucleic acids. *American Journal of Veterinary Research* 54: 2021–2026.
- METCALF, H. E., J. E. PEARSON, AND A. L. KLINGSPORN. 1981. Bluetongue in cattle: A serologic survey of slaughter cattle in the United States. *American Journal of Veterinary Research* 42: 1057–1061.
- NETTLES, V. F., AND D. E. STALLKNECHT. 1992. History and progress in the study of hemorrhagic disease of deer. *Transactions of the North American Wildlife and Natural Resources Conference* 57: 499–516.
- NOON, T. H., S. L. WESCHE, D. CAGLE, D. G. MEAD, E. J. BICKNELL, G. A. BRADLEY, S. RIPLOG-PETERSON, D. EDSALL, AND C. REGGIARDO. 2002a. Hemorrhagic disease in bighorn sheep in Arizona. *Journal of Wildlife Diseases* 38: 172–176.
- , ———, J. HEFFELFINGER, A. FULLER, G. A. BRADLEY, AND C. REGGIARDO. 2002b. Hemorrhagic disease in deer in Arizona. *Journal of Wildlife Diseases* 38: 177–181.
- PEARSON, J. E., AND M. M. JOCHIM. 1979. Protocol for the immunodiffusion test for bluetongue. *Proceedings of the American Association of Veterinary Diagnosticians* 22: 463–475.
- , G. A. GUSTAFSON, A. L. SHAFER, AND A. D. ALSTAD. 1992a. Distribution of bluetongue in the United States. *In* Bluetongue, African horse sickness, and related orbiviruses. *Proceedings of the second international symposium*, T. E. Walton and B. I. E. Osburn (eds.). CRC Press, Inc., Boca Raton, Florida, pp. 128–139.
- , ———, ———, AND ———. 1992b. Diagnosis of bluetongue and epizootic hemorrhagic disease. *In* Bluetongue, African horse sickness, and related orbiviruses. *Proceedings of the second international symposium*, T. E. Walton and B. I. E. Osburn (eds.). CRC Press, Inc., Boca Raton, Florida, pp. 533–546.
- PRESTWOOD, A. K., T. P. KISTNER, F. E. KELLOGG, AND F. A. HAYES. 1974. The 1971 outbreak of hemorrhagic disease among white-tailed deer of the southeastern United States. *Journal of Wildlife Diseases* 10: 217–224.
- ROUGHTON, R. D. 1975. An outbreak of hemorrhagic disease in white-tailed deer in Kentucky. *Journal of Wildlife Diseases* 11: 177–186.
- STALLKNECHT, D. E., J. L. BLUE, E. A. ROLLER, III, V. F. NETTLES, W. R. DAVIDSON, AND J. E. PEARSON. 1991. Precipitating antibodies of the epizootic hemorrhagic disease and bluetongue viruses in white-tailed deer in the southeastern United States. *Journal of Wildlife Diseases* 27: 238–247.
- , V. F. NETTLES, E. A. ROLLER, III, AND E. W. HOWERTH. 1995. Epizootic hemorrhagic disease virus and bluetongue virus serotype distribution in white-tailed deer in Georgia. *Journal of Wildlife Diseases* 31: 331–338.
- , M. P. LUTTRESSL, K. E. SMITH, AND V. F. NETTLES. 1996. Hemorrhagic disease in white-tailed deer in Texas: A case for enzootic stability. *Journal of Wildlife Diseases* 32: 695–700.
- TABACHNICK, W. J. 1996. *Culicoides variipennis* and bluetongue-virus epidemiology in the United States. *Annual Review of Entomology* 41: 23–43.
- THOMAS, F. C., N. WILLIS, AND G. RUCKERBAUER. 1974. Identification of viruses involved in the 1971 outbreak of hemorrhagic disease in southeastern United States white-tailed deer. *Journal of Wildlife Diseases* 10: 187–189.
- THORNE, E. T. 1982. Bluetongue and epizootic hemorrhagic disease. *In* Diseases of wildlife in Wyoming, E. T. Thorne, N. Kingston, W. R. Jolley and R. C. Bergstrom (eds.). Wyoming Game and Fish Department, Cheyenne, Wyoming, pp. 5–10.
- , E. S. WILLIAMS, T. R. SPRAKER, W. HELMS, AND T. SEGERSTROM. 1988. Bluetongue in free-ranging pronghorn antelope (*Antilocapra americana*) in Wyoming: 1976–1984. *Journal of Wildlife Diseases* 24: 113–119.
- WILSON, W. C. 1994. Development of a nested-PCR test based on sequence analysis of epizootic hemorrhagic disease viruses non-structural protein 1 (NS1). *Virus Research* 31: 357–365.
- ZAR, J. H. 1999. *Biostatistical analysis*, 4th Edition, Prentice-Hall, Inc., Upper Saddle River, New Jersey, 663 pp.

Received for publication 7 May 2003.