



DEVELOPMENT AND PATHOGENESIS OF PARELAPHOSTRONGYLUS ODOCOILEI (NEMATODA: PROTOSTRONGYLIDAE) IN EXPERIMENTALLY INFECTED THINHORN SHEEP (OVIS DALLI)

Authors: Jenkins, E. J., Hoberg, E. P., and Polley, L.

Source: Journal of Wildlife Diseases, 41(4) : 669-682

Published By: Wildlife Disease Association

URL: <https://doi.org/10.7589/0090-3558-41.4.669>

BioOne Complete (complete.BioOne.org) is a full-text database of 200 subscribed and open-access titles in the biological, ecological, and environmental sciences published by nonprofit societies, associations, museums, institutions, and presses.

Your use of this PDF, the BioOne Complete website, and all posted and associated content indicates your acceptance of BioOne's Terms of Use, available at www.bioone.org/terms-of-use.

Usage of BioOne Complete content is strictly limited to personal, educational, and non - commercial use. Commercial inquiries or rights and permissions requests should be directed to the individual publisher as copyright holder.

BioOne sees sustainable scholarly publishing as an inherently collaborative enterprise connecting authors, nonprofit publishers, academic institutions, research libraries, and research funders in the common goal of maximizing access to critical research.

DEVELOPMENT AND PATHOGENESIS OF *PARELAPHOSTRONGYLUS ODOCOILEI* (NEMATODA: PROTOSTRONGYLIDAE) IN EXPERIMENTALLY INFECTED THINHORN SHEEP (*OVIS DALLI*)

E. J. Jenkins,^{1,3} E. P. Hoberg,² and L. Polley¹

¹ Department of Veterinary Microbiology, Western College of Veterinary Medicine, 52 Campus Dr., University of Saskatchewan, Saskatoon, Saskatchewan, S7N 5B4, Canada

² United States Department of Agriculture, Agricultural Research Service, US National Parasite Collection, Animal Parasitic Disease Laboratory, BARC East No. 1180, 10300 Baltimore Avenue, Beltsville, Maryland 20705, USA

³ Corresponding author (email: emily.jenkins@usask.ca)

ABSTRACT: Recently, the protostrongylid nematode *Parelaphostrongylus odocoilei* has been reported in a new host species, thinhorn sheep (*Ovis dalli*). For the first time, we completed the life cycle of *P. odocoilei* in three Stone's sheep (*O. dalli stonei*) and two thinhorn hybrids (*O. dalli stonei* × *O. dalli dalli*), each infected with 200 third-stage larvae from slugs (*Deroceras laeve*). The prepatent period ranged from 68 days to 74 days, and shedding of first-stage larvae (L1) peaked at >10,000 L1 per gram of feces between 90 and 110 days postinfection. A total of 75, 27, and 14 adult *P. odocoilei* were recovered from skeletal muscles of three Stone's sheep. Starting in the prepatent period, all infected sheep lost weight and developed peripheral eosinophilia. At 2 wk before patency, two thinhorn hybrids developed neurologic signs (hind end ataxia, loss of conscious proprioception, and hyperesthesia) that resolved at patency. Eosinophilic pleocytosis and antibody to *Parelaphostrongylus* spp. were detected in the cerebrospinal fluid of the affected sheep, suggesting that the migration route of the "muscleworm" *P. odocoilei* may involve the central nervous system. Twenty days after treatment with ivermectin, neurologic signs recurred and larval shedding ceased in one infected thinhorn hybrid, whereas multiple treatments transiently suppressed but did not eliminate larval shedding in the other. During patency, two Stone's sheep with numerous eggs and larvae of *P. odocoilei* in the lungs died of respiratory failure following anesthesia or exertion. *Parelaphostrongylus odocoilei* has widespread geographic distribution, high prevalence, the possibility of causing neurologic and respiratory disease, resistance to treatment, and may constitute a significant emerging disease risk for thinhorn sheep.

Key words: Life cycle, neurologic, *Ovis dalli*, *Parelaphostrongylus odocoilei*, pathogenesis, protostrongylid, thinhorn sheep, treatment.

INTRODUCTION

In 1998, the protostrongylid nematode *Parelaphostrongylus odocoilei* was discovered in a new host, Dall's sheep (*Ovis dalli dalli*), in the Mackenzie Mountains, Northwest Territories, Canada (Kutz et al., 2001). Subsequent investigations revealed that *P. odocoilei* was established in many populations of thinhorn sheep (*O. dalli*), including both Dall's sheep (*O. dalli dalli*) and Stone's sheep (*O. dalli stonei*), in northwestern North America (Jenkins et al., 2005). Thinhorn sheep were traditionally hunted by northern First Nations and currently generate significant revenue for northern communities through their value as a trophy game species (Crapo, 2000; Nadasdy, 2003).

Parelaphostrongylus odocoilei is a member of the Elaphostrongylinae (Family Protostrongylidae), which is comprised of two genera, *Parelaphostrongylus* (of North American origin) and *Elaphostrongylus* (of Eurasian origin) (Lankester, 2001). All protostrongylids undergo a similar life cycle, where first-stage larvae (L1) are shed in the feces of the mammalian definitive host, invade a gastropod intermediate host, and develop to third-stage larvae (L3) infective for another definitive host. The route of migration and target organ within the definitive host, usually a cervid, varies among the elaphostrongylines. Adults of *P. odocoilei* and *Parelaphostrongylus andersoni* are considered to be strictly muscle-dwelling, with a pattern of migration through the central nervous system (CNS)

TABLE 1. Thinhorn sheep experimentally infected with 200 infective larvae of *Parelaphostrongylus odocoilei*.

ID	Species	Age (yr)	Sex	Date of infection or placebo	PPP ^a	Peak LPG ^b	Dpi ^c peak	Dpi at end ^e
SS1	<i>Ovis dalli stonei</i>	2	M	08/02/00	72	14,071	106	173
SS2	<i>O. dalli stonei</i>	16	F	03/14/02	68	NA ^d	NA	87
SS3	<i>O. dalli stonei</i>	15	F	03/07/02	73	NA	NA	92
TS4	<i>O. dalli</i> hybrid	2	F	12/04/03	73	23,750	95	180
TS5	<i>O. dalli</i> hybrid	2	F	12/04/03	74	31,697	109	180
TS6 ^f	<i>O. dalli</i> hybrid	2	F	12/01/03	—	—	—	183
TS7 ^f	<i>O. dalli</i> hybrid	2	F	12/01/03	—	—	—	183

^a Prepatent period.

^b Larvae per gram of dry feces.

^c Days postinfection.

^d Not available as animals died shortly after patency.

^e Death (SS1 and SS3), euthanasia (SS2), or first treatment with ivermectin (TS4-TS7).

^f Control sheep, received placebo instead of infective larvae.

having either been secondarily lost or never acquired (Platt, 1984; Anderson, 2000). Adults of *Parelaphostrongylus tenuis*, the meningeal worm, establish in the CNS and cranial venous sinuses and do not invade the muscles. Adults of *Elaphostrongylus* spp. (*E. rangiferi*, *E. cervi*, and *E. alces*) travel through some aspect of the CNS before establishing in the skeletal musculature (Anderson, 2000; Lankester, 2001).

Elaphostrongylines with a neural migration can cause neurologic disease in “typical” or “atypical” definitive hosts, and eggs and larvae of all elaphostrongyline species travel via the venous circulation to the lungs, causing granulomatous interstitial pneumonia (Lankester, 2001). All elaphostrongylines have the potential to cause disease in individual hosts and can have effects at the population level (Anderson, 1972; Ball et al., 2001; Lankester, 2001). Based on clinical respiratory disease and lung pathology in both naturally and experimentally infected hosts (Brunetti, 1969; Platt and Samuel, 1978b; Pybus and Samuel, 1984a; Pybus et al., 1984; Kutz et al., 2001), *P. odocoilei* could be a significant pathogen in thinhorn sheep.

Using various gastropod intermediate hosts, the life cycle of *P. odocoilei* of cervid origin has been completed in mule deer (*Odocoileus hemionus hemionus*) (Platt and Samuel, 1978b; Pybus and Samuel, 1984b), black-tailed deer (*O. hemionus*

columbianus) (Hobmaier and Hobmaier, 1934; Brunetti, 1969; Platt and Samuel, 1978b), and moose (*Alces alces*) (Platt and Samuel, 1978b). Attempts to infect white-tailed deer (*Odocoileus virginianus*) were only marginally successful, whereas domestic goats (*Capra hircus*) and domestic sheep (*Ovis aries*) seem to be refractory to infection (Platt and Samuel, 1978b; Pybus, 1983; Pybus and Samuel, 1984b; Kutz, unpubl. data). For the first time, we complete the life cycle and describe the pathogenesis of *P. odocoilei* in experimentally infected thinhorn sheep. This work has implications for understanding life history patterns among the Elaphostrongylinae and the significance of a newly discovered host-parasite relationship, *P. odocoilei* in thinhorn sheep.

MATERIALS AND METHODS

Sources of experimental animals and *P. odocoilei*

Three captive Stone's sheep (SS1, SS2, and SS3; Table 1) were acquired from a zoo in June 2000 and housed individually (SS1) or together (SS2 and SS3) in concrete pens measuring 2.3×4 m at the Western College of Veterinary Medicine (WCVM), Saskatoon, Saskatchewan, Canada (52°07'N; 106°38'W). Four hand-raised thinhorn hybrids (*O. dalli stonei* × *O. dalli dalli*, TS4–TS7; Table 1), originally from a game ranch in Saskatchewan, were brought in from pasture in October 2003 and housed in pairs (TS4 with TS5, and TS6 with TS7) in concrete rooms measuring 3.4×4.5 m at WCVM. Animals had unlimited access to water, mineral

blocks, and grass or alfalfa hay and were offered ruminant pellets daily (Landmark Feeds, Winnipeg, Manitoba) and browse as available. SS1, SS2, and SS3 were housed in natural lighting conditions, whereas TS4–TS7 had regulated photoperiods (12 hr light:12 hr dark). Housing and procedures were approved by the University of Saskatchewan Committee on Animal Care (protocol 2000–0040).

On arrival, eggs and oocysts of several species of gastrointestinal parasites were present in feces from all three Stone's sheep, and low numbers of *Protostrongylus* sp. larvae were present in pooled feces from SS2 and SS3. Sheep received benzimidazole anthelmintic and anticoccidial treatment at least 28 days before infection with *P. odocoilei*. At 17 mo before infection, the thinhorn hybrids had been exposed to the muskox lungworm *Umingmakstrongylus pallikuukensis* (Kutz et al., 2004), but showed no evidence of infection with this or any other parasite and were not treated. As part of a separate study, one control sheep (TS7) was experimentally infected with the gastrointestinal nematode *Marshallagia marshalli* at 252 days into the *P. odocoilei* study.

For infection of SS1, first-stage larvae (L1) were obtained from four fecal samples collected in May 2000 from a Dall's sheep population known to be infected with *P. odocoilei* and no other elaphostrongylines, in the Mackenzie Mountains, Northwest Territories (65°01'N; 127°35'W) (Kutz et al., 2001). For the other sheep, L1 were obtained from feces of SS1. Slugs (*Deroceras laeve*) were infected with L1 and, after 18–35 days at room temperature, infective third-stage larvae (L3) were harvested (Hoberg et al., 1995). Motile or tightly coiled L3 were hand-picked under a dissecting microscope and held in tap water at 4 C overnight. Sheep were fasted for 24 hr, anesthetized (protocol modified from Kutz et al., 2004), and infected with 200 L3 in 60 ml of tap water administered by dose syringe and gastric tube (9.5 mm outer diameter), which were immediately flushed with a minimum of 60 ml of water, then twice with 60 ml of air. Control animals (TS6 and TS7) received the same treatment, except no L3 were administered.

Parasitologic monitoring

For SS1 in the prepatent period (PPP), we used a funnel Baermann technique to examine twelve 20-g samples from feces collected over 24 hr every 4 days until 38 days postinfection (dpi), then every 2 days (Kutz et al., 1999). Otherwise, protostrongylid larvae were recovered from feces using modified beaker Baermann sedimentation and counted using an ali-

quot or total count method (Forrester and Lankester, 1997; Jenkins et al., 2005). Larvae per gram (LPG) of wet feces was calculated, and one to three 5-g samples from each fecal collection were air dried for at least 2 wk, and LPG of the dry feces was calculated. From each pair of infected sheep housed together in the PPP, we examined six to twelve 5-g samples from pooled feces collected over 24 hr every 2 days starting at 30–40 dpi. Once patency was established, SS2 and SS3 were separated for 24 hr, and TS4 and TS5 for 4–6 hr, every Monday and Thursday. Three 5-g samples were examined from feces collected from each sheep over the period of separation or over 24 hr every Monday and Thursday for SS1. From TS6 and TS7, we examined six 5-g samples from pooled feces collected over 24 hr once a week from 43 to 380 dpi.

TS4 and TS5 were treated with 200 µg/kg subcutaneous ivermectin (10 mg/ml, Ivomec®, Merial, Baie d'Urfe, Quebec, Canada) at 180, 278, and 292 dpi. One uninfected control sheep (TS6) was treated with ivermectin at the same dose and time as infected sheep. Following treatment, we examined six 5-g samples from feces pooled from TS4 and TS5 collected over 24 hr every Monday and Thursday until 361 dpi. If larvae were detected, samples were collected from individual animals to identify the source.

The ITS-2 regions of rDNA of L1 shed in feces from SS1, TS4, and TS5 were sequenced (Jenkins et al., 2005). Total worm counts were obtained for SS1, SS2, and SS3 (Kutz et al., 2001). Five or six adult male nematodes from each Stone's sheep were fixed in 70% ethanol and 5% glycerol, cleared with lactophenol, and identified using standard morphometric techniques, including measurements of spicules and gubernacula.

Clinical monitoring

Sheep were observed daily by staff of the Animal Care Unit and at least twice a week by researchers. Animals with clinical signs were examined by researchers several times a day and at least once per episode by large animal clinicians from the WCV. Clinical pathology, including complete blood counts (CBC) and serum chemistry, was performed by Prairie Diagnostic Services, WCV, Saskatoon, Saskatchewan, Canada. The three Stone's sheep (SS1–SS3) were anesthetized every 1–4 wk for monitoring changes in the lungs associated with *P. odocoilei* (reported elsewhere); body weight and blood were also obtained at these times. Starting at 2 wk before infection, TS4–TS7 were weighed every week. Starting at 6 wk be-

fore infection, blood for CBC was obtained every 1–2 mo from TS4–TS7 under manual restraint, with increased frequency during times of clinical illness (weekly) or following treatment (every 2 wk for 6 wk). Blood from TS4–TS7 for serum chemistry was obtained every 2–3 mo. TS4–TS7 were anesthetized for cerebrospinal fluid (CSF) taps at 61–64 dpi, for medical imaging at 140 dpi, and, for TS4 only, for magnetic resonance imaging of the spinal column at 223 dpi (anesthetic protocols modified from Kutz et al., 2004). After each procedure, TS4–TS7 were treated prophylactically with subcutaneous injections of 10 mg/kg tilmycosin (300 mg/ml, Micotil®, Provel, division of Eli-Lilly, Guelph, Ontario, Canada). Examination of CSF included differential white blood cell counts, total numbers of nucleated and red blood cells, and total protein. Serum and CSF from TS4–TS7 were analyzed using protein electrophoresis and an assay for specific antibody to excretory-secretory products of *Paraphostromylylus* spp. (Ogunremi et al., 1999).

RESULTS

Parasitologic observations

Before infection with *P. odocoilei*, dorsal-spined larvae were not recovered from the feces of any sheep or from the feces of uninfected control sheep at any time in the study. Dorsal-spined larvae were first detected in feces from infected sheep from 68 to 74 dpi (Table 1). For SS1, larval shedding increased gradually in the first few weeks, reached a peak at 106 dpi, and then stabilized at a mean value of 6,117 LPG (wet weight) for a 2-mo plateau period (Table 1, Fig. 1). During this period, based on average daily production of 320 g of feces (wet weight), SS1 shed approximately two million larvae per day (120 million larvae in total). For TS4 and TS5, larval shedding increased exponentially in the first few weeks, reaching a peak between 95 and 110 dpi, then gradually decreased (Fig. 1).

Following the first treatment with ivermectin, larval counts in TS4 and TS5 were maintained at 1,700–4,800 LPG of dry feces for a week and then fell to 0 at 20 days after treatment. In TS5, but not TS4, intermittent, low-level (<10 LPG) shedding resumed at 30 days after the first treatment and continued until 20 days after a

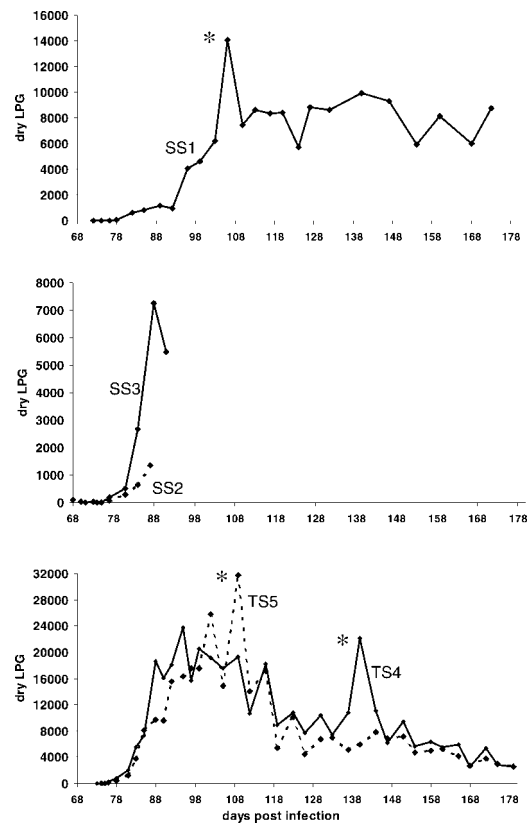


FIGURE 1. Patterns of larval shedding (in larvae per gram of dry feces) for thinhorn sheep experimentally infected with *P. odocoilei*—note different scales on y-axes. *Transient peaks following anesthesia and a monitoring procedure at 106 dpi (SS1), transfer to an unfamiliar room for fecal collection at 109 dpi (TS5), and fasting for a procedure at 140 dpi, which visibly caused stress (TS4).

second treatment. Larvae shedding from TS5 resumed 69 days after the third and final treatment.

Sequences from L1 from SS1, TS4, and TS5 were identical to each other and to that of *P. odocoilei* (GenBank accession numbers AY648380, 648392, and 648393). Seventy-five adult nematodes were recovered from skeletal muscles of SS1 (38% recovery of infective dose of 200 L3), 27 from SS2 (13.5%), and 14 from SS3 (7%). Measurements of 17 adult male nematodes from SS1, SS2, and SS3 were within the range reported for *P. odocoilei* (Platt and Samuel, 1978a; Kutz et al., 2001). At least three voucher specimens from each

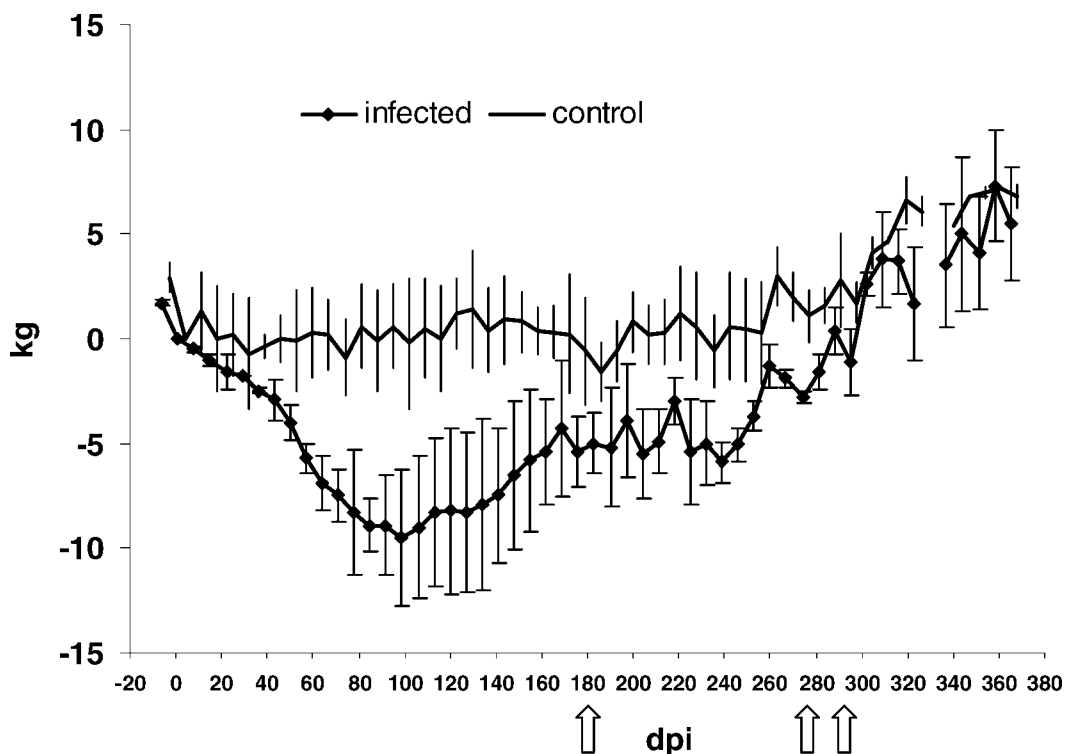


FIGURE 2. Weekly mean changes in weight relative to weight at time of infection of infected (TS4 and TS5) and control thinhorn sheep (TS6 and TS7). Dpi = days postinfection, arrows indicate treatment with ivermectin, and error bars are ± 1 SD.

Stone's sheep were deposited at the United States National Parasite Collection, Beltsville, Maryland, USA (accession numbers 94891–94894, 95314, and 95315).

Clinical observations

Weight loss in SS1, SS2, and SS3 began at approximately 28 dpi and continued until death, at which point sheep had lost, respectively, 16%, 7%, and 13% of body weight at time of infection. Weight loss was observed initially in all thinhorn hybrids on confinement, but weights of control sheep (TS6 and TS7) stabilized at about 30 dpi, whereas infected sheep (TS4 and TS5) continued to lose weight until 85–99 dpi (Fig. 2), losing a maximum of 23% and 16% of body weight at the time of infection. The infected thinhorn hybrids reached their lowest weights shortly after patency and subsequently gained weight, corresponding with decreasing larval

counts (Fig. 3). All thinhorn hybrids began to gain weight after 260 dpi (Fig. 2).

At 60–70 dpi, relative to their own baselines, SS1 and SS3 developed mild eosinophilia ($<1.2 \times 10^9/l$), which continued to increase until death. At 60 dpi, relative to control sheep, TS4 and TS5 developed mild eosinophilia, which became a sustained leukocytosis due to an absolute eosinophilia ($>1.2 \times 10^9/l$) (Fig. 4). Increasing eosinophil counts correlated with spontaneous declines in larval shedding in TS4 and TS5 before treatment with ivermectin (Fig. 5). Fifteen days after the first treatment, counts peaked at 7.5 and 6.2×10^9 eosinophils/l (54% and 48% of total white blood cells), respectively, and then fell but rose again in TS5, which continued to shed larvae after the first treatment. After the second and third treatments, eosinophil counts in both TS4 and TS5 returned to baseline values (Fig. 4). Mildly elevated

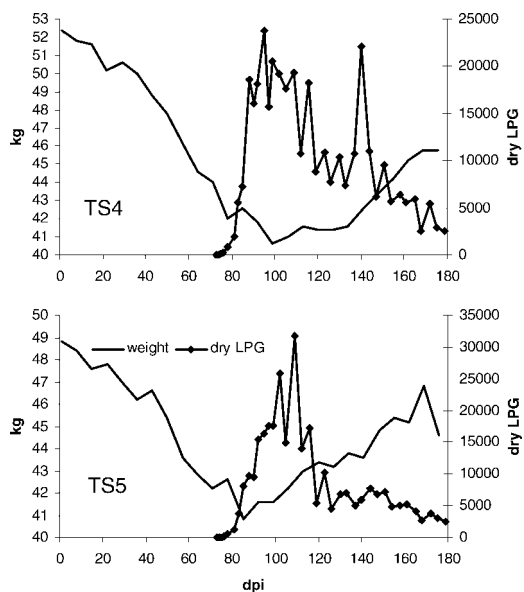


FIGURE 3. Weight (kg) and larvae per gram of dry feces (dry LPG) for infected thinhorn sheep (TS4 and TS5) before treatment. Dpi = days postinfection.

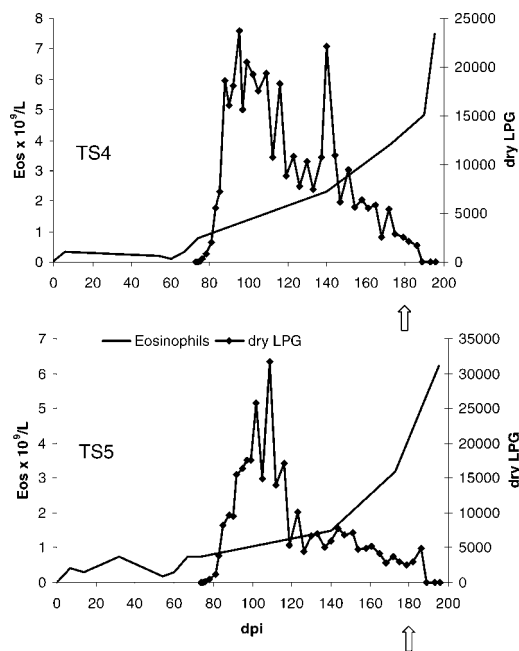


FIGURE 5. Peripheral eosinophil counts (Eos $\times 10^9/l$) and larvae per gram of dry feces (dry LPG) for infected thinhorn sheep (TS4 and TS5). Following the first treatment with ivermectin (arrow) at 180 days postinfection (dpi), larval counts were not 0, as suggested by the scale of these graphs, until 200 dpi.

eosinophil counts in a control sheep (TS7) after 280 dpi probably reflect experimental infection with a gastrointestinal parasite. No abnormalities were observed in serum chemistry panels from any sheep.

At 79 dpi for SS1, all three Stone's sheep developed transient bloody diarrhea due to bovine corona virus identical to that isolated from similarly affected calves

housed nearby (Jenkins and West, unpubl. data). At 173 dpi (101 days after patency), following exertion, SS1 died with fluid draining from the lungs, and hemorrhagic

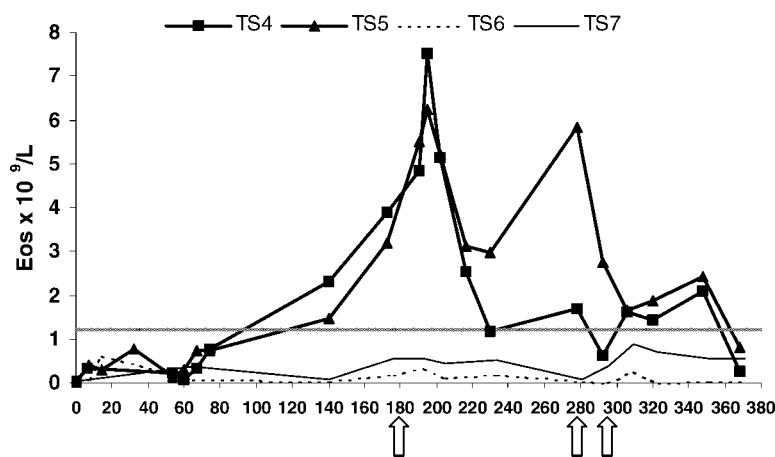


FIGURE 4. Peripheral eosinophil counts (Eos $\times 10^9/l$) for infected (TS4 and TS5) and control (TS6 and TS7) thinhorn sheep. Dpi = days postinfection, arrows indicate treatment with ivermectin, and the hatched line corresponds to 1.2×10^9 eosinophils/l.

foam in the airways. At 92 dpi (19 days after patency), following anesthesia the previous day, SS3 died with rumen fluid draining from the nose and mouth. Granulomatous inflammation, hemorrhage, and edema associated with high intensities of eggs and larvae of *P. odocoilei* were observed on histopathology of the lungs of both SS1 and SS3, although this pattern was somewhat obscured in SS3 by aspiration of rumen contents, possibly agonally. At 84 dpi (16 days after patency), SS2 presented staggering, with what appeared to be a left hind lameness, and later that day had a prolonged recovery from anesthesia, was shaky and unable to rise without difficulty, and was unusually aggressive. The leukogram (neutrophilia with left shift and toxic change) suggested inflammation consistent with severe, chronic, bacterial pneumonia, which was confirmed on post-mortem following euthanasia at 87 dpi.

TS5 (infected) and TS6 (control) developed signs consistent with a mild bacterial pneumonia shortly after anesthesia at 0 dpi, but these resolved within 2–3 wk following antibiotic treatment. Otherwise, no clinical abnormalities were observed in TS4–TS7 until 54 dpi, when the two infected sheep (TS4 and TS5) developed depression and incoordination, had difficulty getting up and lying down, lay with hind, and sometimes fore, limbs in full extension, and assumed a “stacked up” posture (Fig. 6). If made to move, the animals frequently slipped and fell, and spontaneously crossed hind limbs when turning or trying to lie down. Both animals ground their teeth, and TS4 rubbed her head frequently. Treatment with an anti-inflammatory analgesic (1 mg/kg intramuscular [IM] flunixin meglumine, 50 mg/ml, Cronyxin™, Bioniche Animal Health Inc., Belleville, Ontario, Canada) at 55 and 67 dpi did not alleviate clinical signs. Examination by large animal clinicians, including specific tests of neurologic function (sensation, reflexes, placing reactions, gait) at 60 and 67 dpi established that signs were consistent with posterior ataxia, loss of conscious pro-

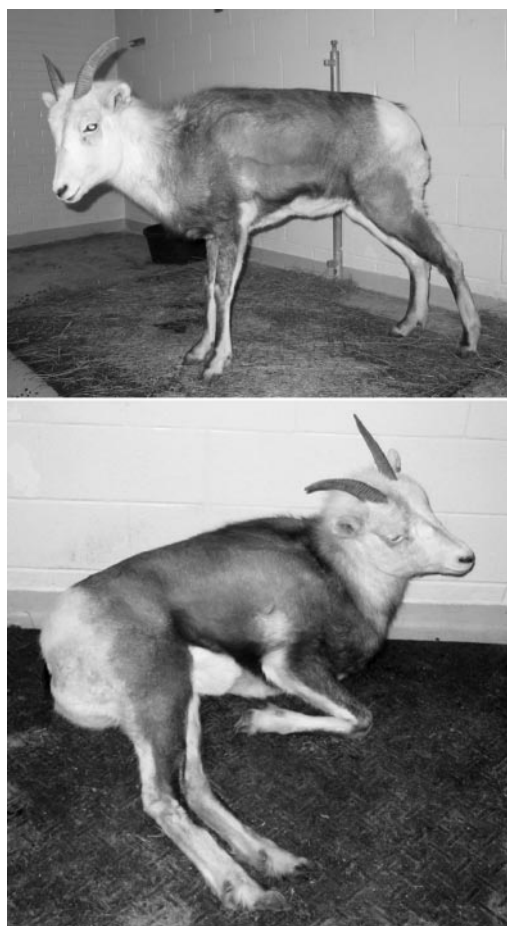

FIGURE 6. Abnormal posture of a thinhorn sheep (TS4) at 55 days following infection with *P. odocoilei*, 18 days before patency. Note that the majority of weight is carried on the forelegs when standing, and that the hind limbs are abnormally extended, both standing and in sternal recumbency.

prioception, increased extensor tone, exaggerated reflexes, and hyperesthesia. At 61 dpi, eosinophilic pleocytosis, hemorrhage, and increased total protein were present in CSF from infected (TS4 and TS5), but not control (TS6 and TS7), sheep (Table 2). There was an equivocal increase in the β -globulin protein fraction in the CSF of TS4 and TS5, but not TS7 (not available for TS6), and no abnormalities were observed in serum protein profiles of any of the four sheep. Antibodies for *Parelaphostrongylus* spp. were detected in the cerebrospinal fluid and serum of

TABLE 2. Cerebrospinal fluid cytology and protein for thinhorn sheep experimentally infected with *Parelaphostrongylus odocoilei* (TS4 and TS5) and uninfected control animals (TS6 and TS7).

	TS4	TS5	TS6	TS7
Eosinophils (%)	67.5	70	0	NA ^a
Mononuclears (%)	31	28.5	100	NA
Neutrophils (%)	1	1.5	0	NA
Plasma cells (%)	0.5	0	0	NA
Nucleated cells × 10 ⁶ /l	105	149	3	1
RBC × 10 ⁶ /l	1,951	818	272	27
Total protein (g/l)	2.4	2.2	0.3	0.3

^a Not available because of the low numbers of nucleated cells, which is normal in CSF.

infected, but not control, sheep. Neurologic signs stabilized at patency and subsequently disappeared until a mild recurrence in TS4, 20 days following the first treatment with ivermectin. At this time, this sheep also developed signs consistent with neurologic bladder dysfunction, with frequent (≤ 1 –2 min) posturing to urinate, spastically producing only a small amount of urine each time. The urinary abnormalities resolved within a few days, but this sheep dragged the dorsal surface of the right hind foot slightly until the end of the monitoring period. Onset of shedding of the winter coat, which began in April 2004 for the two control sheep (TS6 and TS7), was delayed until June–July 2004 for the two infected sheep (TS4 and TS5). Uninfected control sheep showed no clinical abnormalities at any time.

DISCUSSION

This is the first time that the life cycle of *P. odocoilei* has been completed in experimentally infected slugs (*D. laeve*) and thinhorn sheep (*O. dalli*). Sheep were each infected with 200 L3, a “moderate” experimental inoculum based on doses of 14–1,000 L3 of *P. odocoilei* administered to mule deer as a single exposure (Platt and Samuel, 1978b; Pybus and Samuel, 1984a, b). Recovery rate of adult *P. odocoilei* (38%) from a Stone’s sheep at necropsy on 173 dpi was comparable to the mean recovery rate of $45 \pm 8\%$ reported in mule deer experimentally infected with 300 L3 of *P. odocoilei* (Pybus and Samuel,

1984b). Nematode recovery rates were lower in two Stone’s sheep examined earlier in patency, which may have been because of the small size of muscle hemorrhages associated with adult nematodes early in infection (Pybus and Samuel, 1984a; Lankester and Hauta, 1989). Using the same recovery techniques, infection intensities in the experimentally infected Stone’s sheep (14, 27, and 75 adult worms per carcass) were similar to the range of 16–56 worms per carcass in seven naturally infected Dall’s sheep in the Mackenzie Mountains, Northwest Territories (Jenkins, Kutz, and Veitch, unpubl. data).

The prepatent period in five thinhorn sheep (68–74 days) was longer than that reported for mule deer infected with up to 334 L3 of *P. odocoilei* (45–62 days), but similar to that reported in black-tailed deer and moose infected with 50–750 L3 of *P. odocoilei* (58–72 days) (Platt and Samuel, 1978b; Pybus and Samuel, 1984b). The pattern of larval shedding in thinhorn sheep was similar to that observed in mule deer infected with *P. odocoilei*, with larval counts increasing for the first 3–4 wk, peaking at 20–40 days after patency, then reaching a plateau or gradually declining over a period of weeks to months (Platt and Samuel, 1978b; Pybus and Samuel, 1984b). Differences in patterns and magnitude of larval shedding among sheep in the current study likely reflect individual variation in susceptibility or immunity. Stressors, such as fasting or anesthesia, were associated with transient

peaks in larval shedding (Fig. 1); stress-related immunosuppression has been linked to increased shedding of larvae of *E. rangiferi* (Gaudernack et al., 1984).

Stone's sheep infected with 200 L3 of *P. odocoilei* developed relative eosinophilia and weight loss, similar to the mild eosinophilia and overall loss of condition observed in mule deer fawns experimentally infected with 300 L3 of *P. odocoilei* (Pybus and Samuel, 1984a). Absolute eosinophilia in the two thinhorn hybrids was associated with a spontaneous decrease in larval counts as well as treatment-induced inflammatory destruction of parasites. Marked weight loss in the two thinhorn hybrids that developed neurologic signs could, in part, reflect muscle atrophy due to inactivity, whereas delayed shedding of the winter coat was likely a nonspecific indicator of poor health (Woolf and Kradel, 1973). Emaciation has been reported in other definitive hosts with naturally acquired infections of *P. odocoilei* (Brunetti, 1969; Pybus et al., 1984). Following treatment, infected sheep reached and even exceeded weights at time of infection, possibly, in part, because of seasonal effects; control sheep also gained weight at this time (Fig. 2).

Timing of the deaths of two experimentally infected Stone's sheep (SS1 and SS3) and pathology associated with eggs and larvae of *P. odocoilei* in the lungs suggest that infection was at least a contributing factor. Fatal respiratory failure following exertion has been observed in a naturally infected Dall's yearling with similar pulmonary lesions associated with *P. odocoilei* (Kutz, Bollinger, Jenkins, unpubl. data). Two mule deer experimentally infected with *P. odocoilei* developed clinical signs suggestive of gastroenteritis shortly after patency and had severe interstitial pneumonia on postmortem (Platt and Samuel, 1978b). Pybus and Samuel (1984a) found that all experimentally infected mule deer developed signs of respiratory distress at 20–25 days postpatency, with one animal dying at 49 days postpatency “with much hemorrhagic foam. . .

discharged from the mouth and nares,” similar to that observed in SS1.

Aspiration and stress associated with multiple anesthetics likely caused the bacterial pneumonia that led to euthanasia of one older Stone's ewe (SS2). Mild bacterial pneumonia in two of four thinhorn hybrids following routine anesthesia, and transmission of bovine corona virus from nearby calves to the three Stone's sheep (the first report of this pathogen in thinhorn sheep), reinforce the need for strict biosecurity for wildlife species kept in captivity.

This is the first report of a neurologic syndrome associated with *P. odocoilei* in any host species. Loss of conscious proprioception and increased extensor tone in the hind limbs are associated with lesions in the superficial dorsolateral funiculi of the spinal cord between T3 and L3, whereas hyperesthesia is associated with lesions of the dorsal roots (DeLahunta, 1983). Neurogenic bladder dysfunction (possibly reflex dyssynergia or detrusor hyperreflexia) of one thinhorn sheep following treatment can be linked to partial disruption of the long spinocerebellar tracts (superficial lateral funiculi) (Oliver et al., 1997), possibly due to inflammation associated with dying nematodes. The Stone's ewe that was euthanized because of bacterial pneumonia first presented with unilateral lameness and staggering, which may have been ataxia or weakness; without a neurologic examination, the two cannot easily be differentiated. The clinical signs that we observed were similar to those described in both typical and atypical hosts infected with *E. rangiferi* (which localizes in the leptomeninges and subarachnoid space), or with *Parelaphostrongylus tenuis* (which invades the gray matter of the dorsal horns before migrating to the subdural space and venous sinuses) (Handeland, 1994; Pybus et al., 1996; Anderson, 2000; Lankester, 2001). Clinical signs of cerebrospinal parelaphostrongylosis and elaphostrongylosis are nonspecific, often multifocal, and difficult to localize (Anderson, 1968).

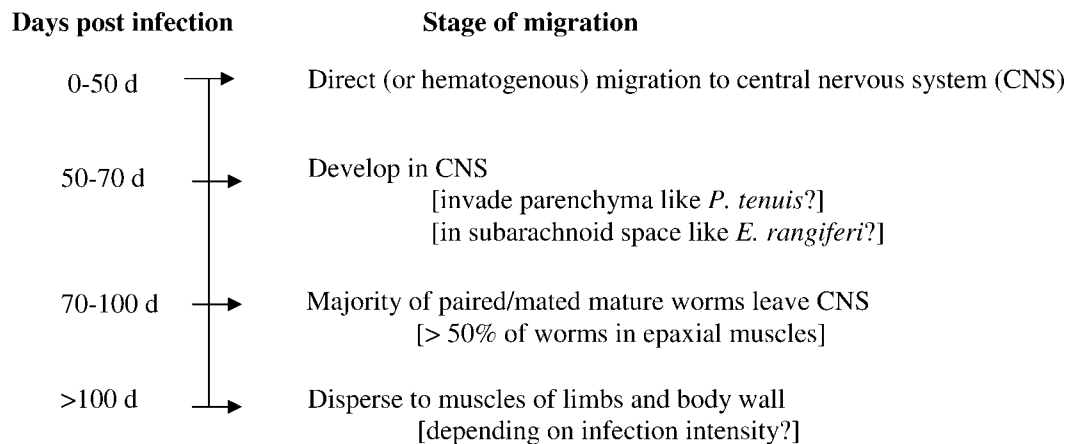


FIGURE 7. Proposed migration route for *P. odocoilei* in thinhorn sheep based on the current study, findings in experimentally infected mule deer (Pybus and Samuel, 1984b), and the migration route of *E. rangiferi* in reindeer (Hemmingsen et al., 1993).

Clinical signs, as well as eosinophilic inflammation and hemorrhage in cerebrospinal fluid, would be considered diagnostic for cerebrospinal nematodiasis in domestic animals (Mayhew et al., 1976; DeLahunta, 1983). These findings in the thinhorn hybrids, combined with detection of parasite-specific antibody in the CSF (Dew et al., 1992), strongly suggest that *P. odocoilei* was present in the CNS and was the cause of inflammation in the subarachnoid space, leptomeninges, and superficial dorsal regions of the spinal cord and nerve roots. Onset of clinical signs at 20 days before patency and cessation at patency are consistent with transient migration of immature *P. odocoilei* through the CNS, similar to the route demonstrated for *E. rangiferi* (Hemmingsen et al., 1993) (Fig. 7). The recurrence of clinical signs and mild residual gait abnormalities in one animal following treatment suggests that, like *E. rangiferi*, some nematodes have prolonged residence in the CNS (Hemmingsen et al., 1993). Magnetic resonance imaging (MRI) of the spinal cord at this time did not reveal nematodes or lesions. MRI at the onset of clinical signs before patency might have been revealing (Wood et al., 1991) but was delayed until after treatment because animals would likely not have survived the necessary extended anesthesia.

Definitive neurologic signs developed in only two of the five experimentally infected sheep. In addition to variation in host factors, such as genetics and age, these two sheep had been previously exposed to *U. pallikuukensis*, which did not establish but may have primed the immune system against protostrongylids. The spontaneous decline in larval shedding accompanied by marked eosinophilia in these two sheep suggests a strong immune response against *P. odocoilei*. Increased severity of inflammation associated with neural migration may have caused a normally subclinical process to become clinically evident. Alternatively, a stronger immune response in these two animals may have driven *P. odocoilei* into the "immunological harbor" of the CNS (Hemmingsen et al., 1993), implying that neural migration of *P. odocoilei* may not normally occur.

A neural migration for *P. odocoilei* and *P. andersoni* has, however, been suggested previously, based on the migration pattern of related parasites (Anderson, 1968) and because adults, eggs, and L1 of both "muscle-worm" species have been found in the epidural tissues and vertebral canals in experimentally infected deer (Pybus, 1983; Pybus and Samuel, 1984b). In early patency, two white-tailed deer experimentally infected with 5,000 L3 of *P. andersoni*, and in the

PPP one mule deer infected with 300 L3 of *P. andersoni*, developed unilateral or bilateral posterior lameness and weakness as well as postural and gait abnormalities that, in retrospect, could be neurologic (Nettles and Prestwood, 1976; Pybus, 1983). Serial post-mortem examinations of the CNS of experimentally infected hosts are needed to confirm the migration route of these “muscleworms”; to our knowledge, such examinations have not been accomplished for *P. odocoilei* or *P. andersoni* in the PPP in any definitive host. No adult *P. odocoilei* were found on gross examination of the vertebral canal or neural parenchyma of the three experimentally infected Stone’s sheep examined after patency or from naturally infected Dall’s sheep (Jenkins, Kutz, and Veitch, unpubl. data); however, detection may depend on the stage of infection as well as techniques used for examination (Pybus and Samuel, 1984b). Further experimental work is needed to determine if neurologic signs occur in thinhorn sheep infected with *P. odocoilei* at doses and methods of exposure comparable to naturally acquired infections.

If detailed and timely examinations of the CNS of both experimentally and naturally infected hosts confirm the hypothesis that the “muscleworms” (*P. andersoni* and *P. odocoilei*) are neurotropic, the life history patterns and phylogeny of the elaphostrongylines may need to be revisited (Platt, 1984; Carreno and Lankester, 1994). Migration through the CNS followed by establishment in skeletal muscles may be the ancestral pattern, occurring in all species of *Elaphostrongylus* and, possibly, in *P. odocoilei* and *P. andersoni*. The CNS-only migration of *P. tenuis* may represent attenuation or loss of the ancestral pattern. If the “muscleworms” (*P. andersoni* and *P. odocoilei*) are neurotropic, this supports the alternative phylogeny outlined by Platt (1984), in which *P. odocoilei* is the sister of *P. tenuis* and *P. andersoni*. Further experimental work and molecular characterization are needed to resolve fully the phylogeny of the elaphostrongylines.

Treatment for protostrongylid parasites

in bighorn sheep has been a common, if controversial, management intervention (Schmidt et al., 1979; Jones and Worley, 1997; Miller et al., 2000), and there has been significant interest in the feasibility of such treatment in thinhorn sheep. Following parenteral ivermectin, neurologic signs recurred and larval shedding ceased in one thinhorn hybrid infected with *P. odocoilei*. In the other thinhorn hybrid, which remained clinically normal following treatment, larval shedding was transiently suppressed but not eliminated, as reported in cervids infected with *P. andersoni*, *P. tenuis*, and *E. cervi* (Kocan, 1985; Watson, 1985; Samuel and Gray, 1988). An extended monitoring period (at least 69 days in the current study) was necessary to detect resumption of larval shedding. Multiple treatments with oral fenbendazole did not eliminate shedding of *Protostrongylus* spp. larvae in at least one naturally infected Stone’s sheep or in a thinhorn hybrid experimentally infected with *Protostrongylus stilesi* (Jenkins and Skific, unpubl. data). For these reasons, anthelmintic treatment may not be effective or realistic for translocations or health management of thinhorn sheep infected with protostrongylid parasites.

Mixed infections with both *P. odocoilei* and *P. stilesi* are common in Dall’s and Stone’s sheep in the Subarctic (Jenkins et al., 2005), and additive, or even synergistic, pulmonary pathology is likely (Petney and Andrews, 1998; Kutz et al., 2001). Bighorn sheep (*Ovis canadensis*) undergo all-age die-offs due to respiratory disease (which may involve preexisting lung damage by protostrongylid lungworms), and thinhorn sheep are susceptible to fatal pneumonia (Foreyt et al., 1996; Jenkins et al., 2000). Thinhorn sheep inhabit a high-latitude, high-altitude environment and are subject to predation by wolves. Parasites that cause respiratory compromise at high-infection intensities (such as *P. stilesi* in bighorn sheep, and *Echinococcus granulosus* in moose) may increase the susceptibility of ungulates to such chase-preda-

tors (Uhazy et al., 1973; Messier et al., 1989). Also, if *P. odocoilei* causes even minor, transient neurologic signs in naturally infected thinnhorn sheep, it could increase susceptibility to predation and falls in hazardous terrain. It would be interesting to compare health, fecundity, and causes of mortality in Dall's sheep populations infected with both *P. odocoilei* and *P. stilesi* (e.g., in the Mackenzie Mountains, Northwest Territories) with nearby populations where only *P. stilesi* is present (e.g., in the Nahanni or Richardson Mountains, Northwest Territories) (Hoberg et al., 2002; Jenkins et al., 2005).

Dall's sheep in the Mackenzie Mountains will soon share range with muskoxen (*Ovibos moschatus moschatus*) infected with *U. pallikuukensis* (Kutz et al., 2004). Although *U. pallikuukensis* does not establish in Dall's sheep, it may "prime" a stronger immune response against migrating *P. odocoilei*, resulting in clinical disease. Although it is not known if muskoxen can be infected with *P. odocoilei*, muskoxen in the Richardson Mountains are naturally infected with *P. stilesi* from Dall's sheep and, elsewhere, are susceptible to cerebrospinal elaphostrongylosis (Holt et al., 1990; Hoberg et al., 2002). Historical precedent for colonization of new host species by protostrongylid parasites (i.e., *P. stilesi* in muskoxen and *P. odocoilei* in thinnhorn sheep) and the potential health consequences for naïve hosts warrant continued surveillance by wildlife managers.

The widespread geographic distribution, high prevalence, resistance to treatment, and the possibility of respiratory and neurologic disease indicate that *P. odocoilei* may constitute a significant emerging disease risk for thinnhorn sheep. Because of its wide host range and the possibility of a neural migration, *P. odocoilei* should be considered a differential diagnosis for dorsal-spined larvae in feces and cerebrospinal nematodiasis (often identified only on histopathology) in a number of ungulate hosts, including mule and black-tailed deer, caribou, moose, mountain goat, and

bighorn and thinnhorn sheep. Definitive diagnosis and differentiation from closely related elaphostrongylines require comparative morphology of adult nematodes or identification of larvae using validated molecular techniques.

ACKNOWLEDGMENTS

We thank Susan Kutz at WCVN, Alasdair Veitch, and Brett Elkin from the Department of Environment and Natural Resources, Northwest Territories, Canada for their invaluable assistance and support. We gratefully acknowledge the contributions and expertise of Greg Appleyard at WCVN for molecular identification of larvae; Dele Ogunremi at the Center for Animal Parasitology, Canadian Food Inspection Agency, Saskatoon Laboratory, for immunological analyses; and Trent Bollinger, Canadian Cooperative Wildlife Health Center, WCVN, for necropsies and pathology. Three Stone's sheep were donated by the Assiniboine Park Zoo, Winnipeg, Manitoba. WCVN personnel and members of Prairie Diagnostic Services who were instrumental in the maintenance and monitoring of thinnhorn sheep include staff of the Animal Care Unit (Monique Burmester, Kyle Constantinoff, Marlow Thue, and Doug Walde); parasitology technicians and summer students (Jennifer Dodd, Farhad Ghandi, Darren Harder, Mathew Herperger, Jeremy Thomas, and Brent Wagner); veterinary clinicians, technicians, and students (Brenda Beierle, Carol Black, Nigel Caulkett, Chris Clark, Elena Garde, Sarah Lightfoot Wagner, Sharon Martin, Marcello Martinez, Matt Read, Jennifer Skific, and Kim Tryon); and researchers in the departments of Veterinary Pathology, Microbiology, and Biomedical Sciences (Manuel Chirino-Trejo, Ted Leighton, Rob McCorkell, Vikram Misra, and Keith West). Many thanks for helpful suggestions by two anonymous reviewers. This project was funded by the following organizations: Association of Mackenzie Mountain Outfitters; Canadian Wildlife Federation; Department of Resources, Wildlife, and Economic Development, Government of the Northwest Territories; Foundation for North American Wild Sheep, national and regional chapters of Alberta, Iowa, Utah, and Washington; Fraternity of the Desert Bighorn; Safari Club International (Pittsburgh Chapter); WCVN Interprovincial Graduate Student Scholarship; and the Wild Sheep Society of British Columbia.

LITERATURE CITED

ANDERSON, R. C. 1968. The pathogenesis and transmission of neurotropic and accidental nematode

- parasites of the central nervous system of mammals and birds. *Helminthological Abstracts* 37: 191–210.
- . 1972. The ecological relationships of meningeal worm and native cervids in North America. *Journal of Wildlife Diseases* 8: 304–310.
- . 2000. Nematode parasites of vertebrates: their development and transmission. CABI Publications, New York, New York, 650 pp.
- BALL, M. C., M. W. LANKESTER, AND S. P. MAHONEY. 2001. Factors affecting the distribution and transmission of *Elaphostrongylus rangiferi* (Protostrongylidae) in caribou (*Rangifer tarandus caribou*) of Newfoundland, Canada. *Canadian Journal of Zoology* 79: 1265–1277.
- BRUNETTI, O. A. 1969. Redescription of *Parelaphostrongylus* (Boev and Schuls, 1950) in California deer, with studies on its life history and pathology. *California Fish and Game* 55: 307–316.
- CARRENO, R. A., AND M. W. LANKESTER. 1994. A re-evaluation of the phylogeny of *Parelaphostrongylus* Boev & Schulz, 1950 (Nematoda: Protostrongylidae). *Systematic Parasitology* 28: 145–151.
- CRAPO, D. 2000. Benefits of outfitted hunting in the Northwest Territories Mackenzie Mountains. Report prepared for the Association of Mackenzie Mountain Outfitters, EXCEleration Corporation, Calgary, Alberta, Canada, 45 pp.
- DELAHUNTA, A. 1983. *Veterinary neuroanatomy and clinical neurology*. 2nd Edition, W. B. Saunders Co. Company, Philadelphia, Pennsylvania, 471 pp.
- DEW, T. L., D. D. BOWMAN, AND R. B. GRIEVE. 1992. Parasite-specific immunoglobulin in the serum and cerebrospinal fluid of white-tailed deer (*Odocoileus virginianus*) and goats (*Capra hircus*) with experimentally induced parelaphostrongylosis. *Journal of Zoo and Wildlife Medicine* 23: 281–287.
- FOREYT, W. J., R. M. SILFLOW, AND J. E. LAGERQUIST. 1996. Susceptibility of Dall's sheep (*Ovis dalli dalli*) to pneumonia caused by *Pasteurella haemolytica*. *Journal of Wildlife Diseases* 32: 586–593.
- FORRESTER, S. G., AND M. W. LANKESTER. 1997. Extracting protostrongylid nematode larvae from ungulate feces. *Journal of Wildlife Diseases* 33: 511–516.
- GAUDERNACK, G., O. HALVORSEN, A. SKORPING, AND K. A. STOKKAN. 1984. Humoral immunity and output of first-stage larvae of *Elaphostrongylus rangiferi* (Nematoda, Metastrongyloidea) by infected reindeer, *Rangifer tarandus tarandus*. *Journal of Helminthology* 58: 13–18.
- HANDELAND, K. 1994. Experimental studies of *Elaphostrongylus rangiferi* in reindeer (*Rangifer tarandus tarandus*): Life cycle, pathogenesis, and pathology. *Journal of Veterinary Medicine, Series B* 41: 350–365.
- HEMMINGSEN, W., O. HALVORSEN, AND A. SKORPING. 1993. Migration of adult *Elaphostrongylus rangiferi* (Nematoda: Protostrongylidae) from the spinal subdural space to the muscles of reindeer (*Rangifer tarandus*). *Journal of Parasitology* 79: 728–732.
- HOBERG, E. P., L. POLLEY, A. GUNN, AND J. S. NISHI. 1995. *Umingmakstrongylus pallikuukensis* gen nov et sp nov (Nematoda: Protostrongylidae) from muskoxen, *Ovibos moschatus*, in the central Canadian Arctic, with comments on biology and biogeography. *Canadian Journal of Zoology* 73: 2266–2282.
- , S. J. KUTZ, J. NAGY, E. JENKINS, B. ELKIN, M. BRANIGAN, AND D. COOLEY. 2002. *Protostrongylus stilesi* (Nematoda: Protostrongylidae): Ecological isolation and putative host-switching between Dall's sheep and muskoxen in a contact zone. *Comparative Parasitology* 69: 1–9.
- HOBMAIER, A., AND M. HOBMAIER. 1934. *Elaphostrongylus odocoilei* n.sp., a new lungworm in black-tailed deer (*Odocoileus columbianus*). Description and life history. *Proceedings of the Society for Experimental Biology and Medicine* 31: 509–514.
- HOLT, G., C. BERG, AND A. HAUGEN. 1990. Nematode related spinal myelomeningitis and posterior ataxia in muskoxen (*Ovibos moschatus*). *Journal of Wildlife Diseases* 26: 528–531.
- JENKINS, E. J., S. J. KUTZ, A. M. VEITCH, B. T. ELKIN, M. CHIRINO-Trejo, AND L. POLLEY. 2000. Pneumonia as a cause of mortality in two Dall's sheep in the Mackenzie Mountains, Northwest Territories, Canada. *Proceedings of the Northern Wild Sheep and Goat Council* 12: 40–53.
- , G. D. APPLEYARD, E. P. HOBERG, B. M. ROSENTHAL, S. J. KUTZ, A. M. VEITCH, H. M. SCHWANTJE, B. T. ELKIN, AND L. POLLEY. 2005. Geographic distribution of the muscle-dwelling nematode *Parelaphostrongylus odocoilei* in North America, using molecular identification of first-stage larvae. *Journal of Parasitology* 91: 574–584.
- JONES, L. C., AND D. E. WORLEY. 1997. Use of fenbendazole for long-term control of protostrongylid lungworms in free-ranging Rocky Mountain bighorn sheep. *Journal of Wildlife Diseases* 33: 365–367.
- KOCAN, A. A. 1985. The use of ivermectin in the treatment and prevention of infection with *Parelaphostrongylus tenuis* (Dougherty) (Nematoda: Metastrongyloidea) in white-tailed deer (*Odocoileus virginianus* Zimmermann). *Journal of Wildlife Diseases* 21: 454–455.
- KUTZ, S., E. P. HOBERG, AND L. POLLEY. 1999. Experimental infections of muskoxen (*Ovibos moschatus*) and domestic sheep with *Umingmakstrongylus pallikuukensis* (Nematoda: Protostrongylidae): Parasite development, population structure, and pathology. *Canadian Journal of Zoology* 77: 1562–1572.
- , A. M. VEITCH, E. P. HOBERG, B. T. ELKIN, E. J. JENKINS, AND L. POLLEY. 2001. New host

- and geographic records for two protostrongylids in Dall's sheep. *Journal of Wildlife Diseases* 37: 761–774.
- , E. GARDE, A. VEITCH, J. NAGY, F. GHANDI, AND L. POLLEY. 2004. Muskox lungworm (*Umingmakstrongylus pallikuukensis*) does not establish in experimentally exposed thinhorn sheep (*Ovis dalli*). *Journal of Wildlife Diseases* 40: 197–204.
- LANKESTER, M. W. 2001. Extrapulmonary lungworms of cervids. In *Parasitic diseases of wild mammals*, 2nd Edition, W. M. Samuel, M. J. Pybus, and A. A. Kocan (eds.). Iowa State University Press, Ames, Iowa, pp. 228–278.
- , AND P. L. HAUTA. 1989. *Parelaphostrongylus andersoni* (Nematoda: Protostrongylidae) in caribou (*Rangifer tarandus*) of northern and central Canada. *Canadian Journal of Zoology* 67: 1966–1975.
- MAYHEW, I. G., A. D. LAHUNTA, J. R. GEORGI, AND D. G. ASPROS. 1976. Naturally occurring cerebrospinal parelaphostrongylosis. *Cornell Veterinarian* 66: 56–72.
- MESSIER, F., M. E. RAU, AND M. A. MCNEILL. 1989. *Echinococcus granulosus* (Cestoda: Taeniidae) infections and moose—Wolf population dynamics in southwestern Quebec. *Canadian Journal of Zoology* 67: 216–219.
- MILLER, M. W., J. E. VAYHINGER, D. C. BOWDEN, S. P. ROUSH, T. E. VERRY, A. N. TORRES, AND V. D. JURGENS. 2000. Drug treatment for lungworm in bighorn sheep: re-evaluation of a 20-year old management prescription. *Journal of Wildlife Management* 64: 505–512.
- NADASDY, P. 2003. Reevaluating the co-management success story. *Arctic* 56: 367–380.
- NETTLES, V. F., AND A. K. PRESTWOOD. 1976. Experimental *Parelaphostrongylus andersoni* infections in white-tailed deer. *Veterinary Pathology* 13: 381–393.
- OGUNREMI, O., M. LANKESTER, S. LORAN, AND A. GAJADHAR. 1999. Evaluation of excretory-secretory products and somatic worm antigens for the serodiagnosis of experimental *Parelaphostrongylus tenuis* infection in white-tailed deer. *Journal of Veterinary Diagnostic Investigation* 11: 515–521.
- OLIVER, J. E., M. D. LORENZ, AND J. N. KORNEGAY. 1997. *Handbook of veterinary neurology*. 3rd Edition, W. B. Saunders Co. Company, Toronto, Canada, 453 pp.
- PETNEY, T. N., AND R. H. ANDREWS. 1998. Multi-parasite communities in animals and humans: Frequency, structure and pathogenic significance. *International Journal for Parasitology* 28: 377–393.
- PLATT, T. R. 1984. Evolution of the Elaphostrongylinae (Nematoda: Metastrongyloidea: Protostrongylidae) parasites of cervids (Mammalia). *Proceedings of the Helminthological Society of Washington* 51: 196–204.
- , AND W. M. SAMUEL. 1978a. A redescription and neotype designation for *Parelaphostrongylus odocoilei* (Nematoda: Metastrongyloidea). *Journal of Parasitology* 64: 226–232.
- , AND W. M. SAMUEL. 1978b. *Parelaphostrongylus odocoilei*: Life cycle in experimentally infected cervids including the mule deer, *Odocoileus hemionus hemionus*. *Experimental Parasitology* 46: 330–338.
- PYBUS, M. J. 1983. *Parelaphostrongylus andersoni* Prestwood 1972 and *P. odocoilei* (Hobmaier and Hobmaier 1934) (Nematoda: Metastrongyloidea) in two cervid definitive hosts. PhD Thesis, University of Alberta, Edmonton, Alberta, Canada, 185 pp.
- , AND W. M. SAMUEL. 1984a. Lesions caused by *Parelaphostrongylus odocoilei* (Nematoda: Metastrongyloidea) in two cervid hosts. *Veterinary Pathology* 21: 425–431.
- , AND W. M. SAMUEL. 1984b. *Parelaphostrongylus andersoni* (Nematoda: Protostrongylidae) and *P. odocoilei* in two cervid definitive hosts. *Journal of Parasitology* 70: 507–515.
- , W. J. FOREYT, AND W. M. SAMUEL. 1984. Natural infections of *Parelaphostrongylus odocoilei* (Nematoda: Protostrongylidae) in several hosts and locations. *Proceedings of the Helminthological Society of Washington* 51: 338–340.
- , S. GROOM, AND W. M. SAMUEL. 1996. Meningeal worm in experimentally infected bighorn and domestic sheep. *Journal of Wildlife Diseases* 32: 614–618.
- SAMUEL, W. M., AND J. B. GRAY. 1988. Efficacy of ivermectin against *Parelaphostrongylus andersoni* (Nematoda, Metastrongyloidea) in white-tailed deer (*Odocoileus virginianus*). *Journal of Wildlife Diseases* 24: 491–495.
- SCHMIDT, R. L., C. P. HIBLER, T. R. SPRAKER, AND W. H. RUTHERFORD. 1979. An evaluation of drug treatment for lungworm in bighorn sheep. *Journal of Wildlife Management* 43: 461–467.
- UHAZY, L. S., J. C. HOLMES, AND J. G. STELFOX. 1973. Lungworms in the Rocky Mountain bighorn sheep of western Canada. *Canadian Journal of Zoology* 51: 817–824.
- WATSON, T. G. 1985. Efficacy of drenching red deer and wapiti with particular reference to *Elaphostrongylus cervi*. *New Zealand Journal of Zoology* 12: 450.
- WOOD, G., S. DELAMONT, M. WHITBY, AND R. BOYLE. 1991. Spinal sensory radiculopathy due to *Angiostrongylus cantonensis* infection. *Postgraduate Medical Journal* 67: 70–72.
- WOOLF, A., AND D. C. KRADEL. 1973. Mortality in captive bighorn sheep—Clinical, hematological, and pathological observations. *Journal of Wildlife Diseases* 9: 12–17.

Received for publication 15 December 2004.