

## **Contagious Mucocutaneous Dermatitis of the Mountain Hare (*Lepus timidus*): Pathology and Cause**

Authors: Saari, Seppo. A. M., Rudbäck, Eeva, Niskanen, Mirjami, Syrjälä, Paula, Nylund, Minna, et al.

Source: Journal of Wildlife Diseases, 41(4) : 775-782

Published By: Wildlife Disease Association

URL: <https://doi.org/10.7589/0090-3558-41.4.775>

---

BioOne Complete ([complete.BioOne.org](https://complete.BioOne.org)) is a full-text database of 200 subscribed and open-access titles in the biological, ecological, and environmental sciences published by nonprofit societies, associations, museums, institutions, and presses.

Your use of this PDF, the BioOne Complete website, and all posted and associated content indicates your acceptance of BioOne's Terms of Use, available at [www.bioone.org/terms-of-use](https://www.bioone.org/terms-of-use).

Usage of BioOne Complete content is strictly limited to personal, educational, and non - commercial use. Commercial inquiries or rights and permissions requests should be directed to the individual publisher as copyright holder.

---

BioOne sees sustainable scholarly publishing as an inherently collaborative enterprise connecting authors, nonprofit publishers, academic institutions, research libraries, and research funders in the common goal of maximizing access to critical research.

# SHORT COMMUNICATIONS

Journal of Wildlife Diseases, 41(4), 2005, pp. 775–782  
© Wildlife Disease Association 2005

## Contagious Mucocutaneous Dermatitis of the Mountain Hare (*Lepus timidus*): Pathology and Cause

**Seppo. A. M. Saari,<sup>1,6</sup> Eeva Rudbäck,<sup>2,3</sup> Mirjami Niskanen,<sup>4</sup> Paula Syrjälä,<sup>4</sup> Minna Nylund,<sup>5</sup> and Marjukka Anttila<sup>2</sup>** <sup>1</sup>Department of Basic Veterinary Sciences, Faculty of Veterinary Medicine, PO Box 66, FIN-00014 University of Helsinki, Finland; <sup>2</sup>Department of Pathology, National Veterinary and Food Research Institute, PO Box 45, FIN-00580 Helsinki, Finland; <sup>3</sup>Present address: Helsinki Zoo, PO Box 4600, FIN-00099 Helsinki, Finland; <sup>4</sup>Kuopio Department, National Veterinary and Food Research Institute, Neulamäentie 4, FIN-70210 Kuopio, Finland; <sup>5</sup>Oulu Regional Unit, National Veterinary and Food Research Institute, PO Box 517, FIN-90101 Oulu, Finland; <sup>6</sup>Corresponding author (email: seppo.saari@helsinki.fi)

**ABSTRACT:** Contagious mucocutaneous dermatitis is a frequently encountered disease of mountain hares (*Lepus timidus*) in Finland. We describe the histopathologic changes and propose an etiologic cause for this disorder. Fifty-three cases collected during 1982–2000 were examined histologically. Transmission electron microscopy was performed in one case. In fully developed lesions, keratinocytes in epidermis and follicular infundibula were swollen and contained large eosinophilic intracytoplasmic inclusion bodies with marked reticular and ballooning degeneration. In later stages, there was marked necrosis and ulceration with severe pyogranulomatous and suppurative inflammation. At this stage, no viral inclusions were detectable, but secondary *Staphylococcus warnerii* infection was present in most cases. In late lesions, there was dermal fibrosis with epidermal hyperplasia. No spiral-shaped bacteria suggesting treponematosis were detected at any stage. Ultrastructurally, swollen epidermal and follicle infundibular cells contained round intracytoplasmic inclusion bodies with a myriad of virions typical of poxvirus with a biconcave nucleocapsid core, two lateral bodies, and a clearly discernible outer lipoprotein capsule. The findings suggest that contagious mucocutaneous dermatitis in mountain hares is a viral disease caused by a poxvirus. The disease is often complicated by secondary bacterial infection, most commonly *S. warnerii*.

**Key words:** Mountain hare, mucocutaneous dermatitis, poxvirus, *Staphylococcus warnerii*, ulcerative dermatitis.

Contagious mucocutaneous dermatitis of mountain hares (*Lepus timidus*) in Finland is characterized by proliferative lesions with marked crust formation at mucocutaneous junctions. The lesions are most often present on the lips and around

the nose (Fig. 1). Prepuce, vulva, conjunctiva, and sometimes skin of extremities may be affected as well. Diagnosis has been based on the presence of typical macroscopic lesions but etiology has remained unsolved. Viruses, bacteria, and even parasites have been suggested as the causative agent. Clinically, similar lesions have been reported in rabbits (*Oryctolagus cuniculus*) and European brown hares (*Lepus europeaus*) with bacterial syphilis, caused by *Treponema paraluis-cuniculi* and *T. paraluisleporis*. Based on these reports, wildlife pathologists have suggested that the disease in mountain hares is also caused by *Treponema* spp. In this retrospective study, we evaluated 53 cases of contagious mucocutaneous dermatitis in mountain hares examined during 1982–2000 in the laboratories of National Veterinary and Food Research Institute in Helsinki, Kuopio, and Oulu, Finland. We describe the histopathologic changes and bacteriologic findings and propose an etiologic agent and a new name for this disease.

During 1982–2000, 53 cases of contagious mucocutaneous dermatitis in mountain hares were diagnosed in Finland. Twenty-one of the affected animals were males and 13 were females. Sex could not be determined in all animals, because only the head was submitted to the laboratory in 19 cases. Complete necropsy was carried out when possible. Tissue samples taken at necropsy were fixed in 10% buff-

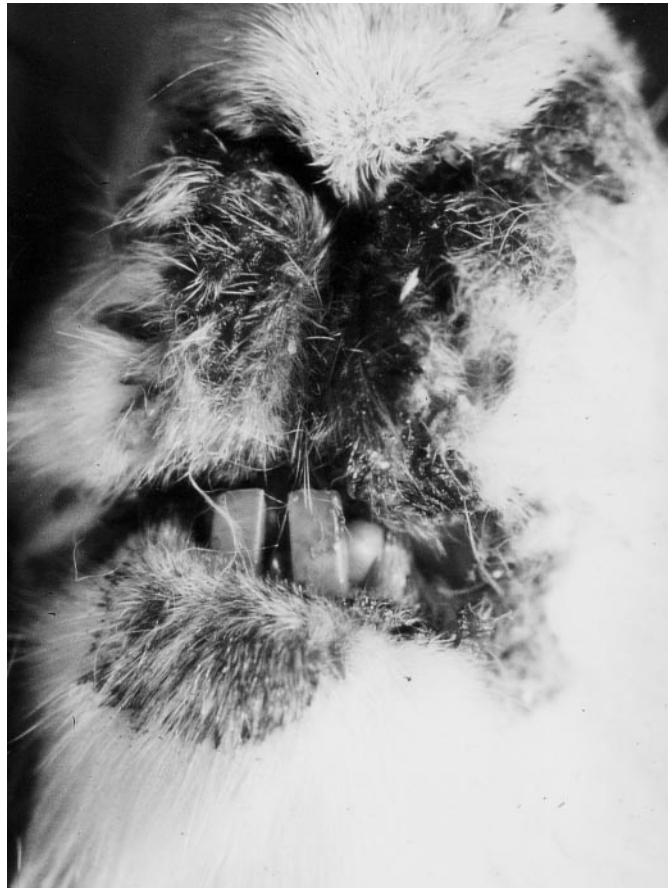

FIGURE 1. Typical clinical presentation of mucocutaneous poxvirus dermatitis of the mountain hare showing proliferative, crusting lesions of the mucocutaneous junctions of the mouth and nose.

ered formalin, routinely processed, cut at 4  $\mu\text{m}$ , and stained with hematoxylin and eosin (HE). Skin samples for histology were collected in 46 cases and also stained with the Bosma-Steiner method for visualizing spirochetes (De Koning et al., 1987).

Transmission electron microscopy was used in one case. Several small samples from formalin-fixed affected skin were trimmed into 1  $\text{mm}^3$  pieces, fixed for 2 hr in 2.5% glutaraldehyde in 0.1 M Sørensen phosphate buffer (pH 7.3). Samples were postfixed in 1% osmium tetroxide, dehydrated in acetone, embedded in epoxy resin, and polymerized. Ultrathin sections (0.06  $\mu\text{m}$ ) were stained with uranyl acetate and lead citrate. Sections were viewed

with a JEM 100 S transmission electron microscope (Jeol, Tokyo, Japan).

During 1990–2000, skin samples from 32 hares were cultured. The crust covering the skin was removed and the underlying inflamed dermis scraped with a blade. Removed material was stained with a Gram stain and culture was attempted on tryptose-soy-agar (TSA; supplemented with 5% bovine blood and incubated at 37 C for 2 days) or Saborraud agar (incubated at 20 C and 37 C). Nineteen samples were cultivated microaerophilically and anaerobically on Fastidious Anaerobe Agar (FAA) plates (Lab M, Bury, UK).

Bacteria were identified using standard biochemical methods. Appropriate api-methods (Bio Merieux: api STAPH, api 20

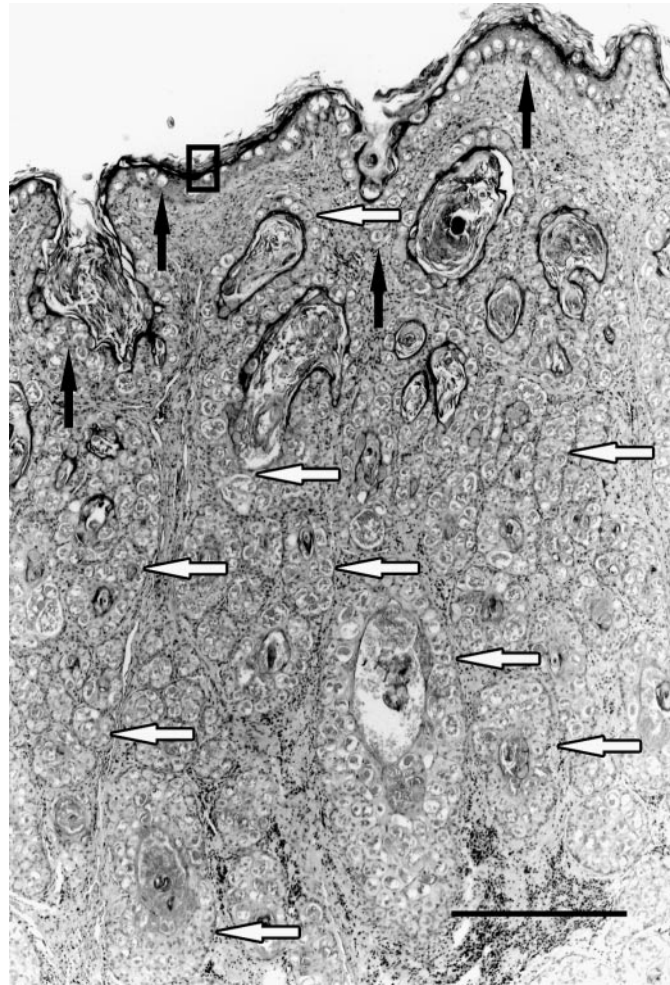


FIGURE 2. Fully developed acute lesion. Many of the keratinocytes in the epidermis (black arrows) and follicular infundibula (white arrows) are swollen and contain large intracytoplasmic viral inclusion bodies. Enlargement of the area in the rectangle is depicted in Figure 3. Hematoxylin and eosin, bar = 450  $\mu$ m.

E, api 20 NE) were selected. Coagulase test and Staphylect Plus (Oxoid) test were used to identify staphylococci spp. Gram stain, api 20 C AUX, and germ tests were used to identify yeast.

Because samples were from natural cases, they varied in stage of disease. In the fully developed acute lesions, multifocal clusters of swollen keratinocytes were present in hyperplastic epidermis. Changes extended to follicular infundibula. As a result of severe hydropic swelling, keratinocytes were large and pale. Numerous eosinophilic, often floccular, intracytoplasmic inclusion bodies were present, in particu-

lar, in cells with ballooning degeneration (Figs. 2, 3). In 12 cases (28%), myriads of inclusion bodies were present. Dermal lesions were sparse, consisting mainly of edema and mild superficial perivascular lymphocytic infiltration.

In later stages, there was marked necrosis of affected epidermis extending to the follicular infundibula with ulceration and marked transmigration of neutrophils into the superficial exudate forming a crust. Numerous coccoid bacteria were often present in the surface of the crust. No spiral-shaped bacteria suggesting treponematoses were found. Occasionally, there

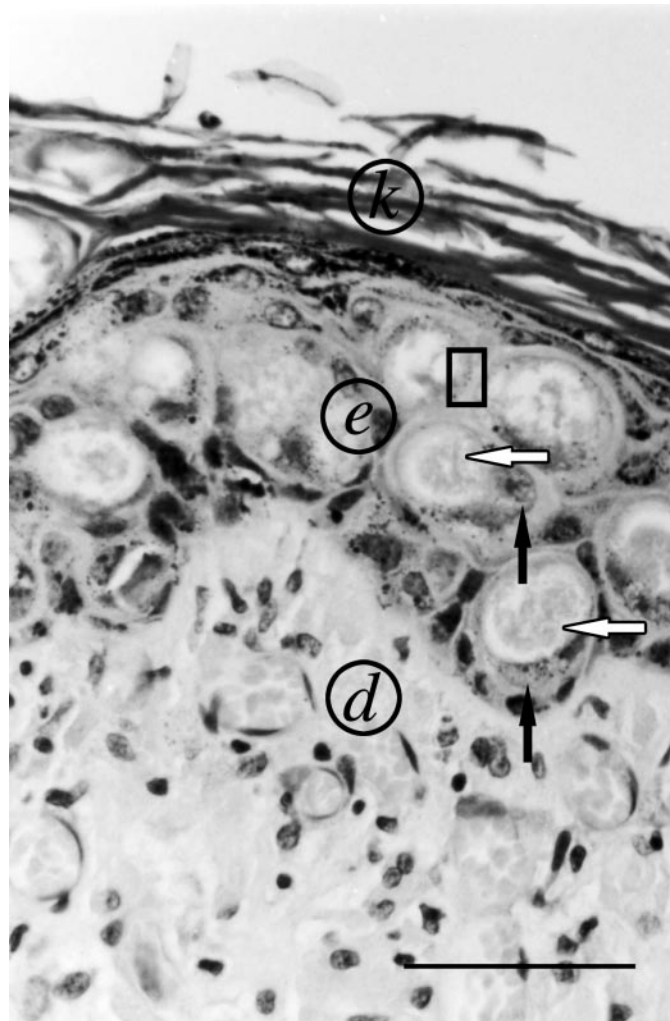


FIGURE 3. Fully developed acute lesion in the epidermis showing ballooning degeneration of the keratinocytes and large, floccular inclusion bodies. Nucleus (black arrow) and inclusion body (white arrow) in two keratinocytes are shown with the arrows. k = keratin layer, e = epidermis, d = dermis. Enlargement of the area in the rectangle is depicted in Figure 4. Hematoxylin and eosin, bar = 60  $\mu\text{m}$ .

was rupture of a hair follicle with leakage of keratin into the dermis with pyogranulomatous inflammatory reaction. Inclusion bodies were seldom detected at this stage. The degree of inflammation was severe in 33 cases (72%), moderate in nine cases (20%), and mild in three cases.

In chronic advanced lesions, there was variable dermal fibrosis and epidermal hyperplasia with mild to minimal infiltration of plasma cells with lesser numbers of lymphocytes and neutrophils. Dermal fibrosis was marked in three (7%) cases.

Ultrastructurally, the swollen epidermal and follicle infundibular keratinocytes contained round intracytoplasmic inclusion bodies with numerous virions (Fig. 4). The virions were large, ovoid, 300 nm  $\times$  130–150 nm, and typical for poxviruses in terms of size and shape, biconcave nucleocapsid core, two lateral bodies, and clearly discernible outer lipoprotein capsule (Fig. 5).

*Staphylococcus warneri* was isolated from 23 samples (72%); in 15 (47%) cases, the bacterium grew in pure culture. In seven samples, many other bacteria in-

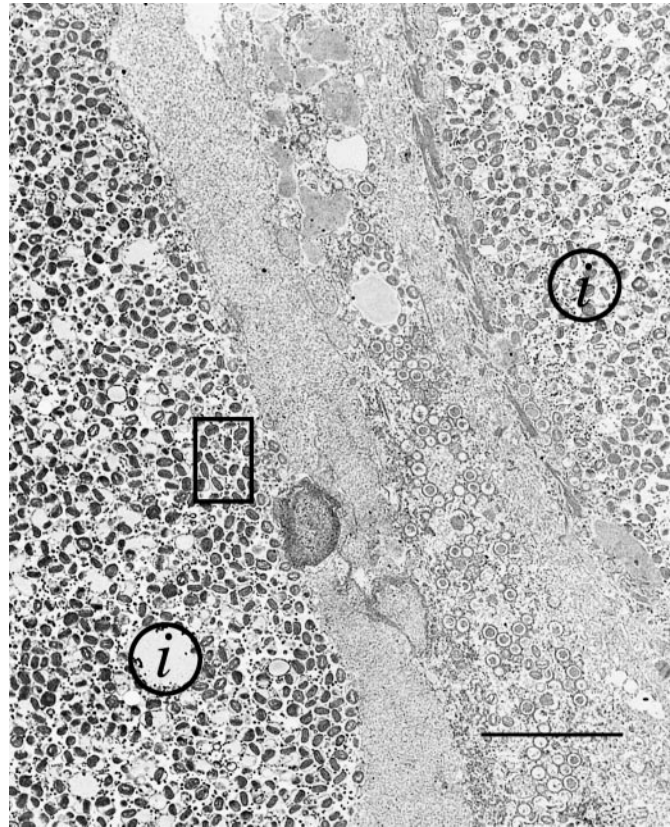


FIGURE 4. Two round inclusion bodies (i) with myriads of virions. Enlargement of the area in the rectangle is depicted in Figure 5. Transmission electron micrograph, bar = 3  $\mu$ m.

cluding *Staphylococcus aureus*, *Staphylococcus sciuri*, and *Staphylococcus chromogenes* or the yeast *Candida albicans* were isolated in addition to *S. warneri*. In six cases, *S. aureus*, *Escherichia coli*, or *Staphylococcus xylosus* was isolated in pure culture. In cases in which *S. warneri* grew in pure culture, massive numbers of gram-positive cocci were present on the skin surface histologically.

*Staphylococcus warneri* colonies were gray-white and clearly  $\beta$ -hemolytic after 1 day of culture and became yellowish after a longer incubation period. Bacteria were catalase-positive and oxidase-negative, did not coagulate rabbit plasma, and were negative in the Staphytest Plus test indicating that clumping factors were not present. They also grew in anaerobic conditions and were typical in api STAPH; however,

the number of nitrate-reducing, phosphatase-positive strains was greater than described in the standard.

The microscopic lesions described in this study represented a continuum of changes from an acute viral dermatitis to secondary pyoderma and finally to cutaneous scarring and substantiate that contagious mucocutaneous dermatitis of mountain hares in Finland is a viral disease. Numerous viral inclusions were present in the acute fully developed stage of the disease, which represented one third of the cases. This suggests that the period of virus replication is fairly short and is rapidly followed by epidermal necrosis and secondary pyoderma. Samples are often taken at the later stages of the disease when the secondary or chronic lesions predominate and no viral inclusions are present. In such cases, an eti-

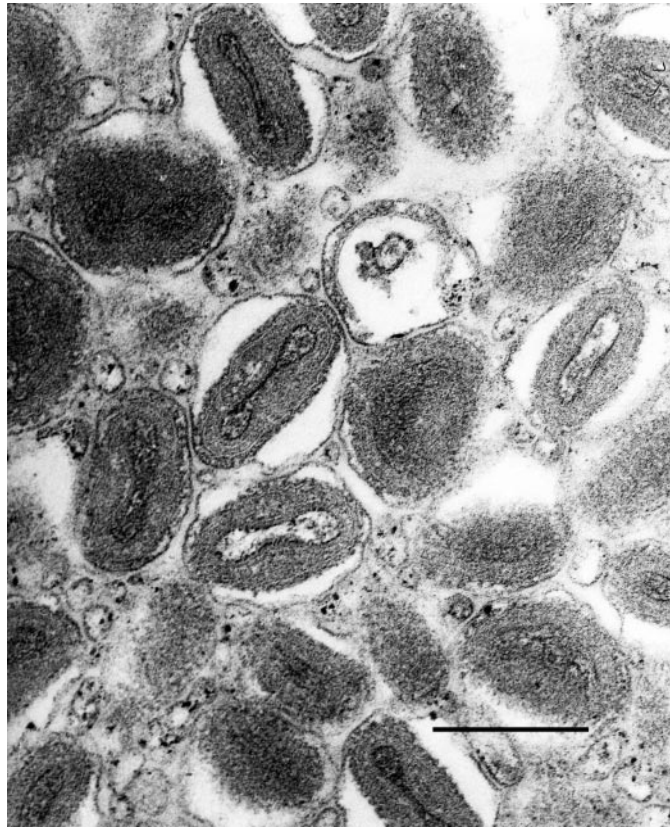


FIGURE 5. Cross sections of enveloped poxviruses. Biconcave nucleocapsid cores and the envelopes are clearly discernible. Transmission electron micrograph, bar = 0.3  $\mu\text{m}$ .

ologic diagnosis cannot be made. The secondary lesions described here are typical for many epitheliotrophic viral diseases. In our opinion, they have been given too much emphasis in the past; thus, the true nature of the disease has remained unsolved. The macroscopic and microscopic lesions were typical for a poxvirus infection. The presence of poxvirus in the inclusions was confirmed by electron microscopy. Proportions and dimensions of virions were suggestive of parapox virus (Quinn et al., 2002). However, molecular studies would be needed to characterize the virus more thoroughly.

Viruses classified as *Poxviridae* are responsible for many types of infections in lagomorphs (Robinson and Kerr, 2002). These infections differ in many respects from our cases. Myxomatosis, caused by

*Myxoma* virus (*Leporipoxvirus*) infection, occurs in wild and domestic rabbits. The outcome and clinical disease largely depend on the virus strain. Although initial lesions may be present at the same sites (face, mucocutaneous junctions) as in contagious mucocutaneous dermatitis of the mountain hare, the histopathologic findings are very different. Epithelial swelling and intracytoplasmic inclusions may be present; however, the characteristic findings in myxomatosis are proliferation of myxomatous tissue around blood vessels and necrotizing vasculitis. The disease may become generalized with high mortality (Robinson and Kerr, 2002). Myxomatosis is very rare in hares. Only a few mountain hares develop clinical signs after experimental infection, but myxomatosis after natural infection has been reported (Fen-

ner and Ratcliffe, 1965). Rabbit fibroma virus and Hare fibroma virus are also included in the genus *Leporipoxvirus*. The disease caused by these viruses is manifested by multiple firm cutaneous tumor-like growths, most commonly seen in the extremities. Histopathologically, marked irregular epidermal hyperplasia extends down into the dermal tumor mass consisting of a proliferation of fibroblasts. Large eosinophilic inclusions may be observed in the cytoplasm of keratinocytes and to a lesser extent in fibroblasts. The disease is reported in brown hares (Grilli et al., 2003) but, to our knowledge, not in mountain hares. Another poxvirus disease occurring in rabbits is rabbitpox, caused by a strain of vaccinia virus in the genus *Orthopoxvirus*. Typically, there are numerous small cutaneous nodular lesions that are histologically characterized by central necrosis and mononuclear cell infiltration. Inclusion bodies are absent. In addition, this infection may become generalized, with necrotizing lesions in oral mucosa, lungs, liver, adrenal glands, lymph nodes, and testicles (Mare, 1974). The disease has not been reported in wild lagomorphs (Robinson and Kerr, 2002).

A disease similar to what has been described here was reported in Sweden. Eleven cases (4%) of 292 mountain hares and two cases (1%) of 551 brown hares examined during 1986–89 in the National Veterinary Institute of Sweden were diagnosed as “elakartat nosekssem” (malignant nasal eczema). *Treponema*-type bacteria were suggested as the etiologic agent (Mörner, 1992).

Treponemal infection described in wild European brown hares is characterized by a mucocutaneous dermatitis of the lips and prepuce with numerous spirochetes. The infection can be confirmed by special stains and by serology (Lumeij et al., 1994; Lumeij, 1996). In our study, there was no indication of infection with spiral-shaped bacteria, although bacteria, predominantly coccoid bacteria, were a constant finding in ulcerated lesions.

Bacteria of the staphylococcus family mainly reside on mucous membranes and in smaller numbers on the skin surface in a benevolent symbiosis with their host. They may multiply on the skin if the protective skin barrier changes (e.g., after an abrasion or necrosis of the epithelium). The staphylococcal strains colonizing the skin appear to depend on the host species. For example, the *Staphylococcus* sp. typical for human skin is *S. aureus*, in dogs it is *Staphylococcus intermedius*, and in piglets *Staphylococcus hyicus* predominates. According to our study, *S. warneri* appears to be typical for hares. *Staphylococcus warneri* has previously been considered more likely to infect humans than animals (Kloos and Schleifer, 1986).

In our study, we have shown that contagious mucocutaneous dermatitis in mountain hares is caused by a poxvirus. The disease is often complicated by secondary bacterial infection, most commonly by *S. warneri*. We propose this disease be called “mucocutaneous poxviral dermatitis of the mountain hare.”

Our sincere thanks to Pirkko Niemelä from the Department of Basic Veterinary Sciences, The University of Helsinki, for her technical support with processing the samples for the transmission electron microscopy.

#### LITERATURE CITED

- DE KONING, J., R. B. BOSMA, AND J. A. A. HOOGKAMP-KORSTANJE. 1987. Demonstration of spirochetes in patients with Lyme disease with modified silver stain. *Journal of Medical Microbiology* 23: 261–267.
- GRILLI, G., A. PICCIRILLO, A. M. PISONI, M. CERIO, D. GALLAZZI, AND A. LAVAZZA. 2003. Re-emergence of fibromatosis in farmed game hares (*Lepus europaeus*) in Italy. *Veterinary Record* 153: 152–153.
- KLOOS, W. E., AND K. H. SCHLEIFER. 1986. Genus IV. *Staphylococcus*. In *Bergey's manual of systematic bacteriology*, Vol. 2, P. H. A. Sneath, N. S. Mair, M. E. Sharpe, and J. G. Holt (eds.). Williams & Wilkins, Baltimore, Maryland, pp. 1013–1035.
- FENNER, F., AND F. N. RATCLIFFE. 1965. *Myxomatosis*. Cambridge University Press, Cambridge, UK, 365 pp.



- LUMEIJ, J. T. 1996. Syphilis in European brown hares. *In* Proceedings of a symposium on causes and risks of wildlife diseases, Utrecht, Netherlands, 11 October 1996. *Veterinary Quarterly* 18(Suppl 3): S151–S152.
- , J. DE KONING, R. B. BOSMA, J. J. VAN DER SLUIS, AND J. F. P. SCHELLEKENS. 1994. Treponemal infections in hares in the Netherlands. *Journal of Clinical Microbiology* 32: 543–546.
- MARE, C. J. 1974. Viral diseases. *In* The biology of the laboratory rabbit, S. J. Weisbroth (ed.). Academic Press, New York, New York, pp. 237–261.
- MÖRNER, T. 1992. Liv och död bland vilda djur. Sellin & Partner Förlag AB, Stockholm, Sweden, pp. 56–76. [In Swedish.]
- QUINN, P. J., B. K. MARKEY, M. E. CARTER, W. J. C. DONNELLY, AND F. C. LEONARD. 2002. *Veterinary microbiology and microbial disease*. Blackwell Science Ltd, Oxford, UK, 536 pp.
- ROBINSON, A. J., AND P. J. KERR. 2001. Poxvirus infections. *In* Infectious diseases of wild mammals, E. S. Williams and I. K. Barker (eds.). Manson Publishing Ltd, The Veterinary Press, London, UK, pp. 179–201.

*Received for publication 10 April 2003.*