

European Brown Hare Syndrome in Wild European Brown Hares from Greece

Authors: Billinis, Charalambos, Psychas, Vassilios, Tontis, Dimitrios K., Spyrou, Vassiliki, Birtsas, Periklis K., et al.

Source: Journal of Wildlife Diseases, 41(4) : 783-786

Published By: Wildlife Disease Association

URL: <https://doi.org/10.7589/0090-3558-41.4.783>

BioOne Complete (complete.BioOne.org) is a full-text database of 200 subscribed and open-access titles in the biological, ecological, and environmental sciences published by nonprofit societies, associations, museums, institutions, and presses.

Your use of this PDF, the BioOne Complete website, and all posted and associated content indicates your acceptance of BioOne's Terms of Use, available at www.bioone.org/terms-of-use.

Usage of BioOne Complete content is strictly limited to personal, educational, and non - commercial use. Commercial inquiries or rights and permissions requests should be directed to the individual publisher as copyright holder.

BioOne sees sustainable scholarly publishing as an inherently collaborative enterprise connecting authors, nonprofit publishers, academic institutions, research libraries, and research funders in the common goal of maximizing access to critical research.

European Brown Hare Syndrome in Wild European Brown Hares from Greece

Charalambos Billinis,^{1,5} Vassilios Psychas,² Dimitrios K. Tontis,³ Vassiliki Spyrou,¹ Periklis K. Birtsas,⁴ Marina Sofia,¹ Fotios Likotraftitis,³ Olga M. Maslarinou,⁴ and Dimitrios Kanteres³ ¹Laboratory of Microbiology and Parasitology, Faculty of Veterinary Medicine, University of Thessaly, Trikalon 224, GR-43100 Karditsa, Greece; ²Laboratory of Pathology, Faculty of Veterinary Medicine, Aristotle University, GR-54124 Thessaloniki, Greece; ³Laboratory of Pathology, Faculty of Veterinary Medicine, University of Thessaly, Trikalon 224, GR-43100 Karditsa, Greece; ⁴Hunting Federation of Macedonia and Thrace, Evripidou 4, 54635 Thessaloniki, Greece; ⁵Corresponding author (email: billinis@vet.uth.gr)

ABSTRACT: From 1999 to mid-2003, 97 European brown hares (*Lepus europaeus*) found dead throughout Greece were examined by necropsy, histopathology, and reverse-transcription polymerase chain reaction (RT-PCR) for the presence of European brown hare syndrome (EBHS) and EBHS virus (EBHSV), respectively. Hare losses were sporadic, starting in the cold season and lasting for many months (December to May). The most prominent gross lesions were observed in the liver and included swelling and discoloration; congestion and hemorrhages were present mainly in lungs and tracheal mucosa. Necropsy findings were suggestive of EBHS, which was confirmed by histopathology and RT-PCR. This study documents, for the first time, EBHS in Greece.

Key words: European brown hare syndrome, Greece, histopathological findings, PCR.

European brown hare syndrome (EBHS) affects wild and farmed hares of the species *Lepus europaeus* and *Lepus timidus*. The syndrome, a severe necrotic hepatitis, has affected up to 100% of a hare population in which animals usually died within 48–72 hr (Chasey et al., 1992). The disease was first reported during the 1980s and occurred simultaneously in many European countries (Morisse, 1988; Eskens and Volmer, 1989; Henriksen et al., 1989; Marcato et al., 1989; Okerman et al., 1989; Chasey and Duff, 1990; Sostaric et al., 1991; Gavier-Widen and Morner, 1993; Nauwynck et al., 1993; Salmela et al., 1993; Steineck and Nowotny, 1993; Gortazar and de Luco, 1995; Frolich et al., 1996, 2001, 2003; Slamecka et al., 1997). The viral etiology was first demonstrated in 1988 by electron microscopy (Lavazza et al., 1988). Sequencing the viral genome has demonstrated EBHS virus (EBHSV)

shares a similar genomic organization to rabbit hemorrhagic disease virus (RHDV), the cause of rabbit hemorrhagic disease (RHD) but that the two viruses are distinct caliciviruses (Wirblich et al., 1994; Le Gall et al., 1996).

European brown hare syndrome has significant similarities to RHD in its epidemiology, clinical signs, and pathology. Findings in the two diseases are characterized by rapid progression, mild nervous symptoms, severe necrotic hepatitis, and circulatory dysfunction in various organs (Capucci et al., 1991; Duff et al., 1994). Our objective was to determine whether EBHS occurs in Greece where an increased mortality in European brown hare populations has been observed in recent years.

Ninety-seven European brown hares found dead or shot throughout Greece were submitted by hunting federations from 1999 to mid-2003. All hares were adults and in fair or poor body condition. In five hares, postmortem findings were unrecognizable because of advanced putrefaction. Gross lesions were found in 85 hares. Edema, congestion, extensive hemorrhages in the lungs, and severe congestion of the tracheal mucosa were observed. The spleen was enlarged and dark red-black, and the kidneys were congested. In 83, the liver was swollen, discolored, and friable. Tissue samples from liver, lungs, spleen, and kidneys from all except the five decomposed hares were fixed in 10% buffered formalin and routinely processed for histopathologic examination. In addition, samples of liver and spleen from all hares

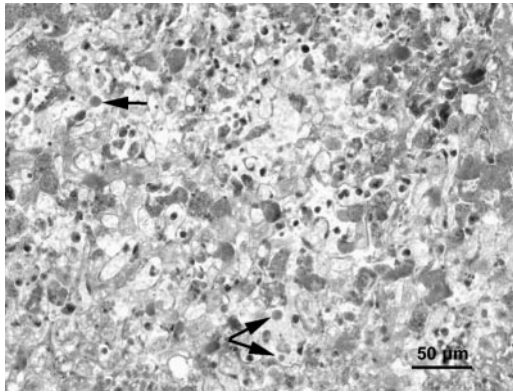


FIGURE 1. Liver. Periportal and midzonal necrosis with a mild inflammatory infiltration of mononuclear cells. Notice the acidophilic bodies (arrows). H&E stain.

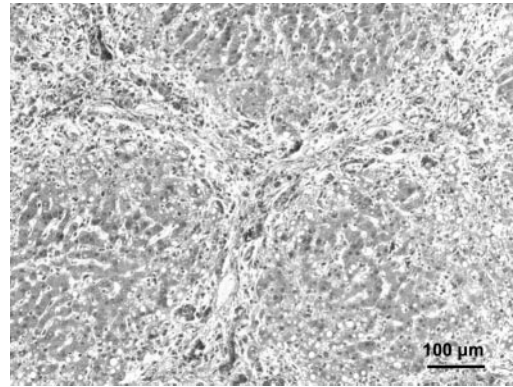


FIGURE 2. Liver. Fibrous tissue infiltrated with lymphocytes has formed in and around the portal tracts and bridged neighbouring portal tracts. Necrosis and degeneration of hepatocytes are seen. H&E stain.

were collected for reverse-transcription polymerase chain reaction (RT-PCR) analysis. The RNA extractions were carried out using a commercial RNA isolation kit (Gentra Systems, Minneapolis, Minnesota, USA). The RNA samples were subjected to reverse transcription, followed by PCR using the primers HEF 5'-CCGTCCAR-CATTTCGTCCTGTCAC-3' and HEB 5'-CATCACCAGTCCTCCGCACCAC-3', which were designed to amplify a part of the gene encoding the structural polypeptide VP60. The expected size of the RT-PCR product was 265 bp (Ros Bascunana et al., 1997).

Histopathologically, in the 85 hares with gross lesions, interstitial and alveolar hemorrhages and edema were observed in the lungs; and in the spleen, the red-pulp was congested and edematous. In 83, acute hepatic lesions, characterized by variably sized areas of periportal and midzonal hepatocellular necrosis, were the most prominent and consistent histopathologic findings. Acidophilic bodies were occasionally seen around or in the necrotic areas in connection with hepatocyte degeneration and calcium deposits (Fig. 1). Three of the seven hares with no gross lesions had a mild periportal inflammatory reaction, prominent periportal fibroplasia, and bile duct proliferation accompanied by peri-

portal degeneration and necrosis of hepatocytes corresponding to chronic hepatitis (Fig. 2).

European brown hare syndrome virus RNA was detected in liver and spleen specimens from the 83 hares with acute hepatic lesions, the three hares with chronic hepatitis, and in spleen from the two hares with changes limited to the lung and spleen. In our study, EBHSV-positive hares were found most frequently between December and May; this observation also has been described by Poli et al. (1991).

Gross and histopathologic findings in these hares were consistent with EBHS, which was confirmed by RT-PCR. On the basis of the morphology of the liver changes, we recognized the two forms of the disease as described by Gavier-Widen (1994), an acute and a subacute form. Furthermore, we found alterations in the liver of three hares corresponding to the chronic form of the disease (Marcato et al., 1991). Detection of viral RNA in this form of the disease may imply that these animals could play a role in the epidemiology of EBHS by spreading and maintenance of the virus.

In conclusion, we have demonstrated that EBHS exists in Greece and may be one of the causes for increased mortality in the hare population in Greece over the past 6 yr. However, the ecological impact

of EBHS needs to be further evaluated in conjunction with other factors, such as changes in habitat, agricultural techniques, and environmental pollution.

LITERATURE CITED

- CAPUCCI L., M. T. SCICLUNA, AND A. LAVAZZA. 1991. Diagnosis of viral hemorrhagic disease of rabbits and the European brown hare syndrome. *Revue Scientifique et Technique. Office International des Epizooties* 10: 347–370.
- CHASEY D., AND P. DUFF. 1990. European brown hare syndrome and associated virus particles in the UK. *Veterinary Record* 126: 623–624.
- , M. LUCAS, D. WESTCOTT, AND M. WILLIAMS. 1992. European brown hare syndrome in the U.K.: A calicivirus related to but distinct from that of viral haemorrhagic disease in rabbits. *Archives of Virology* 124: 363–370.
- DUFF J. P., D. CHASEY, R. MUNRO, AND M. WOOLDRIDGE. 1994. European brown hare syndrome in England. *Veterinary Record* 25: 669–673.
- ESKENS U., AND K. VOLMER. 1989. The etiology of liver dystrophy in the field hare (*Lepus europaeus*). *Deutsche Tierärztliche Wochenschrift* 96: 464–466. [In German].
- FROLICH K., G. HAERER, L. BACCIARINI, M. JANOVSKY, M. RUDOLPH, AND M. GIACOMETTI. 2001. European brown hare syndrome in free-ranging European brown and mountain hares from Switzerland. *Journal of Wildlife Diseases* 37: 803–807.
- , H. H. D. MEYER, Z. PIELOWSKI, L. RONSHOLT, S. V. SECK-LANZENDORF, AND M. STOLTE. 1996. European brown hare syndrome in free-ranging hares in Poland. *Journal of Wildlife Diseases* 32: 280–285.
- , O. E. KUJAWSKI, M. RUDOLPH, L. RONSHOLT, AND S. SPECK. 2003. European brown hare syndrome in free-ranging European brown and mountain hares from Argentina. *Journal of Wildlife Diseases* 39: 121–124.
- GAVIER-WIDEN D. 1994. Morphologic and immunohistochemical characterization of the hepatic lesions associated with European brown hare syndrome. *Veterinary Pathology* 31: 327–334.
- , AND T. MORNER. 1993. Descriptive epizootiological study of European brown hare syndrome in Sweden. *Journal of Wildlife Diseases* 29: 15–20.
- GORTAZAR C., AND D. F. DE LUCO. 1995. The hemorrhagic disease of hares. *Trofeo* 295: 30–34. [In Spanish].
- HENRIKSEN P., D. GAVIER, AND F. ELLING. 1989. Acute necrotizing hepatitis in Danish farmed hares. *Veterinary Record* 125: 486–487.
- LAVAZZA A., M. BOLDINI, P. BONI, E. BROCCHI, L. CAPUCCI, P. CORDIOLI, D. GELMETTI, P. F. GUADAGNINI, G. LOMBARDI, C. SACCHI, AND G. VECCHI. 1988. Identificazione al microscopio elettronico in colorazione negativa di particelle morfologicamente riferibili al virus della malattia X (septicemia virale del coniglio) da organi di lepri. *In the annual meeting of diseases of hares and the European brown hare syndrome*, Uppsala, Sweden, 27–30 October.
- LE GALL G., S. HUGUET, P. VENDE, J. F. VAUTHEROT, AND D. RASSCHAERT. 1996. European brown hare syndrome virus: molecular cloning and sequencing of the genome. *Journal of General Virology* 77: 1693–1697.
- MARCATO P. S., C. BENAZZI, M. GALEOTTI, AND L. SALDA DELLA. 1989. Infective necrotic hepatitis of leporids. *Rivista di Conicoltura* 26: 41–50.
- , C. BENAZZI, G. VECCHI, M. GALEOTTI, L. DELLA SALDA, G. SARLI AND P. LUCIDI. 1991. Clinical and pathological features of viral haemorrhagic disease of rabbits and the European brown hare syndrome. *Revue Scientifique et Technique. Office International des Epizooties* 10: 371–392.
- MORISSE J. P. 1988. Haemorrhagic septicemia syndrome in rabbits: First observations in France. *Le Point Vétérinaire* 20: 79–83.
- NAUWYNCK H., P. CALLEBAUT, J. PEETERS, R. DUCATELLE, AND E. UYTTEBROEK. 1993. Susceptibility of hares and rabbits to Belgian isolate of European brown hare syndrome virus. *Journal of Wildlife Diseases* 29: 203–208.
- OKERMAN L., P. VAN DE KERCKHOVE, S. OSAER, L. DEVRIESE, AND E. UYTTEBROEK. 1989. European brown hare syndrome in captive hares (*Lepus capensis*) in Belgium. *Vlaams Diergeneeskundig Tijdschrift* 58: 44–46.
- POLI A., M. NIGRO, D. GALLAZZI, A. SIRONI, A. LAVAZZA, AND D. GELMETTI. 1991. Acute hepatitis in the European brown hare (*Lepus europaeus*) in Italy. *Journal of Wildlife Diseases* 27: 621–629.
- ROS BASCUNANA C., N. NOWOTNY, AND S. BELAK. 1997. Detection and differentiation of rabbit hemorrhagic disease and European brown hare syndrome viruses by amplification of VP60 genomic sequences from fresh and fixed tissue specimens. *Journal of Clinical Microbiology* 35: 2492–2495.
- SALMELA P., K. BELAK, AND D. GAVIER-WIDEN. 1993. The occurrence of European brown hare syndrome in Finland. *Acta Veterinaria Scandinavica* 34: 215–217.
- SLAMECKA J., P. HELL, AND J. RATISLAV. 1997. Brown hare in the Westslovak lowland. *Acta Scientiarum Naturalium Academiae Scientiarum Bohemicae Brno* 31: 1–115.
- SOSTARIC B., Z. LIPEJ, AND R. FUCHS. 1991. The disappearance of free living hares in Croatia: I. European brown hare syndrome. *Veterinarski Arhiv* 61: 133–150.
- STEINECK T. H., AND N. NOWOTNY. 1993. European brown hare syndrome (EBHS) in Österreich:

Epizootiologische Untersuchungen. Tierärztliche Umschau 48: 225–229.
WIRBLICH C., G. MEYERS, V. F. OHLINGER, L. CAPUCCI, U. ESKENS, B. HAAS, AND H. J. THIEL.
1994. European brown hare syndrome virus: Re-

lationship to rabbit hemorrhagic disease virus and other caliciviruses. Journal of Virology 68: 5164–5173.

Received for publication 22 September 2004.