



**WEST NILE VIRUS IN RAPTORS FROM VIRGINIA
DURING 2003: CLINICAL, DIAGNOSTIC, AND
EPIDEMIOLOGIC FINDINGS**

Authors: Joyner, Priscilla H., Kelly, Sean, Shreve, Allison A., Snead, Sarah E., Sleeman, Jonathan M., et al.

Source: Journal of Wildlife Diseases, 42(2) : 335-344

Published By: Wildlife Disease Association

URL: <https://doi.org/10.7589/0090-3558-42.2.335>

BioOne Complete (complete.BioOne.org) is a full-text database of 200 subscribed and open-access titles in the biological, ecological, and environmental sciences published by nonprofit societies, associations, museums, institutions, and presses.

Your use of this PDF, the BioOne Complete website, and all posted and associated content indicates your acceptance of BioOne's Terms of Use, available at www.bioone.org/terms-of-use.

Usage of BioOne Complete content is strictly limited to personal, educational, and non - commercial use. Commercial inquiries or rights and permissions requests should be directed to the individual publisher as copyright holder.

BioOne sees sustainable scholarly publishing as an inherently collaborative enterprise connecting authors, nonprofit publishers, academic institutions, research libraries, and research funders in the common goal of maximizing access to critical research.

WEST NILE VIRUS IN RAPTORS FROM VIRGINIA DURING 2003: CLINICAL, DIAGNOSTIC, AND EPIDEMIOLOGIC FINDINGS

Priscilla H. Joyner,^{1,5} Sean Kelly,² Allison A. Shreve,^{1,3} Sarah E. Snead,¹ Jonathan M. Sleeman,^{1,4} and Denise A. Pettit²

¹ The Wildlife Center of Virginia, PO Box 1557, Waynesboro, Virginia 22980, USA

² Virginia Department of General Services, Division of Consolidated Laboratory Services, 600 North 5th Street, Richmond, Virginia 23219, USA

³ Current address: Wildlife Care Center, 3200 SW Fourth Avenue, Fort Lauderdale, Florida 33315, USA

⁴ Current address: Virginia Department of Game and Inland Fisheries, 4010 West Broad Street, Richmond, Virginia 23230, USA

⁵ Corresponding author (email: phjoyner@wildlifecenter.org)

ABSTRACT: Sixty-one birds of prey admitted to The Wildlife Center of Virginia (WCV; Waynesboro, Virginia, USA) from June to November 2003 were tested for West Nile virus (WNV) infection. Choanal and/or cloacal swabs were obtained and submitted to Virginia's Division of Consolidated Laboratory Services (Richmond, Virginia, USA) for analysis with real-time reverse transcriptase polymerase chain reaction (RT-PCR). Forty birds of prey were positive for WNV by RT-PCR. Five avian families and nine species of raptors were represented, with great horned owls (*Bubo virginianus*) and red-tailed hawks (*Buteo jamaicensis*) most frequently affected. Presenting clinical signs were consistent with previous reports of WNV infection in raptors; however, these differed between species. Of WNV positive birds, nonspecific signs of illness were the most common clinical findings, particularly in red-tailed hawks; signs included dehydration ($n=20$), emaciation ($n=18$), and depression ($n=15$). Neurologic abnormalities were frequently identified, especially in great horned owls, and included head tremors ($n=17$), ataxia ($n=13$), head incoordination ($n=7$), torticollis ($n=3$), nystagmus ($n=3$), and head tilt ($n=3$). Great horned owls exhibited anemia and leukocytosis with heterophilia, eosinophilia, and monocytosis consistent with chronic inflammation. Red-tailed hawks were anemic with a heterophilic leukocytosis and regenerative left shift. The majority of WNV cases occurred during August and September; there was a marked increase in the number of raptors admitted to WCV during these months followed by a marked decrease during October, November, and December. This pattern differed from mean monthly admissions during the previous 10 years and suggests a negative impact on local raptor populations. The effects of WNV on avian populations are largely unknown; however, because of their ecological importance, further investigation of the effects of WNV on raptor populations is warranted.

Key words: *Bubo virginianus*, *Buteo jamaicensis*, epidemiology, great horned owl, hematology, raptors, red-tailed hawk, surveillance, West Nile virus.

INTRODUCTION

Although avian species represent the principal amplifying hosts for West Nile virus (WNV, *Flavivirus*, *Flaviviridae*) (Komar, 2001), disease associated with this infection in birds prior to its introduction into the United States was rarely reported (Steele et al., 2000). West Nile virus was first detected in North America during an outbreak of viral encephalitis in New York in 1999 (Steele et al., 2000). Since this initial detection in the Western Hemisphere, WNV has spread rapidly across the United States, resulting in unprecedented morbidity and mortality of humans and a broad range of

vertebrate species (McLean et al., 2002). North American avian species appear to be particularly susceptible to disease. Over 230 avian species are listed in the Centers for Disease Control and Prevention (CDC) WNV avian mortality database (www.cdc.gov/ncidod/dvbid/westnile/birdspecies.htm); 15% (35/234) of these reported species are native North American raptor species. Several reports (Ludwig et al., 2002; Fitzgerald et al., 2003; Komar et al., 2003; D'Agostino et al., 2004) describe mortality in native avian species due to WNV infection; clinical descriptions include nonspecific signs of illness, neurological abnormalities, and sudden death. In addition, it has been speculated that

WNV has resulted in regional increases in raptor mortality in the United States (Fitzgerald et al., 2003; McLean, 2003). The impact of WNV on avian populations is unknown, yet some have predicted a likely negative effect in the forthcoming years (Anderson et al., 1999).

Surveillance strategies for WNV effectively have utilized reporting and testing of dead birds for early detection of local WNV transmission, as an indicator of human risk for infection, and for mapping the geographic spread and distribution of this virus (CDC, 2003). Corvids, and in particular American crows (*Corvus brachyrhynchos*), are the most sensitive species that have been used in this surveillance; however, raptor species are useful indicators of WNV activity when corvids are not available (Edison et al., 2001). Live bird surveillance, primarily through serologic testing, also has been suggested as a useful tool for early detection and monitoring of WNV through testing of captive sentinels, primarily chickens, and free-living birds (CDC, 2003). Because free-living North American raptor species are susceptible to WNV infection and are routinely submitted for rehabilitation, the testing of these species also may be useful in WNV surveillance efforts.

The Wildlife Center of Virginia (WCV) is a hospital for native Virginia wildlife and receives injured and orphaned wild animals presented by licensed rehabilitators, government organizations, and the public and has participated in the Virginia Department of Health's WNV surveillance program since 2001. The objectives of this study were to document the presence of WNV in raptors in Virginia as detected by reverse transcriptase polymerase chain reaction (RT-PCR) assay, to describe the utility of using RT-PCR for ante-mortem diagnosis, and to describe the clinical presentation of raptors infected with WNV. This paper also describes temporal patterns of WNV infection in raptors from Virginia during 2003 as well as changes in

number and distribution of admissions for various species of raptors during that year.

MATERIALS AND METHODS

All raptors admitted to WCV (38°02'N, 78°55'W) between June and November 2003 were screened for clinical signs suggestive of WNV. Any animals displaying one or more clinical signs including neurologic abnormalities, anorexia, weakness, lethargy, and/or death or exhibiting hematologic parameters indicative of an inflammatory process were tested for WNV; these selection criteria were based on previous reports of WNV infection in raptors (Fitzgerald et al., 2003).

A physical examination was performed on admission, and 0.2 ml of blood was collected from the ulnar (basilic) or jugular vein into a heparinized 1 ml syringe using a 25 g needle within 48 hr of admission. Hematocrit (PCV) was determined by microhematocrit centrifugation, and plasma protein levels were approximated using a refractometer. Within 10 min of obtaining blood, a blood smear was prepared and stained with Diff Quick (Dip Quick Stain Set, Jorgensen Laboratories, Loveland, Colorado, USA). From the stained smear, a leukocyte differential count was obtained by identifying 100 individual white blood cells and the percentage of each cell type calculated. In addition, a manual white blood cell count was performed using the eosinophil Unopette® 5877 system (Becton Dickinson and Company, Franklin Lakes, New Jersey, USA) and a hemocytometer prepared according to the manufacturer's guidelines. Total granulocytes, stained by the Unopette system, were counted on the hemocytometer, and the total leukocyte count was derived indirectly from the number of stained cells in the hemocytometer and the eosinophil and heterophil percentage using a mathematical calculation (Campbell, 1988). The absolute count of each white blood cell type then was determined based on the total leukocyte count and the cell type percentage obtained from the differential count. Hematology results were entered into a computerized spreadsheet program (Microsoft® Excel 2000, Microsoft Corporation, Redmond, Washington, USA), and the mean, range, and standard deviation were calculated for all parameters of each raptor species and compared to International Species Inventory System (ISIS 2002) reference ranges.

Cloacal and/or choanal swabs were obtained from birds using dry dacron polyester fiber sterile swabs (Fisherbrand® Polyester Tipped

Sterile Swabs, Fisher Scientific International, Hampton, New Hampshire, USA). Swabs were placed in 1 ml of BA-1 diluent (1X medium 199 with Hanks' balanced salt solution, 0.05 M Tris Buffer [pH 7.6], 1% bovine serum albumin, 0.35 g of sodium bicarbonate per liter, 100 µg of streptomycin per liter, 1 µg of amphotericin B per ml) and refrigerated for up to 72 hr, then shipped overnight on ice to the laboratory.

Swabs were analyzed at the Virginia's Division of Consolidated Laboratory Services (DCLS). Nucleic acid was extracted from 220 µl of each sample using the QiaAmp Virus BioRobot 9604 Kit (Qiagen, Valencia, California, USA), according to the manufacturer's instructions. All extractions were performed in a preamplification laboratory containing dedicated equipment and staff. Five microliters of nucleic acid extract from each sample was added to 20 µl of reaction mixture from the QuantiTect Probe RT-PCR Kit (Qiagen) for real-time RT-PCR detection on the ABI 7000 Sequence Detection System (Applied Biosystems, Foster City, California, USA). The reaction mixture also contained one of two 5'FAM- and 3'TAMRA-labeled probes with corresponding primers (WN3'NC set and prNS5 set) that previously have been reported to detect WNV RNA (Briese et al., 2000; Lanciotti et al., 2000). All amplification procedures were performed in a dedicated postamplification laboratory. To ensure that positive signals were not the result of amplicon contamination, all samples screening positive were reextracted as described above and analyzed using the remaining primer/probe set. Each extraction included a WNV-positive control (a homogenate consisting of BA-1 diluent and WNV-infected equine neural tissue) and a negative control (BA-1 diluent alone). Extracts from the positive and negative controls from each extraction run also served as PCR positive and negative controls. Using the method described above, >0.1 pfu of WNV could be reproducibly detected.

An electronic database program (Epi Info Version 6.03, Centers for Disease Control and Prevention, Atlanta, Georgia, USA) containing information on all raptors admitted to WCV between 1993 and 2003 was reviewed to identify trends in distribution. Data extracted from the database included raptor species, age, and month of admission and were compiled into a computerized spreadsheet program (Microsoft® Excel 2000). Species identification and age were determined based on plumage pattern (National Geographic Society, 1987). Annual juvenile raptor admissions from 1996 to 2003 for all species and

red-tailed hawks (*Buteo jamaicensis*) and from 1993 to 2003 for great horned owls (*Bubo virginianus*) were calculated for evaluation in trends. The mean monthly number of admissions plus one standard deviation for all raptor species, great horned owls, and red-tailed hawks admitted to WCV between 1993 and 2002 were calculated and compared with monthly admissions during 2003. Finally, the monthly admissions for all raptors, great horned owls, and red-tailed hawks during 2002 and 2003 were compared to the mean number of monthly admissions during the period 1993–2001.

RESULTS

One hundred forty-nine free-ranging raptors were admitted to WCV between June and November 2003. Twelve raptor species belonging to the orders Falconiformes and Strigiformes were presented from 36 counties in the Commonwealth of Virginia; one bird was from out of state. Sixty-one raptors were tested for WNV, and 40 birds (66%) representing nine species (Table 1) tested positive by reverse transcriptase-polymerase chain reaction. Great horned owls and red-tailed hawks were the most common species presented to WCV between June and November 2003; these two species made up the majority (78%) of the WNV-positive cases. Additional raptor submissions during this time that tested positive for WNV included bald eagles (*Haliaeetus leucocephalus*) ($n=2$) and a peregrine falcon (*Falco peregrinus*) ($n=1$); these made up 8% (3/40) of all WNV-positive birds. For 32 birds, only choanal swabs were tested, and 17 (53%) were positive. Of the 29 birds from which both choanal and cloacal swabs were tested, 23 (76%) tested positive. Seventeen of these 23 positive birds tested positive on both choanal and cloacal swabs, four (two great horned owls and two red-tailed hawks) were positive on choanal swabs only, and two red-tailed hawks were positive on cloacal swabs only. The most common clinical findings in WNV-positive raptors were associated with nonspecific signs of

TABLE 1. Species and number of WNV RT-PCR-positive raptors from WCV during 2003.

Species	Scientific name	Number positive	Number tested
Great horned owl	<i>Bubo virginianus</i>	16	22
Red-tailed hawk	<i>Buteo jamaicensis</i>	15	20
Broad wing hawk	<i>Buteo platypterus</i>	2	2
Bald eagle	<i>Haliaeetus leucocephalus</i>	2	2
Sharp-shinned hawk	<i>Accipiter striatus</i>	1	1
Peregrine falcon	<i>Falco peregrinus</i>	1	2
American kestrel	<i>Falco sparverius</i>	1	2
Barn owl	<i>Tyto alba</i>	1	3
Black vulture	<i>Coragyps atratus</i>	1	1
Cooper's hawk	<i>Accipiter cooperii</i>	0	2
Osprey	<i>Pandion haliaetus</i>	0	1
Eastern screech owl	<i>Otus asio</i>	0	1

illness, neurologic abnormalities, and trauma. Marked interspecies variations in clinical presentation were evident, particularly between great horned owls and red-tailed hawks (Table 2). Neurologic abnormalities were the primary clinical findings in 81% of great horned owls (13/16); clinical signs included moderate to severe head tremors, head incoordination, and ataxia. In contrast, nonspecific signs of illness were the primary clinical finding in 93% of red-tailed hawks (14/15) and included emaciation, dehydration, or depression. Although neurologic abnormalities were also identified in 53% of red-tailed hawks (8/15) at presentation, these were mild when present. Three birds, two great horned owls and one red-tailed

hawk, did not display neurologic abnormalities at time of admission but developed them within 2–6 days of hospitalization. Two raptors (one great horned owl and one red-tailed hawk) had a history of neurologic abnormalities prior to admission; however, they did not display neurologic abnormalities during hospitalization.

Hematology performed on 10 great horned owls showed anemia, leukocytosis, heterophilia, eosinophilia, and a monocytosis with occasional left shift (Table 3). Red-tailed hawks ($n=8$) showed a leukocytosis, heterophilia, and monocytosis with left shift (Table 4). Hematocrit (PCV) performed on red-tailed hawks ($n=9$) revealed anemia in all animals.

Raptor admissions during 2003 decreased during April, May, and June, increased during August and September, followed by a decrease from October to December compared to the monthly mean of the previous 10 years. Total raptor admissions from 2002 showed an increase during January, September, and October and a decrease during February and June (Fig. 1). Unfortunately no avian WNV cases from WCV were confirmed in 2002, as the RT-PCR assay was not available to WCV at this time.

During 2003 red-tailed hawk admissions decreased during January, May, and October through December compared to

TABLE 2. Clinical signs of WNV-positive great horned owls and red-tailed hawks presented to WCV during 2003.

Clinical signs	Great horned owl $n=16$	Red-tailed hawk $n=15$
General		
Dehydration	10	10
Emaciation	7	10
Depression	6	8
Neurologic		
Head tremor	11	3
Head incoordination	5	0
Head tilt	0	3
Ataxia	6	3

TABLE 3. Mean, standard deviation (SD), and range of hematologic parameters for WNV-positive great horned owls admitted to WCV during 2003. $n=10$ for all values.

Value	Mean \pm SD	ISIS Mean \pm SD
	Range	Range
Hematocrit (%)	28 \pm 9.2 14–44	41.3 \pm 4.3 30–53
Total plasma proteins (g/l)	3.4 \pm 1.7 0.9–6.5	Not available
White blood cells ($\times 1,000/\mu\text{l}$)	44.81 \pm 30.70 8.20–89.20	15.69 \pm 10.01 2.89–61.50
Heterophils ($\times 1,000/\mu\text{l}$)	26.68 \pm 21.13 3.77–61.55	8.79 \pm 7.15 0.86–44.30
Lymphocytes ($\times 1,000/\mu\text{l}$)	6.12 \pm 5.89 0.74–17.24	4.83 \pm 3.41 0.07–16.60
Monocytes ($\times 1,000/\mu\text{l}$)	6.55 \pm 5.57 0–16.80	0.90 \pm 1.10 0.07–5.00
Eosinophils ($\times 1,000/\mu\text{l}$)	3.57 \pm 2.10 0.23–9.48	1.67 \pm 2.16 0.06–9.84
Basophils ($\times 1,000/\mu\text{l}$)	0.43 \pm 0.27 0–1.30	Not available
Band cells ($\times 1,000/\mu\text{l}$)	2.33 \pm 2.10 0–5.35	Not available

the monthly mean of the previous 10 years. Red-tailed hawk admissions increased in March, July, August, and September compared to the monthly mean of the previous 10 years. In 2002

a similar change in monthly admissions was noted for the months of March, July, September, and December (Fig. 2). A decrease in great horned owl admissions during January, April, and June was

TABLE 4. Mean, standard deviation (SD), and range of hematologic parameters for WNV-positive red-tailed hawks admitted to WCV during 2003.

Value	n	Mean \pm SD	ISIS Mean \pm SD
		Range	Range
Hematocrit (%)	9	23 \pm 5.4 16–33	42.4 \pm 5.9 28–70
Total plasma proteins (g/dl)	9	2.0 \pm 1.2 0.6–4.0	Not available
White blood cells ($\times 1,000/\mu\text{l}$)	8	29.59 \pm 17.60 7.80–64.10	12.95 \pm 5.85 3.10–29.10
Heterophils ($\times 1,000/\mu\text{l}$)	8	16.80 \pm 12.06 3.59–39.74	6.11 \pm 3.50 1.53–21.20
Lymphocytes ($\times 1,000/\mu\text{l}$)	8	5.60 \pm 4.44 0.31–11.79	3.94 \pm 2.96 0.14–16.40
Monocytes ($\times 1,000/\mu\text{l}$)	8	1.83 \pm 1.47 0.16–4.49	0.91 \pm 0.77 0.03–3.32
Eosinophils ($\times 1,000/\mu\text{l}$)	8	2.56 \pm 2.16 0.16–7.16	1.96 \pm 1.51 0.05–9.61
Basophils ($\times 1,000/\mu\text{l}$)	8	0.64 \pm 0.47 0–1.28	Not available
Band cells ($\times 1,000/\mu\text{l}$)	8	3.29 \pm 2.14 0–6.41	Not available

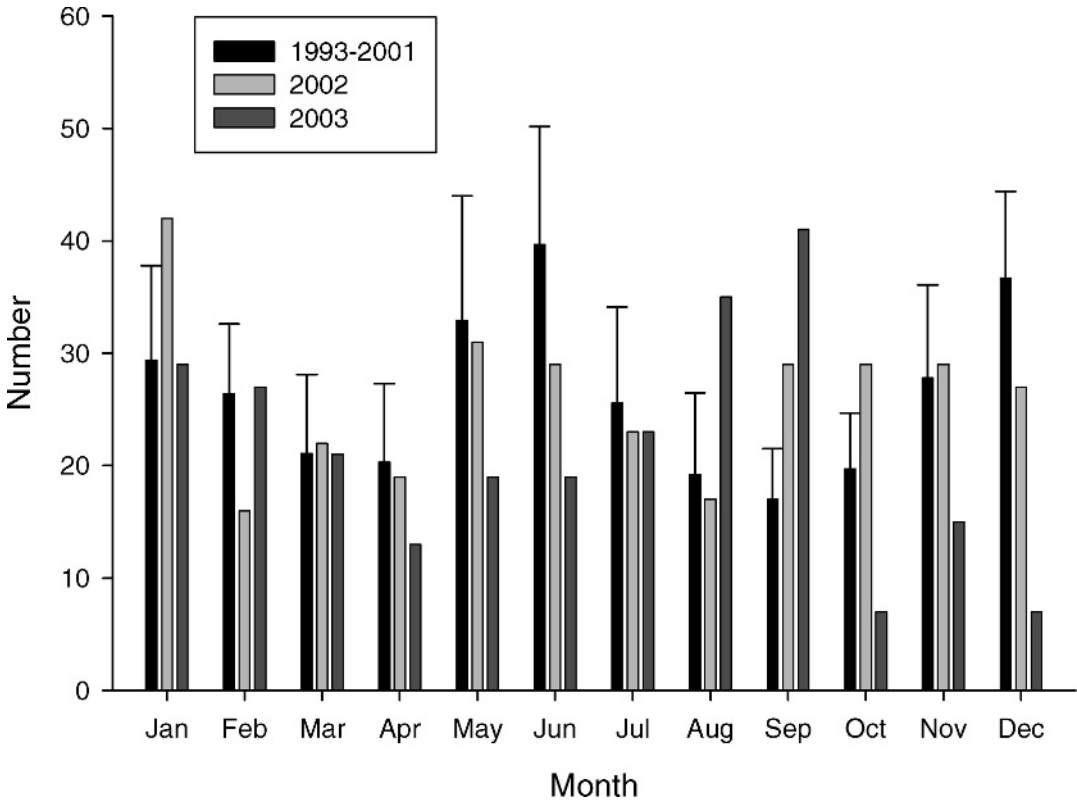


FIGURE 1. Comparison of the monthly admissions of raptors admitted to WCV during 2002 and 2003 and the mean ± 1 standard deviation monthly admissions for raptors from 1993 to 2001.

followed by an increase in admissions from July through September 2003 compared with the monthly mean of the previous 10 years. During 2002 similar changes were noted from June through September (Fig. 3). Additional changes in the monthly admissions for great horned owls were observed, including a marked increase in admissions from October through December.

There was a decrease in the total number of juvenile raptors received throughout 2003 ($n=31$) and 2002 ($n=45$) compared to the mean of the previous seven and six years, respectively (59.6 ± 11.8 ; 62 ± 10.8). Similarly, there was a marked decrease in the number of juvenile great horned owl admissions during 2003 ($n=2$) and 2002 ($n=1$) in comparison with the average annual immature great horned owl admissions from

1993 to 2001 (8.9 ± 2.6). Historically, juvenile red-tailed hawks rarely are presented to WCV; therefore, assessment of trends was not possible (data not shown).

DISCUSSION

Descriptions of clinical disease in WNV-infected free-ranging raptors have been limited, possibly because of a small number of live specimens available for examination. No clinical signs are considered pathognomonic for avian WNV (Ludwig et al., 2002); instead, clinical signs are often nonspecific, or birds may frequently be found dead with no prior clinical signs. In this study interspecies differences in clinical presentation were apparent, particularly between great horned owls and red-tailed hawks. Neurologic abnormalities were the predomi-

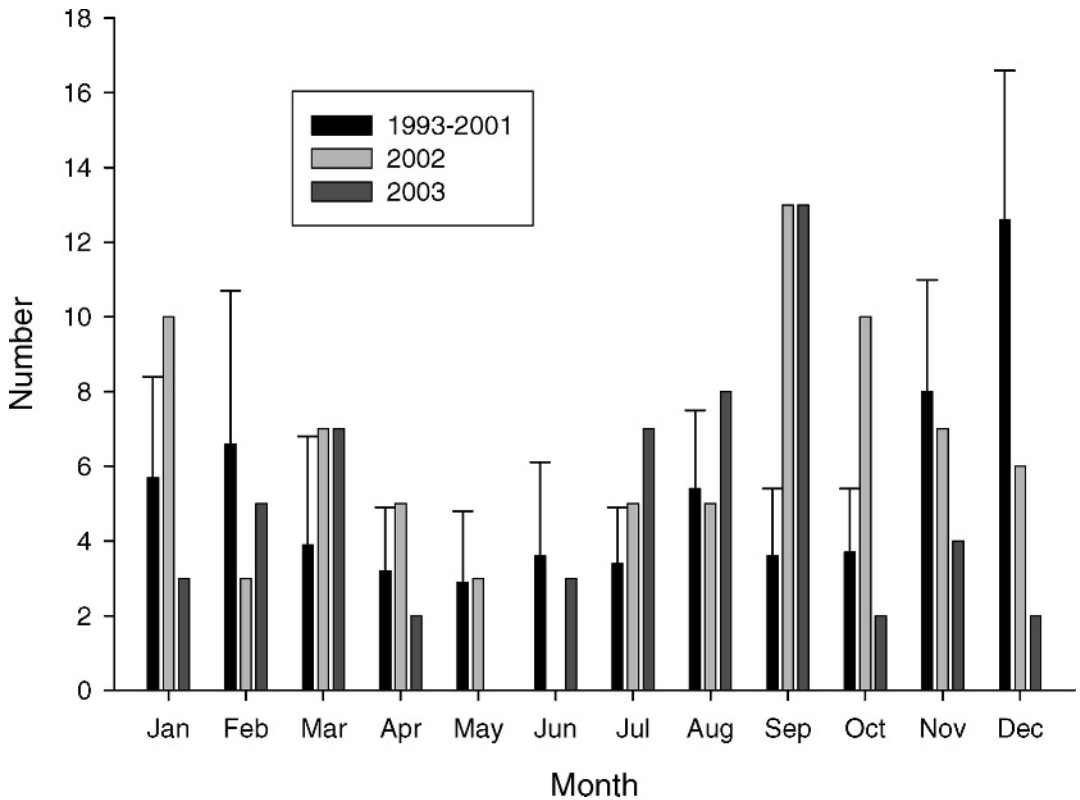


FIGURE 2. Comparison of the monthly admissions of red-tailed hawks admitted to WCV during 2002 and 2003 and the mean +1 standard deviation monthly admissions for red-tailed hawks from 1993 to 2001.

nant clinical sign in great horned owls; this often was accompanied by generalized illness. While neurologic abnormalities were present in red-tailed hawks, these signs were subtle, and general signs of illness including dehydration, emaciation, and depression were more prominent. The clinical presentation of great horned owls is consistent with one previous report of WNV infection in owls (Fitzgerald et al., 2003). However, this is the first clinical description of WNV in red-tailed hawks.

Animals presenting with clinical signs consistent with WNV in combination with a hemogram indicative of an inflammatory process were tested for WNV. The animals tested did not represent a random sampling of total raptor admissions to WCV; selection criteria may have allowed for missed diagnosis of WNV in raptors with unusual clinical presentation. However,

generalized illness and neurological abnormalities were the primary clinical signs identified from WNV positive raptors in this study, which is consistent with previous reports in captive and free-ranging raptors (D'Agostino et al., 2004; Fitzgerald et al., 2004).

Hematologic analysis of ill birds may aid in disease diagnosis, yet hematologic parameters of WNV-infected birds are deficient in the literature. In humans there are no hematology results specific for WNV infection; however, anemia, leukocytosis, and lymphopenia have been reported (Huhn et al., 2003). Similarly, anemia and leukocytosis were common in WNV-positive birds in this study, but lymphopenia was found infrequently.

Hemogram results varied somewhat between WNV-positive great horned owls and red-tailed hawks in this study. Great

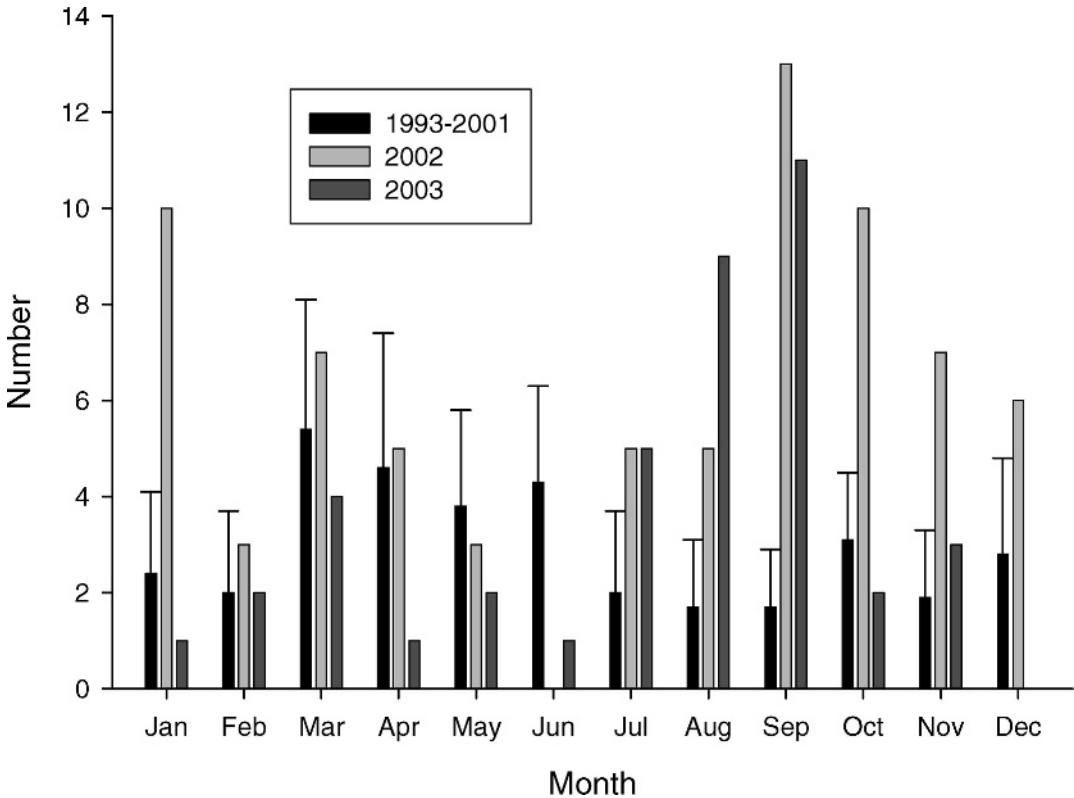


FIGURE 3. Comparison of the monthly admissions of great horned owls admitted to WCV during 2002 and 2003 and the mean +1 standard deviation monthly admissions for great horned owls from 1993 to 2001.

horned owls typically had a heterophilic, monocytic leukocytosis. In birds, leukocytosis and heterophilia can be induced by stress, corticosteroid administration, and inflammatory disease (Altman et al., 1997); however, monocytosis is less likely to be stress induced (Fudge and Joseph, 2000) and characteristic of a chronic inflammatory response (Altman et al., 1997). In the avian patient, causes of monocytic leukocytosis include chlamydia, mycobacteriosis, aspergillosis, granulomatous disease, and bacterial infections (Altman et al., 1997). Red-tailed hawks showed a heterophilic leukocytosis with a regenerative left shift and marked anemia, indicating an acute inflammatory reaction (Fudge and Joseph, 2000). Immature heterophils are uncommon in the avian patient but may appear in the early stages of diseases, including bacterial septicemia, acute chla-

mydophilia, avian tuberculosis, and systemic fungal infections (Fudge and Joseph, 2000). Unfortunately, post-mortem examination of birds was beyond the scope of this study; therefore, concurrent disease could not be ruled out. However, we believe that WNV should be considered in great horned owls and red-tailed hawks that present with an abnormal hemogram characterized by moderate to severe anemia and leukocytosis.

Antemortem diagnosis of WNV is often difficult, and infected birds may die with no premonitory clinical signs. When clinical signs are present, birds are frequently too ill to survive very long or may be euthanized because of severe clinical disease and poor prognosis. A variety of bird species including passerines, corvids, and gulls experimentally infected with WNV usually died within 24 hr after

development of clinical signs (Komar et al., 2003). Reverse-transcriptase polymerase chain reaction of cloacal and choanal swabs has been used for detection of WNV in experimental birds (Komar et al., 2003), captive birds (D'Agostino and Isaza, 2004), and crow carcasses (Komar et al., 2002). However, limited reports on antemortem diagnosis of WNV in free-living birds (Clark et al., 2004), and in particular raptors, are present in the literature. In this study choanal and cloacal swabs for WNV RT-PCR provided a reliable antemortem diagnosis of current infection in field samples and is consistent with the findings of Komar et al. (2002). This is the first report of antemortem diagnosis of WNV infection using real-time RT-PCR on choanal and cloacal swabs in free-ranging wild raptors; with PCR results available in as little as 48 hr, antemortem diagnosis was feasible and practical. Based on results, testing of both choanal and cloacal swabs is recommended.

The impact of WNV infection on raptor populations is unknown. Although wild bird surveillance of WNV first detected infection in wild crows in Virginia in 2000, infection was not established in this state until 2002 (<http://westnilemaps.usgs.gov/>). Compared to previous years, there were an increased number of raptors admitted to WCV during August and September followed by a decrease in admissions from October to December 2003. This is consistent with the spread of avian WNV into Virginia (D. N. Gaines, Virginia Department of Health, personal communication). Although these apparent seasonal changes cannot be regarded as proof of a WNV impact, the change in the trend of monthly distribution of raptors admitted to WCV, as well as the decrease in annual immature raptor admissions (especially great horned owls), may indicate declines in local populations. While environmental factors may be responsible for potential population decline, the most plausible hypothesis is that WNV is having a negative impact on local raptor popula-

tions. Also of great concern is the conservation of certain avian species, which may be affected by WNV (McLean, 2003). In this study two bald eagles were identified as WNV positive by RT-PCR; they were euthanized because of poor prognosis for recovery. In addition, one adult and four juvenile peregrine falcons were positive for WNV detected by RT-PCR, including three juveniles that were submitted directly to DCLS by Virginia Department of Game and Inland Fisheries (data not presented). These falcons were part of the VDGIF Peregrine Falcon Restoration Project Falcon Trak (<http://www.dgif.virginia.gov/wildlife/falcontrak/index.html>).

In summary, WNV is a recently introduced emerging infectious and zoonotic disease in North America, known to cause morbidity and mortality in humans and other vertebrate species (Ludwig et al., 2002). West Nile virus infection should be considered in raptors that are presented for nonspecific signs of illness, with or without neurological abnormalities. Hematology of ill birds showing nonspecific or neurological clinical signs may provide diagnostic support when WNV infection is suspected. Early detection of clinical cases with accurate and rapid diagnosis was achieved using RT-PCR on choanal and cloacal swabs and will aid in monitoring the spread of WNV and detection of the virus in new species. Studies are needed urgently to determine if submission trends reported in this study are indicative of more widespread WNV-related raptor population declines.

ACKNOWLEDGMENTS

We thank D. N. Gaines and S. R. Jenkins of the Virginia Department of Health for their assistance. In addition, we thank the Virginia Department of Game and Inland Fisheries for their cooperation and the staff of The Wildlife Center of Virginia.

LITERATURE CITED

ALTMAN, R. B., S. L. CLUBB, G. M. DORRESTEIN, AND K. QUESENBERRY. 1997. Avian medicine and

- surgery. W. B. Saunders Company, Philadelphia, Pennsylvania, 1070 pp.
- ANDERSON, J. F., T. G. ANDREADIS, C. R. VOSSBRINCK, S. TIRRELL, E. M. WAKEM, R. A. FRENCH, A. E. GARMENDIA, AND H. J. KRUNINGEN. 1999. Isolation of West Nile virus from mosquitoes, crows, and a Cooper's hawk in Connecticut. *Science* 286: 2331–2333.
- BRIESE, T., W. G. GLASS, AND W. I. LIPKIN. 2000. Detection of West Nile virus sequences in cerebrospinal fluid. *The Lancet* 355: 1614–1615.
- CAMPBELL, T. W. 1988. Avian hematology and cytology. Iowa State University Press, Ames, Iowa, 101 pp.
- CENTERS FOR DISEASE CONTROL AND PREVENTION (CDC). 2003. Epidemic/epizootic West Nile virus in the United States: Guidelines for surveillance, prevention and control. 3rd Revision. U.S. Department of Health and Human Services Public Health Service, Centers for Disease Control and Prevention, Fort Collins, Colorado.
- CLARK, L., J. HALL, P. OESTERLE, AND R. MCLEAN. 2004. Detection of West Nile virus from oral swabs of nesting cliff swallows: Potential use as an early surveillance method. 2004 Proceedings AAZV, AAWV, WDA Joint Conference. 220 pp.
- D'AGOSTINO, J. J., AND R. I. ISAZA. 2004. Clinical signs and results of specific diagnostic testing among captive birds housed at zoological institutions and infected with West Nile virus. *Journal of the American Veterinary Medical Association* 10: 1640–1643.
- EDISON, M., L. KRAMER, W. STONE, Y. HAGIWARA, K. SCHMIT, AND THE NEW YORK STATE WEST NILE VIRUS AVIAN SURVEILLANCE TEAM. 2001. Dead bird surveillance as an early warning system for West Nile virus. *Emerging Infectious Diseases* 7: 631–635.
- FITZGERALD, S. D., J. S. PATTERSON, M. KIUPEL, H. A. SIMMONS, S. D. GRIMES, C. F. SARVER, R. M. FULTON, B. A. STEFICEK, T. M. COOLEY, J. P. MASSEY, AND J. G. SIKARSKIE. 2003. Clinical and pathologic features of West Nile virus infection in native North American owls (Family Strigidae). *Avian Diseases* 47: 602–610.
- FUDGE, A. M., AND V. JOSEPH. 2000. Disorders of avian leukocytes. *In* Laboratory medicine avian and exotic pets, A. M. Fudge (ed.). W. B. Saunders Company, Philadelphia, Pennsylvania, pp. 19–27.
- HUHN, G. D., J. J. SEJVAR, S. P. MONTGOMERY, AND M. S. DWORKIN. 2003. West Nile virus in the United States: An update on an emerging infectious disease. *American Family Physician* 68: 653–660.
- INTERNATIONAL SPECIES INVENTORY SYSTEM. 2002. Reference ranges for physiological values in captive wildlife, 2002 Edition. International Species Inventory System, Apple Valley, Minnesota.
- KOMAR, N. 2001. West Nile virus surveillance using sentinel birds. *Annals of New York Academy of Science* 951: 58–73.
- , R. LANCIOTTI, R. BOWEN, S. LANGEVIN, AND M. BUNNING. 2002. Detection of West Nile virus in oral and cloacal swabs collected from bird carcasses. *Emerging Infectious Diseases* 8: 741–742.
- , S. LANGEVIN, S. HINTEN, N. NEMETH, E. EDWARDS, D. HETTLER, B. DAVIS, R. BOWEN, AND M. BUNNING. 2003. Experimental infection of North American birds with the New York 1999 strain of West Nile virus. *Emerging Infectious Diseases* 9: 311–322.
- LANCIOTTI, R. S., A. J. KERST, R. S. NASCI, M. S. GODSEY, C. J. MITCHELL, H. M. SAVAGE, N. KOMAR, N. A. PANELLA, B. C. ALLEN, K. E. VOLPE, B. S. DAVIS, AND J. T. ROEHRIG. 2000. Rapid detection of West Nile virus from human clinical specimens, field-collected mosquitoes, and avian samples by a TaqMan Reverse Transcriptase-PCR assay. *Journal of Clinical Microbiology* 38: 4066–4071.
- LUDWIG, G. V., P. P. CALLE, J. A. MANGIAFICO, B. L. RAPHAEL, D. K. DANNER, J. A. HILE, T. L. CLIPPINGER, J. F. SMITH, R. A. COOK, AND T. MCNAMARA. 2002. An outbreak of West Nile virus in a New York city captive wildlife population. *American Journal of Tropical Medicine and Hygiene* 67: 67–75.
- MCLEAN, R. G. 2003. West Nile Virus: Emerging threat to public health and animal health. *Journal of Veterinary Medical Education* 30: 143–144.
- , S. R. UBICO, D. BOURNE, AND N. KOMAR. 2002. West Nile virus in livestock and wildlife. *Current Topics in Microbiology and Immunology* 267: 271–308.
- NATIONAL GEOGRAPHIC SOCIETY. 1987. Field guide to the birds of North America. National Geographic Society, Washington, D.C., 465 pp.
- STEELE, K. E., M. J. LINN, R. J. SCHOFF, N. KOMAR, T. W. GEISBERT, R. M. MANDUCA, P. P. CALLE, B. L. RAPHAEL, T. L. CLIPPINGER, T. LARSEN, J. SMITH, R. S. LANCIOTTI, N. A. PANELLA, AND T. S. MCNAMARA. 2000. Pathology of fatal West Nile virus infections in native and exotic birds during the 1999 outbreak in New York City, New York. *Veterinary Pathology* 37: 208–224.

Received for publication 16 November 2004.