



## **Johne's Disease in a Free-Ranging White-tailed Deer from Virginia and Subsequent Surveillance for *Mycobacterium avium* subspecies paratuberculosis**

Authors: Sleeman, Jonathan M., Manning, Elizabeth J. B., Rohm, John H., Sims, Jerry P., Sanchez, Susan, et al.

Source: Journal of Wildlife Diseases, 45(1) : 201-206

Published By: Wildlife Disease Association

URL: <https://doi.org/10.7589/0090-3558-45.1.201>

---

BioOne Complete ([complete.BioOne.org](https://complete.BioOne.org)) is a full-text database of 200 subscribed and open-access titles in the biological, ecological, and environmental sciences published by nonprofit societies, associations, museums, institutions, and presses.

Your use of this PDF, the BioOne Complete website, and all posted and associated content indicates your acceptance of BioOne's Terms of Use, available at [www.bioone.org/terms-of-use](https://www.bioone.org/terms-of-use).

Usage of BioOne Complete content is strictly limited to personal, educational, and non - commercial use. Commercial inquiries or rights and permissions requests should be directed to the individual publisher as copyright holder.

---

BioOne sees sustainable scholarly publishing as an inherently collaborative enterprise connecting authors, nonprofit publishers, academic institutions, research libraries, and research funders in the common goal of maximizing access to critical research.

## Johne's Disease in a Free-Ranging White-tailed Deer from Virginia and Subsequent Surveillance for *Mycobacterium avium* subspecies *paratuberculosis*

Jonathan M. Sleeman,<sup>1,5</sup> Elizabeth J. B. Manning,<sup>2</sup> John H. Rohm,<sup>1</sup> Jerry P. Sims,<sup>1</sup> Susan Sanchez,<sup>3</sup> Richard W. Gerhold,<sup>4</sup> and M. Kevin Keel<sup>4</sup> <sup>1</sup>Virginia Department of Game and Inland Fisheries, Richmond, Virginia 23230, USA; <sup>2</sup>Johne's Testing Center, School of Veterinary Medicine, University of Wisconsin, Madison, Wisconsin 53706, USA; <sup>3</sup>Athens Veterinary Diagnostic Laboratory, College of Veterinary Medicine, The University of Georgia, Athens, Georgia 30602, USA; <sup>4</sup>Southeastern Cooperative Wildlife Disease Study, Department of Population Health, College of Veterinary Medicine, The University of Georgia, Athens, Georgia 30602, USA; <sup>5</sup>Corresponding author (email: jonathan.sleeman@dgif.virginia.gov)

**ABSTRACT:** Johne's disease (paratuberculosis) was diagnosed in a 2-yr-old, male, free-ranging white-tailed deer (*Odocoileus virginianus*) from Fauquier County, Virginia, USA, based on histopathology and culture for *Mycobacterium avium* subspecies *paratuberculosis*. Clinical and pathologic findings included emaciation; loss of body fat; chronic diarrhea; severe, chronic, diffuse granulomatous colitis with intrahistiocytic acid-fast bacilli; moderate, chronic granulomatous lymphadenitis with intrahistiocytic acid-fast bacilli; as well as moderate chronic, multifocal, lymphoplasmacytic hepatitis. These findings are consistent with previous reports of Johne's disease in cervids. Subsequent targeted surveillance of 10 emaciated deer with diarrhea, as well as sampling of 72 asymptomatic deer for *M. avium* subsp. *paratuberculosis* using culture of multiple tissue types, as well as serology using an enzyme-linked immunosorbent assay (ELISA) optimized for cervid antibody detection, did not reveal any additional cases of infection in this geographic region. To date, this appears to be an isolated case of Johne's disease in a free-ranging white-tailed deer, and infection with the causative agent for Johne's disease appears to be an infrequent occurrence in deer from this region. The origin of infection was most likely domestic ruminants. This is the first report of clinical Johne's disease in a free-ranging white-tailed deer outside of the Florida Keys, USA. Stressors, such as high deer population density and low selenium levels, may have contributed to the development of clinical disease in this case and warrant further investigation.

**Key words:** Diarrhea, emaciation, Johne's disease, *Mycobacterium avium* subspecies *paratuberculosis*, *Odocoileus virginianus*, paratuberculosis, white-tailed deer.

Johne's disease (paratuberculosis) is an infectious bacterial disease of ruminants of economic importance to a variety of agricultural industries, such as dairies and meat producers (Harris and Barletta, 2001). Caused by *Mycobacterium avium* subspecies *paratuberculosis*, clinical Johne's disease is rarely reported in free-ranging ungulates but has been documented in a few wild species, including Rocky Mountain bighorn sheep (*Ovis canadensis canadensis*), Rocky Mountain goats (*Oreamnos americanus*), tule elk (*Cervus elaphus nannodes*; Jessup and Williams, 1999; Manning et al., 2003), Key deer (*Odocoileus virginianus clavium*; Quist et al., 2002), and free-ranging red deer (*Cervus elaphus hippelaphus*) and fallow deer (*Dama dama*) in Europe (Marco et al., 2002; Glawischnig et al., 2006). The organism has also been isolated from tissues of clinically normal, free-ranging white-tailed deer (*Odocoileus virginianus*) at the time of sample collection (Chiodini and van Kruiningen, 1983; Shulaw et al., 1986; Davidson et al., 2004). However, clinical disease as a result of infection with *M. avium* subsp. *paratuberculosis* in free-ranging white-tailed deer has only been reported for Key deer (Quist et al., 2002) and captive white-tailed deer (Libke and Walton, 1975; Hattel et al., 2004). This case report describes the clinical and pathologic findings of Johne's disease in a white-tailed deer from Virginia, USA,

and the subsequent targeted and active surveillance for infection with *M. avium* subsp. *paratuberculosis* in white-tailed deer from the same geographic region.

In October 2006, following several reports of sick white-tailed deer, a 2-yr-old, male deer from Fauquier County, USA, was reported to the Virginia Department of Game and Inland Fisheries (VDGIF) field staff as being recumbent and reluctant to move. Notable clinical signs included emaciation and abundant dried fecal material around the perineum and hind legs. The deer was euthanized by cervical gunshot, which is an agency-approved method, and a field necropsy was performed. Gross necropsy findings included markedly poor body condition with prominent ribs and vertebrae as well as minimal body fat. The gastrointestinal tract (small intestines, cecum, spiral colon, colon, and rectum) contained copious amounts of brown-green malodorous liquid feces. The serosal surface of the gastrointestinal tract was erythematous with congested and tortuous blood vessels. Additionally, areas of petechial hemorrhage were present on the mucosal surface of various sections of the intestinal tract. The mesenteric lymph nodes were markedly enlarged, and the liver contained several small, white foci within the parenchyma. Representative samples of gastrointestinal tract, lung, heart, mesenteric lymph nodes, spleen, liver, pancreas, kidney, adrenal gland, and skin were collected and placed in 10% buffered neutral formalin. Tissue sections were embedded in paraffin, sectioned at 3  $\mu\text{m}$ , and stained with hematoxylin and eosin and Ziehl-Neelsen acid-fast for light microscopy at the Southeastern Cooperative Wildlife Disease Study (SCWDS). In addition, sections of liver tissue were collected, wrapped in aluminum foil, placed in sterile plastic bags (Whirl-Pak<sup>TM</sup>, Fisher Scientific, Suwanee, Georgia, USA), and frozen at  $-20\text{ C}$  until further analysis.

Histopathologically, the colon mucosa

was infiltrated and markedly thickened by a large number of macrophages. These macrophages separated and displaced the intestinal glands and thickened the submucosa, elevating the muscularis mucosa. An acid-fast stain revealed a large number of acid-fast-positive bacilli within the macrophages (Fig. 1). The subcapsular sinuse of one mesenteric lymph node was expanded by a moderate number of epithelial macrophages and smaller numbers of multinucleate giant cells. These macrophages and giant cells extended into the medullary sinuses, variably infiltrated medullary cords and the cortex, and contained intracytoplasmic acid-fast bacilli as seen in the colon. One section of mesentery contained a focal infiltrate of lymphocytes and plasma cells with fewer macrophages. These inflammatory cells surrounded and variably infiltrated large veins and possibly other vessels. In some veins the infiltrates completely disrupted and obliterated the smooth muscle of the tunica media and were associated with significant perivascular fibrosis. The spleen contained a large amount of red blood cells and golden brown material (hemosiderin). The liver contained a moderate number of small, focal, randomly distributed aggregates of lymphocytes, plasma cells, and rarely neutrophils. The surrounding hepatocytes often were binucleated. Consequently, the most relevant histopathologic diagnoses were severe, chronic, diffuse granulomatous colitis with intrahistiocytic acid-fast bacilli; and moderate, chronic granulomatous lymphadenitis with intrahistiocytic acid-fast bacilli. The hepatitis was minimal and acid-fast bacilli were not observed within the lesions.

DNA amplification by polymerase chain reaction (PCR) was performed on paraffin embedded sections of the colon containing acid-fast bacilli. DNA was extracted from five 5- $\mu\text{m}$ -thick paraffin sections using DNeasy<sup>®</sup> Blood and Tissue (Qiagen, Valencia, California, USA). Real-time PCR was carried out with the extracted

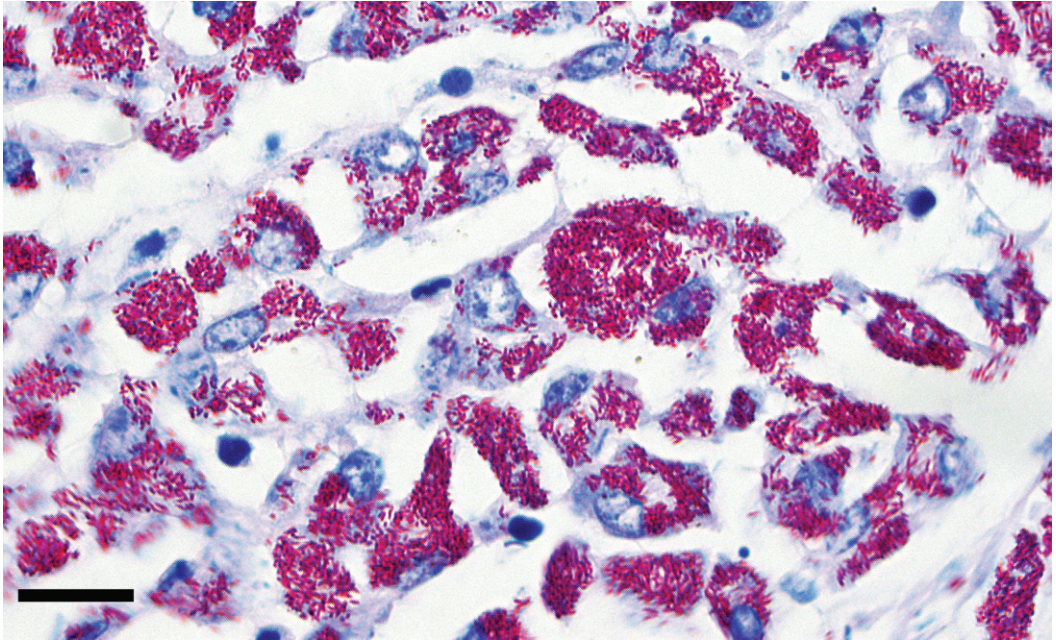


FIGURE 1. Photomicrograph of colon from a white-tailed deer with Johne's disease demonstrating accumulations of epithelioid macrophages in the lamina propria, with myriad intracytoplasmic bacilli consistent with *Mycobacterium avium* subspecies *paratuberculosis* (Acid-fast stain, bar=30  $\mu$ m).

DNA following the TaqMan method of Ravva et al. (2005). DNA was also extracted using the MOBio fecal kit (Solana Beach, California, USA) from feces from this animal. Subsequently, the section of colon was PCR positive for *M. avium* subsp. *paratuberculosis*; however, the feces were PCR negative. Fresh sections of colon were also submitted for routine aerobic, anaerobic, and *Salmonella* culture. *Clostridium perfringens*; type A was subsequently isolated. A presumptive diagnosis of Johne's disease was made based on positive PCR results for *M. avium* subsp. *paratuberculosis* as well as the presence of intrahistiocytic acid-fast bacilli on histopathologic sections of the colon (Fig. 1). A frozen liver sample was submitted to the Johne's Testing Center, (School of Veterinary Medicine, University of Wisconsin, Madison, Wisconsin, USA) for MGIT BACTEC 960 culture for *M. avium* subsp. *paratuberculosis* using methods previously described (Shin et al., 2007). The organism was isolated

from the liver sample, and its identity confirmed by multiplex IS900 DNA PCR and mycobactin-dependent growth.

As a consequence of this diagnosis of Johne's disease, an alert was issued to VDGIF staff and relevant stakeholders to report cases of emaciation and diarrhea in white-tailed deer from this region of Virginia, USA. Field necropsies were performed on deer that fit this case definition, and at necropsy, the distal ileum, spiral colon, colon, ileocecal and mesenteric lymph nodes, liver and rectal feces were collected for *M. avium* subsp. *paratuberculosis* culture, placed in separate sterile plastic bags (Whirl-Pak<sup>TM</sup>, Fisher Scientific, Suwanee, Georgia, USA), and stored chilled. Whole-blood samples were collected for serologic testing by an ELISA optimized at the Johne's Testing Center for cervid antibody detection. The blood was collected from severed thoracic veins using 20 ml syringes, and placed in serum clot tubes. Once clotted, the blood samples were centri-



fuged at  $1,096 \times G$  (Unico Power Spin FX Centrifuge, Dayton, New Jersey, USA); the serum was separated and stored chilled. All samples were shipped by overnight courier to the Johne's Testing Center. In addition, representative tissues from various sections of the gastrointestinal tract, as well as major organs, were collected, placed in 10% buffered neutral formalin, and submitted to SCWDS or the Virginia Department of Agriculture and Consumer Services (VDACS) Animal Health Laboratory (Warrenton, Virginia, USA) for histopathologic evaluation as previously described.

Active surveillance for *M. avium* subsp. *paratuberculosis* infection in deer was also initiated. Seventy-two asymptomatic deer were collected by VDGIF staff using cervical gunshot at seven selected sites in Fauquier County, USA, and neighboring Loudoun County, USA, during January to March 2007. The distal ileum, ileocecal lymph node, and rectal feces were harvested within 1 hr of death. In addition, whole-blood samples were collected and processed as above. All samples were kept refrigerated or chilled and shipped overnight to the Johne's Testing Center for *M. avium* subsp. *paratuberculosis* culture as well as serologic testing. In all, 78 serum samples and 286 tissue and fecal samples were collected.

Ten emaciated deer with diarrhea were subsequently identified during November 2006 to February 2007 in Fauquier and Loudoun counties, Virginia, USA. All cultures of all tissue and fecal samples (total cultures=70) were negative for *M. avium* subsp. *paratuberculosis* after 8 wk. Histopathologic evaluation, including acid-fast staining, did not reveal any pathologic changes consistent with Johne's disease. Consequently, no evidence of Johne's disease was found in these deer. Further diagnostics were pursued, but no definitive diagnoses were made in these cases (VDGIF, unpubl.), but all appeared to be incidental to the case of Johne's disease. Cultures were successfully com-

pleted on all 72 sets of samples from the asymptomatic deer, and all cultures ( $n=216$ ) were negative for *M. avium* subsp. *paratuberculosis* after 8 wk. All deer were negative by ELISA for *M. avium* subsp. *paratuberculosis* antibodies. Unfortunately, no serum from the index case was available for testing.

This report describes the clinical and pathologic findings of Johne's disease in a free-ranging white-tailed deer. The clinical and pathologic findings are consistent with previous reports in Key deer (Quist et al., 2002), experimentally infected deer (Williams et al., 1983), and other wild North American ungulates (Williams, 2001). Although *Clostridium perfringens* Type A was isolated from the colon, the pathogenicity of this species of bacteria is controversial, and the organism has been isolated from the gastrointestinal tract of animals without corresponding clinical signs or lesions (Songer and Uzal, 2005).

This single case of Johne's disease among uniformly test-negative deer from Fauquier and Loudoun counties, USA, indicates that infection with *M. avium* subsp. *paratuberculosis* is an infrequent occurrence in deer from this geographic region. A study that performed multistate surveys of wild white-tailed deer in southeastern United States also revealed a very low prevalence of infection (0.3%; Davidson et al., 2004) and concluded that white-tailed deer do not constitute a broad regional reservoir for this organism. Our results of more local-scale surveillance are consistent with this conclusion. Sample sites in our study were selected based on proximity to investigated cases of emaciation and diarrhea; however, the sampling was mostly opportunistic and nonrandom, and no conclusions concerning the prevalence of infection with *M. avium* subsp. *paratuberculosis* can be made. We were unable to determine whether the deer with Johne's disease was actively shedding the organism, as cultures were not performed on the feces; however, as mentioned, the feces from this deer were

negative by PCR for *M. avium* subsp. *paratuberculosis*. This deer was found in proximity to a cattle farm with known cases of Johne's disease (VDACS, unpubl.), and this is the most likely origin of infection. This is supported by the fact the organism isolated was a strain typically associated with cattle.

Quist et al. (2002) discussed the role of stressors, such as high deer population density, and low nutritional quality of habitat, as risk factors that may enhance transmission of *M. avium* subsp. *paratuberculosis* and development of clinical disease. Based on population reconstruction data, the density of deer in Loudoun and Fauquier counties, USA, is one of the highest in Virginia, USA, with estimates of 15–23 deer/km<sup>2</sup>. This is twice the state average of 10 deer/km<sup>2</sup> (VDGIF, unpubl.). Furthermore, preliminary studies indicate that deer from this region have significantly lower hepatic selenium levels compared with deer from Nottoway County, in southeast Virginia, USA, (VDGIF, unpubl.), a finding that is consistent with the known distribution of selenium-deficient soils (Ihnat, 1989). It is currently unknown whether low selenium levels are associated with increased susceptibility to development of clinical Johne's disease; however, investigation of any risk factors that may have contributed to the development of clinical disease in this case is warranted. Targeted and active surveillance for the presence of *M. avium* subsp. *paratuberculosis* in free-ranging white-tailed deer from this region of Virginia, USA, is ongoing.

We thank the staff of VDGIF; in particular, R. Busch, R. Duncan, R. Ellis, R. Hughes, J. Ferdinandsen, M. Knox, N. Lafon, D. Lovelace, and B. Moyer for assistance with this work. In addition, we thank K. Magura from VDACS Animal Health Laboratory, Warrenton, Virginia, USA, and N. Chenoweth at the Athens Veterinary Diagnostic Laboratory. Financial support was provided by the Federal Aid to Wildlife Restoration Act under Project WE-99,

administered by the Virginia Department of Game and Inland Fisheries, and the Morris Animal Foundation.

#### LITERATURE CITED

- CHIODINI, R. J., AND H. J. VAN KRUNINGEN. 1983. Eastern white-tailed deer as a reservoir of ruminant paratuberculosis. *Journal of the American Veterinary Medical Association* 182: 168–169.
- DAVIDSON, W. R., E. J. B. MANNING, AND V. F. NETTLES. 2004. Culture and serologic survey for *Mycobacterium avium* subsp. *paratuberculosis* among southeastern white-tailed deer (*Odocoileus virginianus*). *Journal of Wildlife Diseases* 40: 301–306.
- GLAWISCHNIG, W., T. STEINECK, AND J. SPERGSER. 2006. Infections caused by *Mycobacterium avium* subspecies *avium*, *hominissuis*, and *paratuberculosis* in free-ranging red deer (*Cervus elaphus hippelaphus*) in Austria, 2001–2004. *Journal of Wildlife Diseases* 42: 724–731.
- HARRIS, N. B., AND R. A. BARLETTA. 2001. *Mycobacterium avium* subsp. *paratuberculosis* in veterinary medicine. *Clinical Microbiology Reviews* 14: 489–512.
- HATTEL, A. L., D. P. SHAW, B. C. LOVE, D. C. WAGNER, T. R. DRAKE, AND J. W. BROOKS. 2004. A retrospective study of mortality in Pennsylvania captive white-tailed deer (*Odocoileus virginianus*): 2000–2003. *Journal of Veterinary Diagnostic Investigation* 16: 515–521.
- IHNAT, M. 1989. Occurrence and distribution of selenium. CRC Press, Boca Raton, Florida, pp. 1–368.
- JESSUP, D. A., AND E. S. WILLIAMS. 1999. Paratuberculosis in free-ranging wildlife in North America. *In Zoo and wild animal medicine current therapy*, 4th Edition, M. E. Fowler and R. E. Miller (eds.). W. B. Saunders, Philadelphia, Pennsylvania, pp. 616–620.
- LIBKE, K. G., AND A. M. WALTON. 1975. Presumptive paratuberculosis in a Virginia white-tailed deer. *Journal of Wildlife Diseases* 11: 552–553.
- MANNING, E. J. B., T. E. KUCERA, N. B. GATES, L. M. WOODS, AND M. FALLON-MCKNIGHT. 2003. Testing for *Mycobacterium avium* subsp. *paratuberculosis* infection in asymptomatic free-ranging tule elk from an infected herd. *Journal of Wildlife Diseases* 39: 323–328.
- MARCO, I., M. RUIZ, R. JUSTE, AND J. M. LAVIN. 2002. Paratuberculosis in free-ranging fallow deer in Spain. *Journal of Wildlife Diseases* 38: 629–632.
- QUIST, C. F., V. F. NETTLES, E. J. B. MANNING, D. G. HALL, J. K. GAYDOS, T. J. WILMERS, AND R. R. ROPER. 2002. Paratuberculosis in Key deer (*Odocoileus virginianus clavium*). *Journal of Wildlife Diseases* 38: 729–737.
- RAVVA, S. V., AND L. H. STANKER. 2005. Real-time

- quantitative PCR detection of *Mycobacterium avium* subsp. *paratuberculosis* and differentiation from other mycobacteria using SYBR Green and TaqMan assays. *Journal of Microbiological Methods* 63: 305–17.
- SHIN, S. J., J. H. HAN, E. J. B. MANNING, AND M. T. COLLINS. 2007. Rapid and reliable method of quantification of *Mycobacterium paratuberculosis* by use of the BACTEC MGIT 960 system. *Journal of Clinical Microbiology* 45: 1941–1948.
- SHULAW, W. P., J. C. GORDON, S. BECH-NIELSEN, C. I. PRETZMAN, AND G. F. HOFFSIS. 1986. Evidence of paratuberculosis in Ohio's white tailed deer, as determined by an enzyme-linked immunosorbent assay. *American Journal of Veterinary Research* 47: 2539–2542.
- SONGER, J. G., AND F. A. UZAL. 2005. Clostridial enteric infections in pigs. *Journal of Veterinary Diagnostic Investigation* 17: 528–536.
- WILLIAMS, E. S. 2001. Paratuberculosis and other mycobacterial diseases. In *Infectious diseases of wild mammals*, 3rd Edition, E. S. Williams and I. K. Barker (eds.). Iowa State University Press, Ames, Iowa, pp. 361–371.
- , S. P. SYNDER, AND K. L. MARTIN. 1983. Pathology of spontaneous and experimental infection of North American wild ruminants with *Mycobacterium paratuberculosis*. *Veterinary Pathology* 20: 274–291.

*Received for publication 10 February 2007.*