

Dermoid Cysts in Caribou

Authors: Wobeser, G., Bollinger, T., Neimanis, A., and Beckmen, K. B.

Source: Journal of Wildlife Diseases, 45(2) : 505-507

Published By: Wildlife Disease Association

URL: <https://doi.org/10.7589/0090-3558-45.2.505>

BioOne Complete (complete.BioOne.org) is a full-text database of 200 subscribed and open-access titles in the biological, ecological, and environmental sciences published by nonprofit societies, associations, museums, institutions, and presses.

Your use of this PDF, the BioOne Complete website, and all posted and associated content indicates your acceptance of BioOne's Terms of Use, available at www.bioone.org/terms-of-use.

Usage of BioOne Complete content is strictly limited to personal, educational, and non - commercial use. Commercial inquiries or rights and permissions requests should be directed to the individual publisher as copyright holder.

BioOne sees sustainable scholarly publishing as an inherently collaborative enterprise connecting authors, nonprofit publishers, academic institutions, research libraries, and research funders in the common goal of maximizing access to critical research.

Dermoid Cysts in Caribou

G. Wobeser,^{1,3} T. Bollinger,¹ A. Neimanis,¹ and K. B. Beckmen² ¹ Canadian Cooperative Wildlife Health Centre, Department of Veterinary Pathology, Western College of Veterinary Medicine, University of Saskatchewan, Saskatoon, Saskatchewan S7N 5B4, Canada; ² Division of Wildlife Conservation, Alaska Department of Fish and Game, 1300 College Road, Fairbanks, Alaska 99701-1599, USA; ³ Corresponding author (email: gary.wobeser@usask.ca)

ABSTRACT: Subcutaneous dermoid cysts were identified in eight wild caribou (*Rangifer tarandus*) from widely dispersed locations in northern Canada and in one wild caribou from Alaska. The dermoid cysts from Canadian caribou were found among 557 diagnostic specimens that had been detected by hunters and submitted by resource officers and biologists between 1 January 1966 and 15 May 2007. All of the cysts were located in the cervical region, and five of nine cysts were found in the throat area. All of the animals for which the age was known were adult; males and females were equally represented. Dermoid cysts were not diagnosed in any of 1,108 white-tailed deer (*Odocoileus virginianus*), 293 mule deer (*Odocoileus hemionus*), 174 elk (*Cervus elaphus*), or 529 moose (*Alces alces*) examined during the same period at the Canadian laboratory.

Key words: Anomaly, caribou, dermoid cyst, *Rangifer tarandus*, skin.

A dermoid cyst is defined as a “congenital dermal and/or subcutaneous cyst lined by epidermis with mature dermal and appendageal structures in the cyst wall,” with hair and keratin in the cyst lumen (Goldschmidt et al., 1998). Dermoid cysts have been described in many species and are usually considered to result from entrapment of epidermis and associated adnexal structures in the dermis during embryonic development (Goldschmidt and Schofer, 1998). In humans, dermoid cysts are found most commonly on the head and neck (Cohen, 1999). Dermoid cysts are not considered to be harmful in animals, but must be differentiated from other more-significant subcutaneous masses including abscesses, granulomas, and neoplasms (Fitzgerald, 1998), as well as from follicular and epidermal cysts. During a review of case files for another

purpose, we noted an unusual frequency of occurrence of dermoid cysts in diagnostic specimens from wild caribou (*Rangifer tarandus*). This prompted a search for records of dermoid cysts in wild cervids. The files searched were those of the Department of Veterinary Pathology, Western College of Veterinary Medicine, Saskatoon, Saskatchewan, Canada from 1 January 1966 to 31 December 1991; and those of Western/Northern Region of the Canadian Cooperative Wildlife Health Centre (CCWHC; Saskatoon, Saskatchewan, Canada) from 1 January 1992 to 15 May 2007.

Dermoid cysts were diagnosed in eight of 557 caribou specimens (1%) from widely dispersed sites in northern Canada during this period (Table 1). Almost all of the specimens consisted of tissues submitted in a frozen state by biologists or conservation officers after an abnormality had been detected by a hunter. Animal F was a woodland caribou (*Rangifer tarandus caribou*); the other animals were barren-ground caribou (*R. t. groenlandicus*). A dermoid cyst from a barren-ground caribou in Alaska was located through consultation with neighboring jurisdictions.

All of the animals for which age had been recorded were adult; males and females were equally represented. The dermoid cyst in all nine caribou was located under the skin of the neck; in five, the submitter referred specifically to the throat area. Animal E was described to have had similar masses at other unspecified sites, but only the mass from the throat was submitted. The masses were

TABLE 1. Geographic origin, age and sex of animals, and anatomical location of dermoid cysts identified in wild caribou from northern Canada and Alaska.

Specimen	Year	Origin	Sex	Age	Location	Size (cm)
A	1987	Pelly Bay, NU ^a 68°53'N, 90°05'W	U ^b	U	Throat	6×2.5
B	1988	Holman, NT ^c 70°44'N, 114°45'W	F	A ^d	Throat	4×2×2.5
C	1990	Norman Wells, NT 65°17'N, 126°50'W	M	A	Ventral neck	6×4
D	1992	Little Corner Cliff, NU 64°10'N, 82°51'W	F	A	Throat	6×3×2
E	1997	Hope Lake, NT 69°16'N, 135°17'W	F	A	Lateral neck	6×3
F	2001	Ross River, YT ^e 61°45'N, 131°45'W	F	U	Throat	4.5×3×1.5
G	2004	Yellowknife, NT 64°48'N, 112°03'W	M	A	Throat	6.5×2
H	2006	Anaktuvuk Pass, AK ^f 68°14'N, 151°74'W	M	A	Neck	10×6
I	2007	Fort McPherson, NT 67°26'N, 134°53'W	M	A	Neck	5×10

^a NU = Nunavut.

^b U = Unknown.

^c NT = Northwest Territories.

^d A = Adult.

^e YT = Yukon.

^f AK = Alaska.

generally ovoid and, on section, all were filled with fine hair and waxy fluid (Fig. 1). Microscopically, the wall of the cysts consisted of stratified squamous epithelium overlying a fibrous dermis containing hair follicles and sebaceous glands. Because the cysts had been dissected from

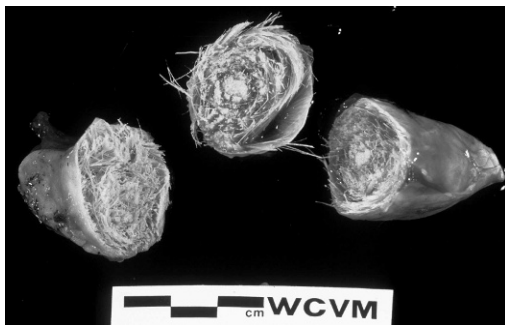


FIGURE 1. Gross appearance of a dermoid cyst removed from a subcutaneous location on the neck of a wild barren-ground caribou (animal A, Table 1). The cyst has been sectioned to show the content of fine hair.

adjacent tissues prior to submission, it is not known how many occurred on the ventral midline.

Structures resembling dermoid cysts have been reported previously in caribou. Banfield (1958) described a subcutaneous dermoid measuring 5.8×2.5 cm and filled with tightly packed hair found in a woodland caribou killed near Schefferville, Quebec (54°48'N, 66°50'W) in 1956. It is not known if this specimen was examined microscopically. Banfield made reference to a much-earlier report of a similar cyst from the lower part of the neck of a woodland caribou from an unidentified site in Canada (Richardson, 1829). Richardson did not see the cyst but quoted from an earlier report regarding a male caribou, likely from near York Factory (57°00'N, 92°18'W, now in the province of Manitoba), that had “a peculiar bag or cist in the lower part of the neck about the bigness of a crown-piece

and filled with fine flaxen hair neatly coiled round to the thickness of an inch" (Richardson, 1829). This cyst was described to have an opening through the skin. Fitzgerald (1998) described the gross and microscopic features of a dermoid cyst beneath the skin on the ventral midline of the neck of an adult female caribou, presumably from a zoologic collection.

We cannot quantify how commonly dermoid cysts occur in wild caribou because we do not know the number of caribou examined by hunters or the proportion of abnormalities, seen by hunters, that were submitted to the laboratory. Dermoid cyst was not diagnosed in any of 1,108 white-tailed deer, (*Odocoileus virginianus*), 293 mule deer (*Odocoileus hemionus*), 529 moose (*Alces alces*) or 174 elk (*Cervus elaphus*) specimens from Canada examined in our laboratory during the same time period. A 2.5-cm diameter infundibular cyst (epidermal cyst) filled with keratin was diagnosed under the skin of the neck of an adult mule deer. An infundibular cyst is defined as "A simple cyst lined by stratified squamous epithelium. All four layers of the normal epidermis or infundibulum, including a granular cell layer, are present" (Goldschmidt et al., 1998). It is not possible to directly compare the relative frequency of occurrence of dermoids in different cervid species because

specimens of different species were submitted to the laboratory under different circumstances; however, it appears that this lesion occurs more commonly in caribou than in the other cervid species examined.

We thank the field staff of various agencies for collection and submission of the specimens and information about the animals involved.

LITERATURE CITED

- BANFIELD, A. W. F. 1958. Dermoid cysts a basis of Indian legends. *Journal of Mammalogy* 39: 451–452.
- COHEN, B. A. 1999. *Pediatric dermatology*, 2nd Edition. Mosby, London, 232 pp.
- FITZGERALD, S. D. 1998. Clinical challenge. *Journal of Zoo and Wildlife Medicine* 29: 349–351.
- GOLDSCHMIDT, M. H., AND F. S. SCHOFER. 1998. *Skin tumors of the dog and cat*. Butterworth-Heinemann, Oxford, England, 316 pp.
- , R. W. DUNSTAN, A. A. STANNARD, C. VON TSCHRAMER, E. J. WALDER, AND J. A. YAGER. 1998. Histological classification of epithelial and melanocytic tumors of the skin of domestic animals. World Health Organization International histologic classification of tumors of domestic animals, Second Series, Vol. III. Armed Forces Institute of Pathology, Washington, D.C., USA, 788 pp.
- RICHARDSON, J. 1829. *Fauna Boreali-Americana; or the zoology of the northern parts of British America, part first containing the quadrupeds*. John Murray, London, p. 251; 300 pp.

Received for publication 8 June 2007.