



**CANINE DISTEMPER VIRUS–ASSOCIATED
ENCEPHALITIS IN FREE-LIVING LYNX (LYNX
CANADENSIS) AND BOBCATS (LYNX RUFUS) OF
EASTERN CANADA**

Authors: Daoust, Pierre-Yves, McBurney, Scott R., Godson, Dale L.,
van de Bildt, Marco W. G., and Osterhaus, Albert D. M. E.

Source: Journal of Wildlife Diseases, 45(3) : 611-624

Published By: Wildlife Disease Association

URL: <https://doi.org/10.7589/0090-3558-45.3.611>

BioOne Complete (complete.BioOne.org) is a full-text database of 200 subscribed and open-access titles in the biological, ecological, and environmental sciences published by nonprofit societies, associations, museums, institutions, and presses.

Your use of this PDF, the BioOne Complete website, and all posted and associated content indicates your acceptance of BioOne's Terms of Use, available at www.bioone.org/terms-of-use.

Usage of BioOne Complete content is strictly limited to personal, educational, and non - commercial use. Commercial inquiries or rights and permissions requests should be directed to the individual publisher as copyright holder.

BioOne sees sustainable scholarly publishing as an inherently collaborative enterprise connecting authors, nonprofit publishers, academic institutions, research libraries, and research funders in the common goal of maximizing access to critical research.

CANINE DISTEMPER VIRUS–ASSOCIATED ENCEPHALITIS IN FREE-LIVING LYNX (*LYNX CANADENSIS*) AND BOBCATS (*LYNX RUFUS*) OF EASTERN CANADA

Pierre-Yves Daoust,^{1,4} Scott R. McBurney,¹ Dale L. Godson,² Marco W. G. van de Bildt,³ and Albert D. M. E. Osterhaus³

¹ Canadian Cooperative Wildlife Health Centre, Atlantic Veterinary College, University of Prince Edward Island, 550 University Avenue, Charlottetown, PE C1A 4P3, Canada

² Prairie Diagnostic Services, Western College of Veterinary Medicine, University of Saskatchewan, 52 Campus Drive, Saskatoon, SK S7N 5B4, Canada

³ Department of Virology, Erasmus Medical Centre, Dr. Molewaterplein 50, 3000DR Rotterdam, The Netherlands

⁴ Corresponding author (email: daoust@upei.ca)

ABSTRACT: Between 1993 and 1999, encephalitis caused by morbillivirus was diagnosed by immunohistochemistry and histology in six lynx (*Lynx canadensis*) and one bobcat (*Lynx rufus*) in the eastern Canadian provinces of New Brunswick and Nova Scotia. Five of the six cases in lynx occurred within an 11-mo period in 1996–97. A second bobcat with encephalitis caused by unidentified protozoa and a nematode larva also had immunohistochemical evidence of neurologic infection by morbillivirus. The virus was identified as canine distemper virus (CDV) by reverse transcriptase polymerase chain reaction and nucleotide sequencing in four of five animals from which frozen tissue samples were available, and it was isolated in cell culture from one of them. To our knowledge, this is the first report of disease caused by CDV in free-living felids in North America.

Key words: Bobcat, Canada, distemper, lynx, *Lynx canadensis*, *Lynx rufus*, morbillivirus.

INTRODUCTION

The potential for morbillivirus infection to cause severe mortality in new host species, such as seals, cetaceans, and felids, has been recognized in the past two decades (Appel et al., 1994; Roelke-Parker et al., 1996; Kennedy, 1998). To our knowledge, reports of disease caused by morbillivirus infection in feline species in North America so far have been confined to captive exotic animals (Blythe et al., 1983; Gould and Fenner, 1983; Fix et al., 1989; Appel et al., 1994; Wood et al., 1995). The exact source of the virus could not be confirmed in any of these cases. However, an outbreak of this disease that affected large cats in California, USA, in 1992 and 1993 coincided with unusually high mortality from infection with canine distemper virus (CDV) among free-living raccoons (*Procyon lotor*) and skunks (*Mephitis mephitis*) in the area (Appel et al., 1994).

Indigenous species of North American felids include cougar (*Felis concolor*), lynx (*Lynx canadensis*), and bobcat (*Lynx*

rufus). Because of the elusive nature and solitary habits of these animals, little is known about infectious diseases that may affect them and the potential impact of these diseases on their populations. In the eastern Canadian provinces of New Brunswick (NB) and Nova Scotia (NS) (between 43°50'N, 59°40'W and 48°00'N, 68°00'W), cougars are very rare (Stocek, 1995); lynx occur in NB, although almost exclusively in the northwest corner of the province, and in the highland plateau of Cape Breton Island in the northern part of NS (Poole, 2003); and bobcats range throughout both provinces, except for the highland plateau of Cape Breton Island, NS (Parker and Smith, 1983). Populations of bobcats in both provinces are secure, but those of lynx are at risk of extirpation.

In this report, we describe seven cases of encephalitis caused by CDV infection in free-ranging bobcats and lynx from NB and NS that occurred between 1993 and 1999. To our knowledge, this is the first report of disease caused by CDV in free-living felids in North America.

MATERIALS AND METHODS

Source of animals and sample collection

Between 1989 and 2005, carcasses of 14 bobcats and 14 lynx from NB and NS found sick or dead by wardens of national parks, provincial conservation officers, or members of the public were submitted for necropsy to the regional office of the Canadian Cooperative Wildlife Health Centre, at the Atlantic Veterinary College (AVC), University of Prince Edward Island. Live animals were killed by intravenous injection of barbiturates or with a rifle or shotgun. Some carcasses were submitted fresh, whereas others were frozen for variable amounts of time before submission. In one instance, only the animal's head was submitted; a complete necropsy was performed on the 27 other animals. Determination of their relative age, i.e., immature (<1 yr) or adult, was based on combinations of the animal's size, the presence or absence of a pulp cavity within the canine teeth (Parker and Smith, 1983), presence or absence of a physal growth plate in the proximal region of the femurs, and gross appearance of the reproductive tract. Samples of major organs from 25 of the 27 whole carcasses and samples of brain from the animal with only the head submitted were fixed in 10% neutral buffered formalin and embedded in paraffin blocks. Organs sampled (and number of carcasses sampled, respectively) included: brain (cerebrum, brain stem, cerebellum; 24), spinal cord (8), heart (22), lung (23), stomach (12), liver (21), pancreas (9), kidney (22), spleen (14), lymph nodes (8), and adrenal (15).

Serology

Serum samples were taken from two lynx prior to euthanasia. In addition, serum samples were collected during spring 2000 from four adult free-living lynx from Cape Breton Island, NS. These four lynx had been found alive but very thin and abnormally docile and were captured and held in captivity for several months prior to their release back into the wild. A serum neutralization (SN) test for antibodies against the Onderstepoort strain of CDV adapted to Vero cells (considered positive at dilutions of 1:32 and above) was performed on these samples (Appel and Robson, 1973).

Light microscopy and immunohistochemistry

Sections, 5- μ m-thick, were cut from the paraffin blocks, processed for routine histopathologic examination, and stained with

hematoxylin and eosin or by immunohistochemistry (IHC). Immunohistochemical detection of morbillivirus, rabies virus, *Toxoplasma gondii*, *Sarcocystis*, and *Neospora* antigens was conducted using an avidin-biotin complex technique adapted for an automated slide stainer (CodeOn Histomatic Stainer, Fisher Scientific, Edmonton, Canada) as previously described (Haines and Chelack, 1991). Following protease (Sigma Chemical Co., St. Louis, Missouri, USA) digestion, tissue sections were incubated with rabbit antiserum against purified whole measles virus (MV) and purified trypsin-derivatized ribonucleoprotein from MV (Dr. B. Ziola, University of Saskatchewan, Saskatoon, Saskatchewan, Canada; 1/8,000 dilution; Haines et al., 1999), rabies virus (Animal Diseases Research Institute, Canadian Food Inspection Agency, Nepean, Ontario, Canada; 1/2,000 dilution), *Toxoplasma gondii* (Biogenex, San Ramon, California, USA; 1/800 dilution), or *Sarcocystis* sp. (Dr. J. P. Dubey, US Department of Agriculture, Beltsville, Maryland, USA; 1/500 dilution). A monoclonal antibody, isotype IgG2 α , to *Neospora caninum* (clone 6G7) (Dr. D. S. Lindsay, Auburn University, Auburn, Alabama, USA; 3 μ g IgG/ml) was used to detect *Neospora* antigens (Cole et al., 1993). The secondary antibodies, biotinylated goat antirabbit IgG or horse antimouse IgG (Vector Labs Inc., Burlington, Canada), were used at a 1/400 dilution. A positive control tissue for each antigen was included in each run of the immunohistochemical assay, and each tissue was stained using a substitution control for the primary antibody.

Virology

Tissue samples frozen at -70 C were available from the following animals: brain and lung from bobcat #2 and lynx #2 and #6, and lung from lynx #3 and #5. For virus isolation, 10% organ homogenates in Dubelco's Minimum Essential Medium (DMEM) supplemented with antibiotics were made of lung and brain samples using a tissue homogenizer (Kinematica Polytron, Lucerne, Switzerland). Homogenates were inoculated on Vero.DogSLAM cells for 1 hr at 37 C (Seki et al., 2003). Cell cultures were washed twice with culture medium, DMEM supplemented with antibiotics, and 10% Fetal Calf serum and incubated at 37 C humid atmosphere 5% CO₂. Cultures were checked routinely for cytopathic effects (CPE).

For reverse transcriptase polymerase chain reaction (RT-PCR), 300 μ l of the 10% organ homogenates were mixed with 300 μ l of lysis

buffer for RNA isolation. The High Pure Viral Nucleic Acid Kit (Roche Diagnostic GmbH, Mannheim, Germany) was used following the protocol provided by the manufacturer. Reverse transcriptase polymerase chain reaction was performed to detect morbilliviral RNA in lung and brain tissues of bobcat and lynx using morbillivirus specific primers P1: 5'ATGTT-TATGATCACAGCGGT3' and P2: 5'ATTGG-GTTGCACCACTTGTC3', after first strand synthesis with specific morbilliviral primers.

Automated sequencing of RT-PCR fragments was performed on an ABI 3130XL genetic analyzer with the Big Dye terminator cycle sequencing kit (ABI, Applied Biosystems, Foster City California, USA) using the RT-PCR primers P1 and P2. For identification of sequenced fragments, the BLAST option of the National Center for Biotechnology Information (NCBI) website was used (<http://www.ncbi.nlm.nih.gov/>). For phylogenetic analysis, the SEQBOOT and DNAML programs of the phylip package were used (Felsenstein, 2004).

RESULTS

Pathology

Among 14 carcasses of bobcats submitted for necropsy to the AVC between 1989 and 2005, the primary health problem identified was emaciation in seven animals, acute trauma from vehicular collision in four animals, cranio-ventral pulmonary congestion and edema possibly associated with acute aspiration pneumonia in one animal, and encephalitis in two animals. Among 14 lynx submitted during the same period, the primary health problem was emaciation in three animals, acute trauma from vehicular collision in three animals, chronic trauma caused by a snare and followed by emaciation in one animal, encephalitis in six animals, and undetermined in one animal.

The two bobcats with encephalitis were from NB. Both were immature and considered in good nutritional condition, based on the relative amount of their fat reserves and the relative size of their muscle masses (Table 1). Bobcat #1 had been found alive by a hunter and brought to a veterinary clinic where it was kept for 1 wk before being euthanized. While in captivity, this animal had a normal appetite but displayed

ataxia, a slight head tilt, partial cortical blindness, and progressive hind leg weakness. No gross lesion was seen at necropsy. Microscopically, lesions of encephalomyelitis were identified, characterized primarily by severe primary and secondary demyelination involving mainly the medullary region of the brain stem and associated with numerous microglial cells and gitter cells and much cellular debris (Table 1 and Fig. 1). In the medullary region of the brain stem, neuronal necrosis was marked, and a few neurons and astrocytes contained acidophilic intranuclear inclusion bodies. There was multifocal microgliosis in the cerebrum, cerebellum, and spinal cord. Perivascular cuffing, however, was not prominent in any region of the brain or spinal cord. The only other microscopic diagnosis in this animal was a mild multifocal cardiomyopathy characterized by small areas of degeneration of myocardial fibers accompanied by an infiltration of moderate numbers of inflammatory cells and a variable degree of fibrosis.

Bobcat #2 was reported to have shown convulsions before being shot. No lesion was seen grossly at necropsy except those caused by the gunshot. Microscopic lesions of encephalitis in this animal consisted of relatively few scattered nodules of microgliosis, mainly in the cerebral cortex, some of which contained small protozoal cysts. One nodule, composed of macrophages and lymphocytes and located in the subcortical white matter, contained a few structures approximately 20 μ m in diameter, with a thick acidophilic wall, and numerous small central nuclei, compatible with cross sections of a nematode larva.

All six lynx with encephalitis were from Cape Breton Island, NS. Three were immature, two were adult, and one was of undetermined age (Table 1). Five of these six lynx died or were euthanized between September 1996 and July 1997. In five cases, the animal was still alive when first seen and showed some evidence of abnormal behavior, such as ataxia, aggression, or tameness. A more detailed clinical exami-

TABLE 1. Main gross and microscopic findings in one bobcat (#1) and six lynx from eastern Canada diagnosed with encephalitis caused by morbillivirus and in one bobcat (#2) with encephalitis associated with protozoal cysts and a nematode larva and also with evidence of infection by morbillivirus.

	Species/Animal #							
	Bobcat #1	Bobcat #2	Lynx #1	Lynx #2	Lynx #3	Lynx #4	Lynx #5	Lynx #6
Month/year found	November 1993	March 1994	September 1996	December 1996	February 1997	May 1997	July 1997	September 1999
Sex/age	Male/immature	Male/immature	Male/immature	Male/immature	Male/immature	Unknown	Female/adult	Male/adult
Gross and microscopic morphologic diagnoses	Good nutritional condition (but captive for 1 wk). Diffuse encephalo-myelitis. Multifocal cardiomyopathy.	Good nutritional condition. Multifocal encephalitis	Emaciation. Diffuse encephalitis.	Good nutritional condition. Diffuse encephalitis.	Good nutritional condition (but captive for 3 wk). Diffuse encephalo-myelitis. Verminous pneumonia.	Only head submitted. Diffuse encephalitis.	Emaciation. Diffuse encephalitis. Verminous pneumonia. Lymphoid depletion.	Emaciation. Diffuse encephalitis. Multifocal cardiomyopathy. Verminous pneumonia. Lymphoid depletion.
Tissue preservation	Good	Poor	Poor	Poor	Good	Poor	Good	Moderate
Regions of CNS primarily affected ^a	Med obl, Cerebel, Spi co	Cer cort	Cer cort, Hipp, Cerebel	Cer cort, Hipp	Cer cort, Hipp, Thal, Med obl, Cerebel, Spi co	Thal	Cer cort, Hipp, Med obl, Opt n	Cer cort, Hipp
CNS—primary and secondary demyelination	Marked	No vacuolation distinct from freezing artifacts moderate, multifocal	No vacuolation distinct from freezing artifacts moderate, diffuse	No vacuolation distinct from freezing artifacts moderate, diffuse	Moderate but widespread	No vacuolation distinct from freezing artifacts	Marked	Slight
CNS—microgliosis	Marked, diffuse	Moderate, multifocal	Moderate, diffuse	Moderate, diffuse	Marked, diffuse	Slight, diffuse	Moderate, diffuse	Slight, diffuse
CNS—neuronal necrosis	Marked	None seen	Rare	Rare	Moderate	None seen	Moderate	Rare
CNS—perivascular cuffing	Slight	Slight	Moderate	Marked	Marked	Marked	Marked	Slight

TABLE 1. Continued.

	Species/Animal #							
	Bobcat #1	Bobcat #2	Lynx #1	Lynx #2	Lynx #3	Lynx #4	Lynx #5	Lynx #6
CNS-viral inclusion bodies	None seen	None seen	None seen	None seen	Few	None seen	Few	None seen
CNS-IHC ^b	Many positive cells diffusely	Several positive cells in one site	Many positive cells diffusely	Many positive cells diffusely	Many positive cells diffusely	Many positive cells diffusely	Many positive cells diffusely	Few positive cells diffusely

^a CNS = central nervous system; Cerebel = cerebellum; Cer cort = cerebral cortex; Hipp = hippocampus; Med obl = medulla oblongata; Opt n = optic nerve; Spi co = spinal cord; Thal = thalamus.

^b IHC = immunohistochemical stain (avidin-biotin-complex technique), using a rabbit antiserum against whole measles virus (MV) and purified ribonucleoprotein from MV.

nation in one of these animals revealed various degrees of myoclonus and cortical blindness. At necropsy, two lynx (#2, #3) were considered in good nutritional condition; one of them (#3) had been kept in captivity for 3 wk prior to euthanasia and had shown a normal appetite during that time. Three lynx (#1, #5, #6) were emaciated. The nutritional condition of the remaining lynx (#4), with only the head submitted, was not determined.

The only gross lesion identified in any of the six lynx, besides those of acute trauma (e.g., hit by car or shot), was mild pulmonary parasitism caused by *Troglostrongylus wilsoni* (van Zyll de Jong, 1966) in three individuals. Microscopically, encephalitis was the dominant pathologic process in all six animals, although artifacts associated with freezing and thawing and with autolysis precluded a detailed description of lesions in three of them. These lesions, which varied in severity in different regions of the brain and among the animals, included primary and secondary demyelination (identifiable in only three animals), multifocal to diffuse microgliosis (Fig. 2), neuronal necrosis, perivascular cuffing by macrophages, lymphocytes, and some plasma cells, and the presence of round, acidophilic, intranuclear and intracytoplasmic inclusion bodies of variable size in neurons and/or astrocytes (observed in only two animals; Fig. 3 and Table 1).

Relatively mild microscopic lesions of lymphoplasmacytic bronchointerstitial pneumonia were present in the three lynx with infection by *T. wilsoni*. Lymphoid depletion was noted in two of five lynx with encephalitis from which samples of spleen and/or lymph nodes had been taken. One lynx also had mild multifocal microscopic lesions of cardiomyopathy characterized by loss of myocardial fibers and infiltration of mononuclear leukocytes.

Immunohistochemistry

For the eight animals with encephalitis, IHC for morbillivirus was done on brain

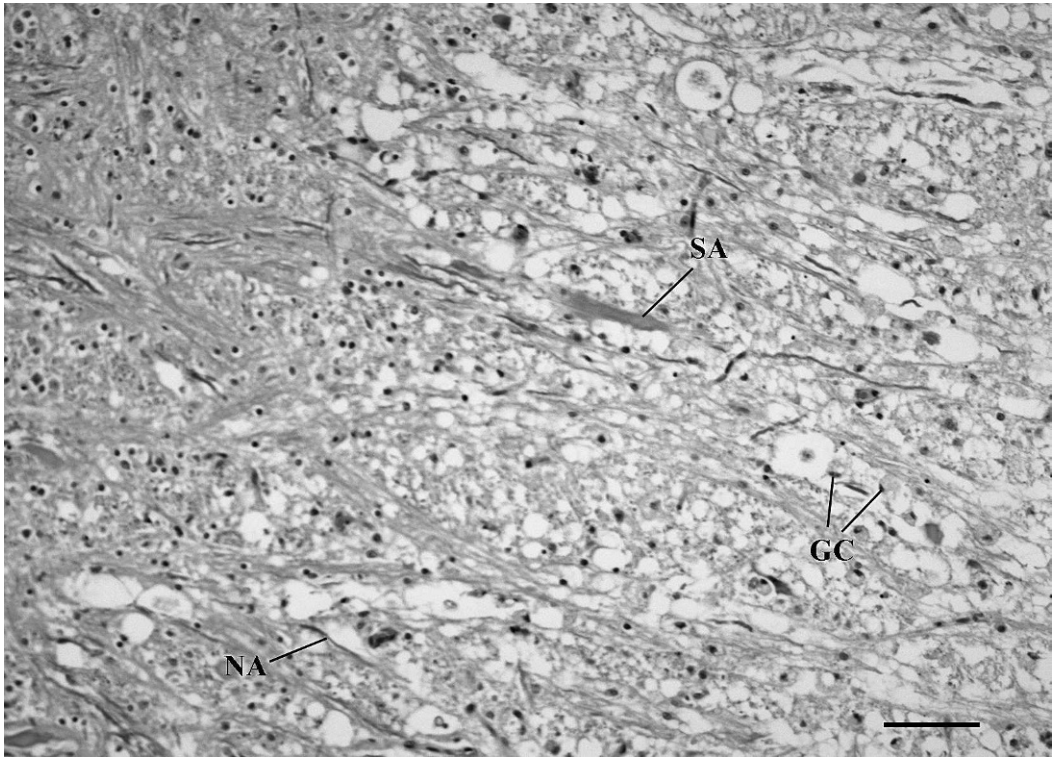


FIGURE 1. Marked vacuolation in the medulla oblongata of bobcat #1 with encephalitis caused by morbillivirus infection. Some swollen myelin sheaths contain a morphologically normal axon (NA) (primary demyelination), while others contain a swollen axon (SA) (secondary demyelination). Gitter cells (GC) are also present. Normal parenchyma is in the upper left corner. H&E. Bar=400 μ m.

and lungs of the two bobcats and six lynx, on the spleen of bobcat #1 and of the six lynx, and on lymph nodes of three lynx. Positive cells were identified in the brain of all eight animals and in the spleen of bobcat #1, but in none of the other tissues. In the brain, IHC identified numerous positive cells closely associated with lesions in bobcat #1 and in five of the six lynx and small numbers of cells scattered in the nervous parenchyma and also associated with lesions in lynx #6 (Fig. 4 and Table 1). In bobcat #2, IHC revealed several deeply staining neurons confined to one area of the thalamus that did not, however, show microscopic lesions.

Immunohistochemical staining for morbillivirus was also done on the brain, lungs, and/or spleen of seven of the 12 bobcats without encephalitis and of six of the eight lynx without encephalitis. Re-

sults were negative in all cases. Immunohistochemical staining for rabies virus was done on the brain of the eight animals with encephalitis, with negative results. Immunohistochemical staining for *T. gondii* and *Sarcocystis* and *Neospora* spp. on the brain of bobcat #2 was also negative.

Serology

A SN test for antibodies against CDV performed on serum samples collected from two lynx (#3, #5) shortly before euthanasia was positive at a titer of 1,445. A similar test performed on serum samples collected from two of four free-living, very thin lynx found on Cape Breton Island, NS, in spring 2000 was also positive (titers of 64 and 256, respectively), but it was negative in the two others (titers of 4 and 8, respectively). None of these four lynx exhibited clinical signs suggestive of encephalitis,

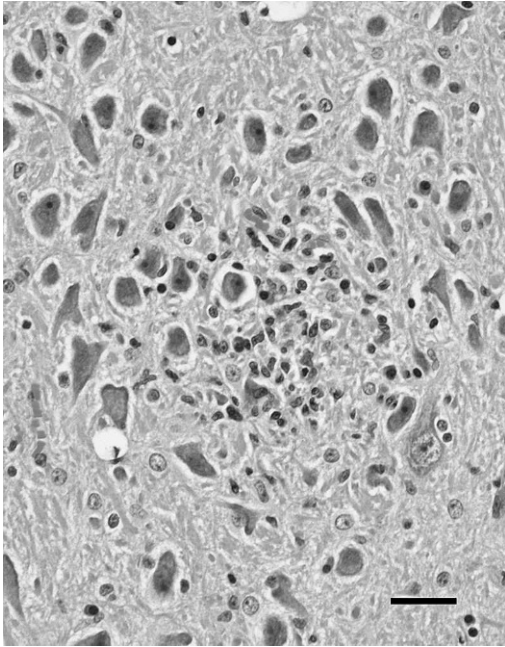


FIGURE 2. Focus of microgliosis in the hippocampus of lynx #2 with encephalitis caused by morbillivirus infection. H&E. Bar=200 μ m.

such as uncoordination or cortical blindness.

Virology

One of the brain homogenates, from bobcat #2, inoculated on Vero.DogSLAM cells resulted in a culture with clear CPE on day 6 after inoculation. Supernatant from this culture could be passaged onto fresh Vero.DogSLAM cells, resulting in similar CPE. Supernatants were checked by RT-PCR and nucleotide sequencing. The sequence of the morbillivirus present in the culture was identical to the one from the original material.

Both lung and brain samples from bobcat #2 and lynx #6 and lung samples from lynx #2 and #5 were positive according to RT-PCR using morbillivirus specific primers P1 and P2. Morbillivirus RNA could not be detected in the brain sample from lynx #2 and in the lung sample from lynx #3.

Sequences were compared to published morbillivirus sequences for identification

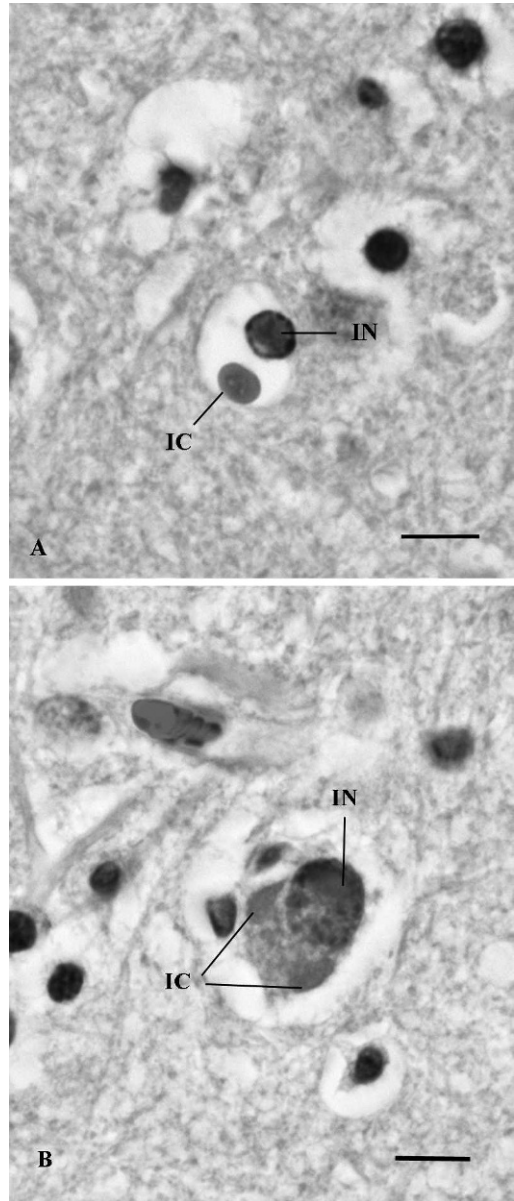


FIGURE 3. Cerebral cortex of lynx #4 with morbillivirus encephalitis. (A) Swollen astrocyte with intranuclear (IN) and intracytoplasmic (IC) inclusion bodies compatible with those caused by morbillivirus infection. (B) Neuron with one intranuclear (IN) and two intracytoplasmic (IC) inclusion bodies compatible with those caused by morbillivirus infection. H&E. Bar=40 μ m.

of morbillivirus species in the samples using the BLAST option of the NCBI website (<http://www.ncbi.nlm.nih.gov/>), and for phylogenetic comparison (Fig. 5).

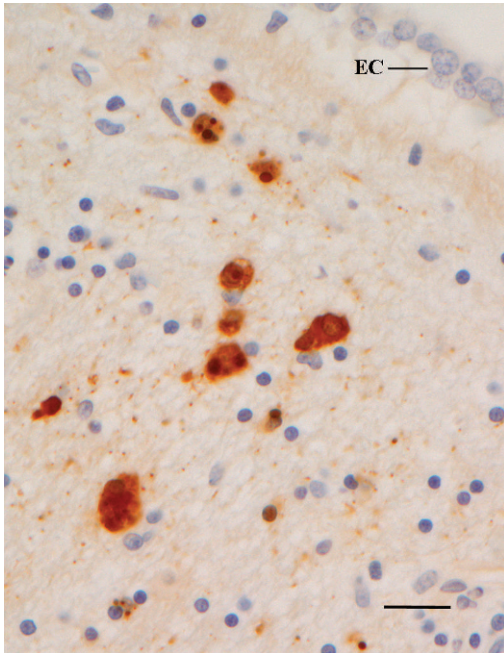


FIGURE 4. Periventricular region of a cerebral hemisphere of lynx #4 with morbillivirus encephalitis. Several cells show strong immunoreactivity for the presence of morbillivirus antigen. EC=ependymal cells of lateral ventricle. Avidin-biotin-complex immunohistochemical stain, using a rabbit antiserum against whole measles virus (MV) and purified ribonucleoprotein from MV. Bar=100 μ m.

Comparison of the 388-nucleotide fragment of the P gene with sequences from the Genbank database showed the highest identity of 98.5% with the wild type CDV strain A75/17, proving that the morbilliviruses in these lynx and bobcats were CDV. Sequences from the lynx from 1996, 1997, and 1999 were identical and treated as one sequence for phylogenetic analysis, Lynx #2. The sequence of the bobcat, Bobcat #2, showed 99.5% identity with the sequence from Lynx #2. These bobcat and lynx sequences showed the highest identity with CDV isolates obtained from dog, leopard, and gray fox from the USA between 1975 and 1992.

DISCUSSION

The diagnosis of encephalitis caused by morbillivirus infection in bobcat #1 and

the six lynx included in this report was based on the presence in the brain of cells that were positive for morbillivirus antigen according to IHC, the anatomic location of which coincided with microscopic evidence of a nonsuppurative inflammation and with lesions distinctive for infection by morbillivirus. The latter included primary and secondary demyelination and presence of viral intranuclear and intracytoplasmic inclusion bodies in neurons and astrocytes, although identification of these lesions was restricted to animals in a good state of postmortem preservation. A relatively high antibody titer on a SN test for morbillivirus in two lynx from which blood samples had been collected prior to euthanasia also suggested recent exposure of these two animals to this virus. Moreover, two of four wild lynx captured in 2000 in the same region of NS where the six affected lynx had been found had positive antibody titers against morbillivirus, also supporting at least occasional exposure of this lynx population to the virus. Although very thin and abnormally docile, these four lynx did not exhibit clinical signs suggestive of encephalitis when in captivity and were later released back into the wild. A coeval crash in the population of snowshoe hare may have been responsible for an inordinate prevalence of seemingly tame, emaciated lynx in that region at that time (Dan Banks, Nova Scotia Department of Natural Resources, pers. comm.; Poole, 2003).

Encephalitis attributed to morbillivirus infection was subsequently confirmed by the identification by RT-PCR and nucleotide sequencing of CDV in four of five animals from which frozen tissue samples were available. Philippa et al. (2004) included the serology results obtained from lynx #3 and #5 in their survey, and Biek et al. (2002) reported the presence of anti-CDV antibody titers in a small proportion (3%) of lynx from western North America. We believe, however, that this is the first report of disease caused by CDV in free-living felids in North America.

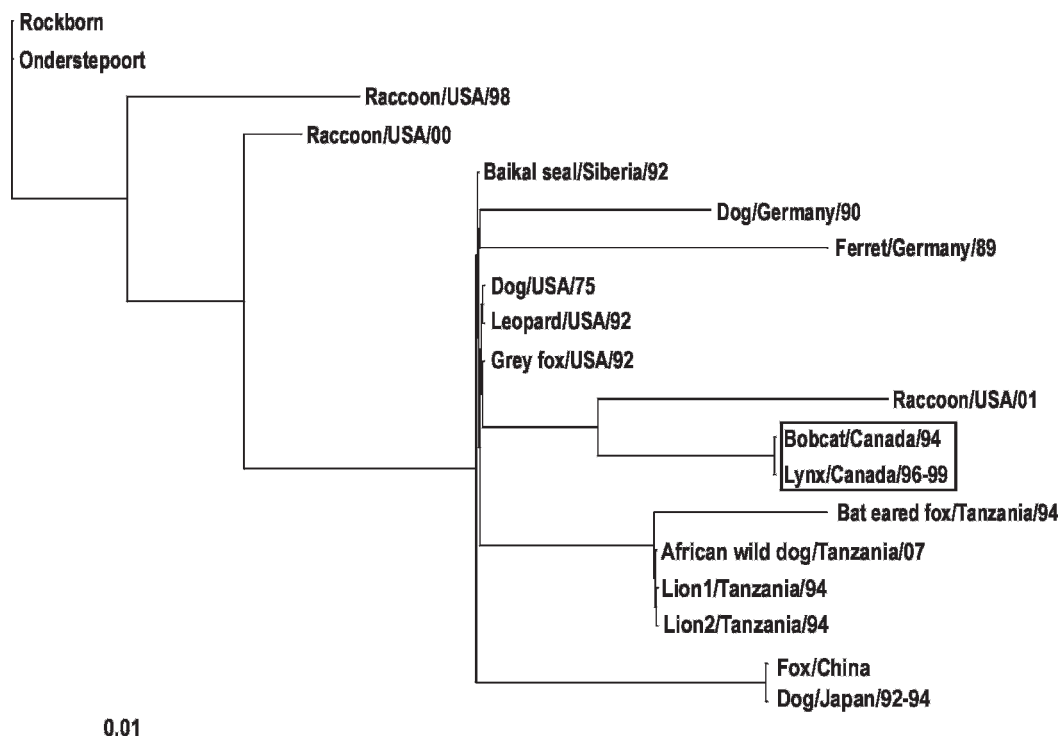


FIGURE 5. Phylogenetic analysis of representative CDV sequences, including free-living carnivores of North America and of felids, based on a 388-nucleotide fragment of the phosphoprotein (P) gene. The maximum likelihood tree was generated with the SEQBOOT and DNAML program of the Phylip package (Felsenstein, 2004) with 500 bootstraps. When available, Genbank accession numbers are given in parentheses: Onderstepoort: Onderstepoort strain (AF305419); Rockborn: Rockborn strain (AF181446); Raccoon/USA/98: raccoon brain 98-2645, USA, 1998 (AY445077); Raccoon/USA/00: raccoon brain 00-2601, USA, 2000 (AY443350); Baikal seal/Siberia/92: Baikal seal (*Phoca sibirica*), Siberia, 1992 (AF259551); Dog/Germany/90: dog 5804, Germany, 1990 (AY386315); Ferret/Germany/89: ferret, Germany, 1989 (AF259550); Dog/USA/75: domestic dog A75/17, USA, 1975 (AF164967); Leopard/USA/92: black leopard A92-6, USA, 1992 (Harder et al., 1995, 1996); Gray fox/USA/92: gray fox A92-9A, USA, 1992 (Harder et al., 1995, 1996); Raccoon/USA/01: raccoon brain 01-2689, USA, 2001 (AY649446); Bobcat/Canada/94: bobcat 94-X5538, Canada, 1994 (this study) (FJ240228); Lynx/Canada/96-99: lynx 97-X6984, Canada, 1996–99 (this study) (FJ240229); Bat-eared fox/Tanzania/94: bat-eared fox (*Otocyon megalotis*) 94-200, Tanzania, 1994 (U53714); African wild dog/Tanzania/07: X6511, African wild dog (*Lycaon pictus*), Tanzania, 2007 (EU481827); Lion1/Tanzania/94: lion 94-28/PLE, Tanzania, 1994 (Harder et al., 1995, 1996); Lion2/Tanzania/94: lion 94-52.10, Tanzania, 1994 (U53712); Fox/China: fox HLJ1-06, China (EU545143); Dog/Japan/92-94: dog, Hamamatsu, Japan, 1992–94 (AB028915).

Cells positive for morbillivirus antigen by IHC were also present in one area of the brain of bobcat #2, but that area did not show microscopic evidence of inflammation. Canine distemper virus was subsequently identified by RT-PCR in brain and lung samples from this animal. This bobcat had scattered microscopic inflammatory lesions caused by unidentified protozoa and a single lesion caused by a metazoan parasite identified as a larval

nematode. Pulmonary tissue from this bobcat was negative for morbillivirus by IHC but positive for CDV by RT-PCR, thus indicating an earlier systemic infection and, therefore, the possibility that the animal had suffered from some degree of immunosuppression secondary to this infection. Therefore, identification of a protozoal infection in this bobcat was not surprising. Activation of infection by *T. gondii* secondary to immunodeficiency

caused by CDV infection is well recognized in dogs (Dungworth, 1993). The larval nematode in this bobcat could not be identified but did not have the morphologic characteristics of an ascarid, such as the raccoon round worm, *Baylisascaris procyonis* (Bowman, 1987). The only report of a nematode larva in a felid brain available in the literature is that of *Dirofilaria immitis* in domestic cats (Bowman et al., 2002). Although it is not known with certainty whether this parasite is present in the part of NB where bobcat #2 was found, it is endemic in all parts of the United States, including the state of Maine, which is just south of NB (Bowman et al., 2003).

The outcome of infection by morbillivirus is influenced by the species and immune status of the host and by the viral strain or biotype involved. Experimental inoculation of domestic cats with CDV caused no clinical signs (Appel et al., 1974; Harder et al., 1996). In contrast, introduction of CDV, presumably from domestic dogs, into a free-living population of lions (*Panthera leo*) in Tanzania's Serengeti National Park in 1994 caused widespread mortality, as did the introduction of CDV, apparently from raccoons, into captive groups of lions, tigers (*Panthera tigris*), and leopards (*Panthera pardus*) in California in 1992 and 1993 (Appel et al., 1994; Roelke-Parker et al., 1996). Interestingly, in the latter outbreak, mortality was not seen in captive indigenous felids, including mountain lions and bobcats, or in smaller exotic cats, although it could not be determined whether these species were intrinsically more resistant to CDV infection or whether, in this case, the animals involved had enhanced immunity to this virus from previous exposure. The fact that attenuated variants of CDV used for vaccination are safe in healthy dogs but can be highly virulent for several species of wild carnivores also demonstrates the large variation in susceptibility to this virus among different species (Appel and Summers, 1995). The possibility of concurrent

infection by other viruses, such as feline leukemia virus or feline immunodeficiency virus, in lions from the Serengeti or in captive large cats from California that could have impaired their immune system and thus made them more susceptible to infection by CDV was considered, but no such co-infections were detected (Appel et al., 1994; Roelke-Parker et al., 1996).

Morbilliviruses have an affinity for epithelial, lymphoid, and nervous tissues (Dungworth, 1993). Encephalitis and interstitial pneumonia were common findings in lions that died of morbillivirus infection in the Serengeti in 1994, and interstitial pneumonia and severe lymphoid depletion were the primary lesions in large captive cats affected by this virus in California in 1992 and 1993 (Appel et al., 1994; Roelke-Parker et al., 1996). By comparison, and perhaps with the exception of some lymphoid depletion noted microscopically in two lynx, the only disease manifestation in bobcat #1 and in the six lynx was neurologic, and viral antigen was detected only in the brain in all cases, except for bobcat #1, which also had viral antigen in its spleen. The reason for this is not clear. Considering the normally secretive nature of bobcats and lynx, animals with encephalitis may be more likely detected than those with pneumonia because of their altered behavior. Dogs can develop a form of canine distemper that is chiefly or strictly confined to the central nervous system (CNS) (Coffin and Liu, 1957; Appel, 1969). This form typically occurs at least a month after initial infection, when lesions outside the CNS have disappeared and the virus has been cleared from most tissues other than the CNS. Based on experimental work by Appel (1969) in dogs, however, this form is uncommon. The mild multifocal cardiomyopathy in bobcat #1 and lynx #6 may have represented the reparative stage of primary myocardial necrosis secondary to their neurologic disease, as described in dogs (Robinson and Maxie, 1993).

The prominence of lesions in the CNS, such as perivascular cuffing, demyelination, and presence of viral inclusion bodies, varied substantially among the seven animals with encephalitis caused by morbillivirus. This variation may have been partly a reflection of the difficulty encountered in identifying some of these lesions in poorly preserved nervous tissue. However, Summers et al. (1984) demonstrated the strong influence of different strains of CDV on the types of microscopic lesions of encephalitis in dogs, some of which affected primarily the gray matter, while others caused mainly lesions of demyelination. They proposed that this difference might reflect a variation among viral strains in tropism for cells of the CNS (i.e. neurons versus astrocytes, respectively). A longer survival time of the host might also allow progression of the lesions from primary to secondary demyelination, which would be more easily distinguished from postmortem vacuolation in poorly preserved tissues. Finally, the occurrence of perivascular cuffs of inflammatory cells is a late development in the course of CDV-induced encephalitis and appears to coincide with the ability of the host to mount a cell-mediated immune response to the virus (Appel et al., 1982; Dungworth, 1993).

It is currently believed that genetic variants of CDV form geographic clusters of serologically monotypic viruses, or genotypes, rather than groups of viruses based on host origin (Harder et al., 1996; Harder and Osterhaus, 1997). Thus, morbilliviruses isolated from a variety of carnivore species in the Serengeti, including lions, spotted hyenas (*Crocuta crocuta*), bat-eared fox (*Otocyon megalotis*), and domestic dogs, were closely related and genetically distinct from isolates from various animal species in other parts of the world (Carpenter et al., 1998). Canine distemper virus does not persist long outside susceptible hosts, and these hosts do not become persistently infected (Appel and Summers, 1995). Bobcats and lynx

are solitary animals, and their social organization is characterized by intolerance and mutual avoidance (Poole, 2003). It is therefore doubtful that these species can maintain the virus within their populations in an endemic form, as compared, for example, to dense populations of unvaccinated dogs, in which pups continuously provide a reserve of susceptible hosts. Consequently, the source of CDV infection in bobcats and lynx in eastern Canada must be sought among other sympatric species of carnivores, such as canids (e.g., coyotes [*Canis latrans*], red fox [*Vulpes vulpes*]), mustelids (e.g., skunks, mink [*Mustela vison*], short-tailed weasels [*Mustela erminea*]), and raccoons. Canine distemper virus is shed in all excretions from infected animals during the systemic phase of infection, and viral transmission is thought to occur predominantly by inhalation of aerosols (Dungworth, 1993; Harder and Osterhaus, 1997). Beyond this, however, the nature of the interactions between bobcats or lynx, on one hand, and other species of carnivores, on the other hand, that would allow such transmission remains speculative. Lynx can predate on red fox (Stephenson et al., 1991), and remains of raccoons and skunks have been identified in a small proportion of stomach contents from bobcats in NS (Matlack and Evans, 1992). Moreover, bobcats and lynx might scavenge on larger preys such as white-tailed deer (*Odocoileus virginianus*) killed by coyotes and thus are potentially indirectly exposed to excretory products from these animals (Parker et al., 1983; Matlack and Evans, 1992). The possibility of direct spread between lynx or bobcats, however, cannot be ruled out, since these animals are passively territorial, using their excretions such as feces, urine, or anal secretions to mark their home range (Poole, 2003). Moreover, fights between conspecifics occasionally occur, usually related to territorial disputes (Jackson and Jackson, 1987). Cat-to-cat viral transmission was thought to have occurred during the

outbreak in zoo animals in California in 1992 and 1993, following the presumed introduction of CDV from wild raccoons (Appel et al., 1994).

The cluster of five cases among lynx from Cape Breton Island, NS, in the 11-mo period between September 1996 and July 1997 contrasted with a single case identified during the following 8 yr despite increased awareness by park wardens and provincial conservation officers of the possible occurrence of this disease among lynx in the region. This suggests a true peak in incidence of the disease in that lynx population at that time. The reason for this increased incidence is unknown. Emergence of a particularly virulent strain or biotype of CDV may have been a factor. This was suggested by some in order to explain the epidemic proportion of the disease and mortality among lions and other carnivores of the Serengeti in 1994 (Roelke-Parker et al., 1996; Carpenter et al., 1998), although, according to others, severe drought leading to high exposure of these animals to ticks carrying *Babesia* species was an important factor causing mortality (Munson et al., 2008). Alternatively, an epizootic of CDV in other carnivore species such as red fox, coyotes, or raccoons on Cape Breton Island in 1996–97 would have increased the likelihood of lynx becoming exposed to the virus. A study of the epidemiology of distemper in raccoons in New Jersey, USA, between 1977 and 1991 showed that the disease was enzootic in that population and that epizootics often tended to occur at 4-yr intervals (Roscoe, 1993). There is, however, no specific information available in the veterinary diagnostic laboratory of NS on the incidence of diagnoses of infection by CDV in different carnivore species of Cape Breton Island, except for the occasional occurrence of this disease in raccoons submitted for necropsy.

Biek et al. (2002) observed a low prevalence of antibodies to various infectious agents in lynx of western North America and concluded that these animals

have only limited exposure to these agents, particularly those such as CDV that require close contact for transmission and do not persist well outside their host. Nonetheless, transmission of CDV from other carnivore species to lynx or bobcats is likely more common than previously thought, as suggested by the fact that two of four free-living lynx captured in 2000, 3 yr after the cluster encountered in 1996–97, were seropositive for morbillivirus. These two animals were adults, however, and thus could have been exposed to the virus during the putative peak in incidence of the disease in their population in 1996–97. Similarly, the CDV outbreak encountered among lions in the Serengeti in 1994 was likely not the first time that this virus had crossed host species from canids to that species, since serum samples collected from lions between 1984 and 1989 in that region had antibodies to this virus without a corresponding increase in disease-related mortality having been observed during that period (Roelke-Parker et al., 1996; Carpenter et al., 1998).

Health surveillance of populations of bobcats and lynx in the eastern Canadian provinces of NB and NS continues to be passive in nature, based on opportunistic identification and recovery of sick or dead individual animals and their submission for necropsy. Because lynx are at risk of extirpation in NB and NS, disease caused by CDV and other infectious agents in these animals could potentially have a substantial impact on recovery of their population.

ACKNOWLEDGMENTS

We wish to thank the many park wardens and provincial conservation officers who shared our interest in health surveillance of lynx and bobcats in their respective regions. B. Summers, College of Veterinary Medicine, Cornell University, kindly reviewed histopathologic sections from the first case. J. Miller, Atlantic Veterinary College, University of Prince Edward Island, performed a clinical examination on some of the live animals

included in this report. T. Kuiken provided very useful comments on the contents of an earlier draft of this article.

LITERATURE CITED

- APPEL, M. J. G. 1969. Pathogenesis of canine distemper. *American Journal of Veterinary Research* 30: 1167–1182.
- , AND D. S. ROBSON. 1973. A microneutralization test for canine distemper virus. *American Journal of Veterinary Research* 34: 1459–1463.
- , AND B. A. SUMMERS. 1995. Pathogenicity of morbilliviruses for terrestrial carnivores. *Veterinary Microbiology* 44: 187–191.
- , B. E. SHEFFY, D. H. PERCY, AND J. M. GASKIN. 1974. Canine distemper virus in domesticated cats and pigs. *American Journal of Veterinary Research* 35: 803–806.
- , W. R. SHEK, AND B. A. SUMMERS. 1982. Lymphocyte-mediated immune cytotoxicity in dogs infected with virulent canine distemper virus. *Infection and Immunity* 37: 592–600.
- , R. A. YATES, G. L. FOLEY, J. J. BERNSTEIN, S. SANTINELLI, L. H. SPELMAN, L. D. MILLER, L. H. ARP, M. ANDERSON, M. BARR, S. PEARCE-KELLING, AND B. A. SUMMERS. 1994. Canine distemper epizootic in lions, tigers, and leopards in North America. *Journal of Veterinary Diagnostic Investigation* 6: 277–288.
- BIEK, R., R. L. ZARNKE, C. GILLIN, M. WILD, J. R. SQUIRES, AND M. POSS. 2002. Serologic survey for viral and bacterial infections in western populations of Canada lynx (*Lynx canadensis*). *Journal of Wildlife Diseases* 38: 840–845.
- BLYTHER, L. L., J. A. SCHMITZ, M. ROELKE, AND S. SKINNER. 1983. Chronic encephalomyelitis caused by canine distemper virus in a Bengal tiger. *Journal of the American Veterinary Medical Association* 183: 1159–1162.
- BOWMAN, D. D. 1987. Diagnostic morphology of four larval ascaridoid nematodes that may cause visceral larva migrans: *Toxascaris leonina*, *Baylisascaris procyonis*, *Lagochilascaris sprengi*, and *Hexametra leidyi*. *Journal of Parasitology* 73: 1198–1215.
- , C. M. HENDRIX, D. S. LINDSAY, AND S. C. BARR. 2002. The nematodes. *In* *Feline clinical parasitology*. Iowa State University Press, Ames, Iowa, pp. 233–354.
- , R. C. LYNN, AND M. L. EBERHARD. 2003. Helminths. *In* *Georgis' parasitology for veterinarians*. 8th Edition. W. B. Saunders Co., Philadelphia, Pennsylvania, pp. 115–243.
- CARPENTER, M. A., M. J. G. APPEL, M. E. ROELKE-PARKER, L. MUNSON, H. HOFER, M. EAST, AND S. J. O'BRIEN. 1998. Genetic characterization of canine distemper virus in Serengeti carnivores. *Veterinary Immunology and Immunopathology* 65: 259–266.
- COFFIN, D. L., AND C. LIU. 1957. Studies on canine distemper infection by means of fluorescein-labeled antibody. II. The pathology and diagnosis of the naturally occurring disease in dogs and the antigenic nature of the inclusion body. *Virology* 3: 132–145.
- COLE, R. A., D. S. LINDSAY, J. P. DUBEY, AND B. L. BLAGBURN. 1993. Detection of *Neospora caninum* in tissue sections using a murine monoclonal antibody. *Journal of Veterinary Diagnostic Investigation* 5: 579–584.
- DUNGWORTH, D. L. 1993. The respiratory system. *In* *Pathology of domestic animals*, Volume 2, 4th Edition, K. V. F. Jubb, P. C. Kennedy and N. Palmer (eds.). Academic Press, Toronto, Canada, pp. 539–699.
- FELSENSTEIN, J. 2004. PHYLIP (Phylogeny Inference Package) (Version 3.6). Department of Genome Sciences, University of Washington, Seattle, Washington.
- FIX, A. S., D. P. RIORDAN, H. T. HILL, M. A. GILL, AND M. B. EVANS. 1989. Feline panleukopenia virus and subsequent canine distemper virus infection in two snow leopards (*Panthera uncia*). *Journal of Zoo and Wildlife Medicine* 20: 273–281.
- GOULD, D. H., AND W. R. FENNER. 1983. Paramyxovirus-like nucleocapsids associated with encephalitis in a captive Siberian tiger. *Journal of the American Veterinary Medical Association* 183: 1319–1322.
- HAINES, D. M., AND B. J. CHELACK. 1991. Technical considerations for developing enzyme immuno-histochemical staining procedures on formalin-fixed paraffin-embedded tissues for diagnostic pathology. *Journal of Veterinary Diagnostic Investigation* 3: 101–112.
- , K. M. MARTIN, B. J. CHELACK, R. A. SARGENT, C. A. OUTERBRIDGE, AND E. G. CLARK. 1999. Immunohistochemical detection of canine distemper virus in haired skin, nasal mucosa, and footpad epithelium: A method for antemortem diagnosis of infection. *Journal of Veterinary Diagnostic Investigation* 11: 396–399.
- HARDER, T. C., AND A. D. M. E. OSTERHAUS. 1997. Canine distemper virus—A morbillivirus in search of new hosts? *Trends in Microbiology* 5: 120–124.
- , M. KENTER, M. J. G. APPEL, M. E. ROELKE-PARKER, T. BARRETT, AND A. D. M. E. OSTERHAUS. 1995. Phylogenetic evidence of canine distemper virus in Serengeti's lions. *Vaccine* 13: 521–523.
- HARDER, T. C., M. KENTER, H. VOS, K. SIEBELINK, W. HUISMAN, G. VAN AMERONGEN, C. ÖRVELL, T. BARRETT, M. J. G. APPEL, AND A. D. M. E. OSTERHAUS. 1996. Canine distemper virus from diseased large felids: Biological properties and phylogenetic relationships. *Journal of General Virology* 77: 397–405.
- JACKSON, D. H., AND L. S. JACKSON. 1987. An observation of fighting between free-ranging bobcats, *Lynx rufus*. *Canadian Field-Naturalist* 101: 465–466.

- KENNEDY, S. 1998. Morbillivirus infections in aquatic mammals. *Journal of Comparative Pathology* 119: 201–225.
- MATLACK, C. R., AND A. J. EVANS. 1992. Diet and condition of bobcats, *Lynx rufus*, in Nova Scotia during autumn and winter. *Canadian Journal of Zoology* 70: 1114–1119.
- MUNSON, L., K. A. TERIO, R. KOCK, T. MLENGEYA, M. E. ROELKE, E. DUBOVI, B. SUMMERS, A. R. E. SINCLAIR, AND C. PACKER. 2008. Climate extremes promote fatal co-infections during canine distemper epidemics in African lions. *PLoS ONE* 3 (6): e2545. doi: 10.1371/journal.pone.0002545.
- PARKER, G. R., AND G. E. J. SMITH. 1983. Sex- and age-specific reproductive and physical parameters of the bobcat (*Lynx rufus*) on Cape Breton Island, Nova Scotia. *Canadian Journal of Zoology* 61: 1771–1782.
- , J. W. MAXWELL, L. D. MORTON, AND G. E. J. SMITH. 1983. The ecology of the lynx (*Lynx canadensis*) on Cape Breton Island. *Canadian Journal of Zoology* 61: 770–786.
- PHILIPPA, J. D. W., F. A. LEIGHTON, P.-Y. DAoust, O. NIELSEN, M. PAGLIARULO, H. SCHWANTJE, T. SHURY, R. VAN HERWIJNEN, B. E. E. MARTINA, T. KUIKEN, M. W. G. VAN DE BILDT, AND A. D. M. E. OSTERHAUS. 2004. Antibodies to selected pathogens in free-ranging terrestrial carnivores and marine mammals in Canada. *Veterinary Record* 155: 135–140.
- POOLE, K. G. 2003. A review of the Canada lynx, *Lynx canadensis*, in Canada. *Canadian Field-Naturalist* 117: 360–376.
- ROBINSON, W. F., AND M. G. MAXIE. 1993. The cardiovascular system. *In* *Pathology of domestic animals*, 4th Edition, Volume 3, K. V. F. Jubb, P. C. Kennedy and N. Palmer (eds.). Academic Press, Toronto, Canada, pp. 1–100.
- ROELKE-PARKER, M., L. MUNSON, C. PACKER, R. KOCK, S. CLEAVELAND, M. CARPENTER, S. O'BRIEN, A. POSPISCHIL, R. HOFMANN-LEHMANN, H. LUTZ, G. L. M. MWAMENGELE, M. N. MCGASA, G. A. MACHANGE, B. A. SUMMERS, AND M. J. G. APPEL. 1996. A canine distemper virus epidemic in Serengeti lions (*Panthera leo*). *Nature* 379: 441–445.
- ROSCOE, D. E. 1993. Epizootiology of canine distemper in New Jersey raccoons. *Journal of Wildlife Diseases* 29: 390–395.
- SEKI, F., N. ONO, R. YAMAGUCHI, AND Y. YANAGI. 2003. Efficient isolation of wild strains of canine distemper virus in Vero cells expressing canine SLAM (CD150) and their adaptability to Marmoset B95a cell. *Journal of Virology* 77: 9943–9950.
- STEPHENSON, R. O., D. V. GRANGAARD, AND J. BURCH. 1991. Lynx, *Felis lynx*, predation on red foxes, *Vulpes vulpes*, caribou, *Rangifer tarandus*, and Dall sheep, *Ovis dalli*, in Alaska. *Canadian Field-Naturalist* 105: 255–262.
- STOCEK, R. F. 1995. The cougar, *Felis concolor*, in the Maritime Provinces. *Canadian Field-Naturalist* 109: 19–22.
- SUMMERS, B. A., H. A. GREISEN, AND M. J. G. APPEL. 1984. Canine distemper encephalomyelitis: Variation with virus strain. *Journal of Comparative Pathology* 94: 65–75.
- VAN ZYLL DE JONG, C. G. 1966. Parasites of the Canada lynx, *Felis (Lynx) canadensis* (Kerr). *Canadian Journal of Zoology* 44: 499–509.
- WOOD, S. L., G. W. THOMSON, AND D. M. HAINES. 1995. Canine distemper virus-like infection in a captive African lioness. *Canadian Veterinary Journal* 36: 34–35.

Received for publication 14 September 2007.