



GRANULOMATOUS INFLAMMATION IN RETROPHARYNGEAL LYMPH NODES OF WILD CERVIDS IN SASKATCHEWAN

Authors: Chiu, Jung-To, Wobeser, Gary, and Bollinger, Trent

Source: Journal of Wildlife Diseases, 45(3) : 625-630

Published By: Wildlife Disease Association

URL: <https://doi.org/10.7589/0090-3558-45.3.625>

BioOne Complete (complete.BioOne.org) is a full-text database of 200 subscribed and open-access titles in the biological, ecological, and environmental sciences published by nonprofit societies, associations, museums, institutions, and presses.

Your use of this PDF, the BioOne Complete website, and all posted and associated content indicates your acceptance of BioOne's Terms of Use, available at www.bioone.org/terms-of-use.

Usage of BioOne Complete content is strictly limited to personal, educational, and non - commercial use. Commercial inquiries or rights and permissions requests should be directed to the individual publisher as copyright holder.

BioOne sees sustainable scholarly publishing as an inherently collaborative enterprise connecting authors, nonprofit publishers, academic institutions, research libraries, and research funders in the common goal of maximizing access to critical research.

GRANULOMATOUS INFLAMMATION IN RETROPHARYNGEAL LYMPH NODES OF WILD CERVIDS IN SASKATCHEWAN

Jung-To Chiu,¹ Gary Wobeser,^{1,2} and Trent Bollinger¹

¹ Canadian Cooperative Wildlife Health Centre, Department of Veterinary Pathology, Western College of Veterinary Medicine, University of Saskatchewan, Saskatoon, Saskatchewan S7N 5B4, Canada

² Corresponding author (email: gary.wobeser@usask.ca)

ABSTRACT: A portion of retropharyngeal lymph nodes from 6,824 wild cervids, comprising 1,458 white-tailed deer (*Odocoileus virginianus*), 5,345 mule deer (*Odocoileus hemionus*), 11 unidentified deer (*Odocoileus* spp.), and 10 elk (*Cervus elaphus*), were examined histologically for evidence of inflammation. Focal granulomatous lymphadenitis was detected in 0.3% of white-tailed deer, 1.3% of mule deer, and in one of 10 elk. Material consistent with Splendore-Hoeppli phenomenon was present in 70 (93%) of 75 cases of lymphadenitis. Replicate sections stained with Gram, acid fast, and methenamine silver stains were examined for organisms. Organisms morphologically consistent with *Actinomyces* spp. were found in one white-tailed deer; no organisms were detected in any of the other cases of lymphadenitis. Aerobic and anaerobic culture from frozen tissue from the lymph nodes was negative, as was polymerase chain reaction (PCR) for *Mycobacterium* spp. and *Mycobacterium bovis*. The method of sampling likely underestimated the prevalence of lymphadenitis.

Key words: *Actinomyces*, cervids, lymphadenitis, mycobacteria.

INTRODUCTION

Chronic inflammation of lymph nodes of the head occurs in domestic ruminants in association with infection caused by a variety of microorganisms, notably *Actinobacillus lignieresii* in cattle and *Corynebacterium pseudotuberculosis* in sheep. Infection with *Mycobacterium bovis* may cause granulomatous lymphadenitis in cattle and deer (Griffin et al., 2006), and the retropharyngeal lymph nodes are the most frequently involved site in deer infected naturally (Schmitt et al., 1997; O'Brien et al., 2001) and experimentally with *M. bovis* (Palmer et al., 2002). Observation of chronic inflammation in retropharyngeal lymph nodes collected from wild deer in Saskatchewan, Canada, as part of a surveillance program for Chronic Wasting Disease (CWD) prompted this study to determine the prevalence and possible cause of lymphadenitis in wild deer.

MATERIALS AND METHODS

As part of the surveillance program for CWD in Saskatchewan, Canada, heads of white-tailed deer (*Odocoileus virginianus*), mule deer (*Odocoileus hemionus*), and elk (*Cervus elaphus*) were collected from hunters in the autumn of

2004. Most heads were frozen when submitted, and all were held frozen at ambient winter temperature until processed. At the time of processing, heads were thawed, identified to species and sex, and age was estimated based on tooth wear (Larson and Taber, 1980). For CWD surveillance, a portion of the obex region of the medulla oblongata, the palatine tonsil, and one retropharyngeal lymph node from each animal were fixed in 10% neutral-buffered formalin for 24 hr, then treated with 95% formic acid for 1 hr, followed by immersion in a water bath for 15 min before routine histologic processing, sectioning at 6 μ m, and immunohistochemical staining for abnormal prion protein with a hematoxylin counterstain (Spraker et al., 2002). Another portion of retropharyngeal lymph node from each animal was stored at -20 C. Slides from all animals were examined for presence of abnormal prion protein, and only animals that were test negative for CWD were used for the present study. Hematoxylin-stained sections of retropharyngeal lymph node from 1,458 white-tailed deer, 5,345 mule deer, 11 unidentified deer, and 10 elk were examined microscopically for evidence of inflammation. Replicate microscopic slides prepared from nodes with evidence of inflammation were stained with hematoxylin-eosin (H&E), Brown and Brenn (Gram) stain, Fite's acid fast stain, and Gomorri's methenamine silver stain (GMS; Luna, 1968). Sections stained with these stains were examined microscopically at 400 \times for at least 15 min for pathogens by a single observer.

The portion of retropharyngeal lymph node held at -20 C from each case with micro-

scopic evidence of inflammation was thawed and divided into three portions. One portion was submitted to Prairie Diagnostic Services (PDS) Inc. (Saskatoon, Saskatchewan, Canada) for bacteriologic examination. A direct smear was stained with Gram stain and examined, and aerobic and anaerobic culture, using 5% sheep blood agar, was done. Plates were incubated at 37 C under 5% carbon dioxide condition for 5 days for aerobic culture. For anaerobic culture, duplicate plates were sealed in an anaerobic jar (Anaerocult A, EM Science, Gibbstown, New Jersey) and incubated at 37 C for 5 days. All agar plates were examined for growth of possible pathogens on days two and five of incubation.

Another portion of frozen lymph node from each deer was used for polymerase chain reaction (PCR) testing at PDS. The portion of lymph node was trimmed to a final total volume of tissue of 3–5 mm³. The DNA was extracted with lysis buffer (100 mM NaCl, 500 mM Tris [pH 8], 10% sodium dodecyl sulfate (VWR Scientific Products, Mississauga, Ontario, Canada) followed by proteinase K (0.2 ng/ml) digestion (Promega Corporation, Madison, Wisconsin). The resulting product was ribolyzed in a FastPrepTM FP120 machine (Thermo Savant, Holbrook, New York) at speed 6.0 for 45 sec with 100 µl of zirconium beads (Biospec Products Inc., Bartlesville, Oklahoma), followed by a second ribolyzing with an additional equal volume of phenol-chloroform (1:1). Two solvent extractions with phenol-chloroform (1:1) were performed. Nucleic acids were concentrated by precipitation in cold, salted, 95% ethanol (1:10 volume 3 M sodium acetate), dried thoroughly in a vacuum, resuspended in 100 µl of sterile water and further diluted 1:100 in sterile water.

Nested PCR was performed for *Mycobacterium* spp. In primary PCR, amplification of a 792 base-pair fragment of the gene sequence of *Mycobacterium* sp. was performed using in-house–designed primers Mb-F1 (5'-CGGAG-GAATCACTTCGCA-3') and Mb-R1 (5'-CTTGTTGACGACCAGGGT-3'). The DNA was amplified in a 50-µl final reaction mixture consisting of 5 µl of 10× PCR buffer, 4 µl of 25 mM MgCl₂, 0.5 µl of 25 mM dNTPs, 2 µl of each primer (20 pmol), 34.25 µl of H₂O, 0.25 µl of Taq polymerase (5 U/µl), and 2 µl of sample DNA. (All reagents were supplied by Fennetas Life Sciences, Ontario, Ontario, Canada). The mixtures were placed in a PTC 200 thermal cycler (MJ Research, Watertown, Massachusetts; licensed by Perkin-Elmer Cetus, Norwalk, Connecticut). Initial incubation occurred at 94 C for 5 min. This was followed by 45 cycles of amplification at 94 C for 1 min,

60 C and 72 C for 1 min and 50 sec each. Finally, specimens were incubated at 72 C for 7 min. Secondary PCR was performed using primary PCR products and primers Mb-F2 (5'-ACCAACGATGGTGTGTCCAT-3') and Mb-R2 (5'-CTTGTCGAACCGCATACCCT-3') for detection of a 439 base-pair fragment of the *Mycobacterium* sp. gene sequence (Telenti et al. 1993). DNA was amplified as described above for primary DNA amplification, except that the initial incubation occurred at 94 C for 5 min. This was followed by 45 cycles of amplification consisting of 94 C for 60 sec and 60 C and 72 C for 60 sec each. Finally, specimens were incubated at 72 C for 10 min. The PCR products were separated by electrophoresis through 1.5% agarose gel and visualized with ethidium bromide using ultraviolet light. Tissue from a wood bison (*Bison bison athabasca*) naturally infected with *M. bovis* was used as a positive control, and a PCR solution with water was used as a negative control.

Amplification of a 123 base-pair fragment of the IS611 0 insertion sequence gene region of *Mycobacterium* sp. (tuberculosis complex) was performed using the primers IS611 0-F (5'-CTCGTCCAGCGCCGCTTCGG-3') and IS611 0-R (5'-CCTGCGAGCGTAGGCGTC-GG-3'). The DNA was amplified as described above for primary DNA amplification, except that initial incubation occurred at 94 C for 10 min followed by 72 C for 135 sec. This was followed by 40 cycles of amplification consisting of 94 C for 45 sec and 72 C for 85 sec. Finally, specimens were incubated at 72 C for 10 min. Respective positive and negative controls and separation of PCR products were used as described above.

Because we were concerned that treatment with 95% formic acid might have interfered with the special stains used to detect bacteria, three small trials were performed. A portion of fresh tissue from a bovine infected with *Actinomyces bovis* (lumpy jaw) was fixed in 10% neutral-buffered formalin for 24 hr, treated with decalcifying solution (20% formic acid, 36.5% formaldehyde solution, and distilled water in 1:1:5 ratio) for 4 days and then divided into two portions. One portion was processed using the 95% formic acid treatment and histologic procedures used for the deer tissues. The other was submitted for histologic procedures without prior treatment with 95% formic acid. In the second trial, fixed tissue known to contain acid-fast bacilli from a cow with paratuberculosis, two chickens with avian tuberculosis, and an elk infected with *M. bovis*, were each divided into two portions. One portion was treated with 95% formic acid before processing, and the other was submit-

TABLE 1. Species, age and sex composition of a sample of cervids examined for lymphadenitis. The number of animals with lymphadenitis is indicated in brackets.

Species and gender	Age				Total No.
	No. Fawn ^a	No. Yearling ^b	No. Adult ^c	No. Unknown	
White-tailed deer					
Male	200 (1)	52	111 (1)	1	364 (2)
Female	280 (1)	202	595 (1)		1,091 (2)
Unknown	1		1	1	3
Mule deer					
Male	719 (2)	154 (3)	815 (15)	12	1,700 (20)
Female	844 (3)	613 (5)	2,152 (41)	22	3,631 (49)
Unknown	2	1	8 (1)	3	14 (1)
Unknown deer (Male)				11	11
Elk					
Male		2	4 (1)		6 (1)
Female	1		2	1	4

^a Fawns were born in 2004.

^b Yearlings were born in 2003.

^c Adults were born before 2003.

ted for processing without formic acid treatment. The two tissue portions from each of the animals were mounted in a single paraffin block, sectioned, and stained with Fite’s acid fast stain. In the third trial, a portion of frozen lymph node from 26 (34.7%) of the 75 animals with lymphadenitis was fixed in 10% neutral buffered formalin and then processed histologically without prior treatment with 95% formic acid, sectioned, and stained with H&E and the other stains described previously.

RESULTS

Species, sex, and age of the animals examined are shown in Table 1. Seventy-five animals comprising 70 mule deer, four white-tailed deer, and one elk had microscopic evidence of lymphadenitis (Table 1). The prevalence of lymphadenitis in mule deer (1.3%, 70/5,345) was significantly greater than that in white-tailed deer (0.3%, 4/1,458; $\chi^2=11.41, P=0.0007$). The prevalence in males and females was not significantly different in either white-tailed or mule deer. In white-tailed deer, the prevalence in fawns was not significantly different from that in adults ($\chi^2=0.15, P=0.6979$). In mule deer, the prevalence in fawns was significantly less than that in yearlings ($\chi^2=4.85, P=0.0277$) and adults

($\chi^2=19.40, P=<0.0001$), but the prevalence in yearlings was not significantly different from that in adults ($\chi^2=2.73, P=0.0982$).

Microscopic lesions in the lymph nodes consisted of single to multiple foci, composed of large numbers of macrophages with a few multinucleated giant cells, and rimmed by moderate numbers of lymphocytes and plasma cells and a small amount of fibrous tissue. Large numbers of neutrophils were present in some cases. In 70 cases (93%), there were radiating, club-shaped bodies of homogeneous eosinophilic material (Splendore-Hoeppli material [SH]) within the inflammatory foci (Fig. 1). No microorganisms were identified in sections stained with Gram stain, GMS stain, or Fite’s acid fast stain from 74 of the cases. In one white-tailed deer, an aggregation of branching filamentous organisms that stained positive in Gram stain and GMS stain (Fig. 2), but negative in Fite’s acid fast stain, was seen. This staining pattern is consistent with that of *Actinomyces* spp. (Biberstein and Hirsch, 2004). Lesions similar to those described above were found in 10 (38.5%) of the 26 cases from which tissue frozen at -70 C was

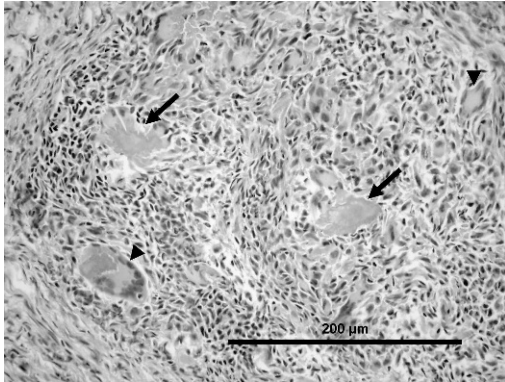


FIGURE 1. Granuloma within the retropharyngeal lymph node of a mule deer. Multiple giant cells (small arrows) and small collections of Splendore-Hoeppli material (large arrows) are evident. The inflammatory cells in this animal are predominantly lymphocytes and macrophages. H&E stain.

thawed, fixed in 10% neutral-buffered formalin, and prepared routinely for histopathologic examination without treatment with 95% formic acid. No microorganisms were observed in any of the 26 cases.

No pathogens were identified in Gram-stained smears taken from lymph nodes from any of the 75 cases. Aerobic and anaerobic cultures of retropharyngeal lymph nodes were negative. Tissues from all cases were negative for *Mycobacterium* spp. and *M. bovis* by PCR.

The specimen of bovine actinomycosis had pyogranulomatous inflammation associated with SH phenomenon visible in H&E stain. Branching filamentous organisms that were Gram positive, GMS positive, and that did not stain acid fast, were equally visible in the center of SH phenomenon on tissue with and without treatment with 95% formic acid. Formic acid treatment had no visible effect on acid-fast staining of bacteria in any of the cases of mycobacterial infection tested.

DISCUSSION

We detected lymphadenitis in 1.1% of the deer and elk (75/6,824) examined. In a similar survey in Nebraska, USA, Steffen et al. (1999) reported lymphadenitis in 3%




FIGURE 2. Filamentous microorganisms within a granuloma in the retropharyngeal lymph node of a white-tailed deer. Splendore-Hoeppli material that was present about the bacteria is not evident in this methenamine silver-stained section.

of 271 white-tailed deer. The difference in prevalence may be related to differences in sampling because multiple lymph nodes from adult deer were examined in Nebraska, USA, whereas we examined a single node from deer of all ages. The apparent prevalence in our study probably underestimates the actual prevalence of lymphadenitis. The lesions were small and focal, and hence, likely to be missed in the 6- μ m section examined per animal. This is illustrated by finding lesions in only 10 (39%) of 26 positive cases when a second section was prepared from another area of the same node.

The prevalence in mule deer >1 yr old was significantly greater than that in white-tailed deer of the same age, which might suggest that mule deer are more vulnerable to lymphadenitis than white-tailed deer. The prevalence in deer <1 yr old (species combined) was significantly less than that in deer >1 yr old, suggesting that lymphadenitis is a chronic condition that accumulates with age.

The identity of the organism(s) responsible for lesions in the retropharyngeal lymph nodes of wild deer was not established. We detected microorganisms in only one animal. The lesion in that animal contained filamentous organisms consistent with *Actinomyces* spp. No

microorganisms were detected in similar lesions from deer in Nebraska, USA, using Gram and acid-fast stains (Steffen et al., 1999). Tissue handling, including freezing and thawing before fixation, may have influenced our ability to identify microorganisms. Treatment with 95% formic acid was unlikely to have affected the special stains for pathogens.

Material consistent with SH was found in 93% of the lesions. This material is considered to be antigen-antibody complex and may be associated with immunoglobulin, complement cell debris from degenerate leukocytes or eosinophilic granule major protein (Schlossberget al., 1998; Read et al., 2005). It is a nonspecific phenomenon reported in many chronic conditions including infection by fungi, helminths, and certain bacteria, as well as in foreign body reactions to material such as sutures (Johnson, 1976). This material has been reported in infections caused by *Arcanobacterium pyogenes*, *Actinobacillus lignieresii*, and *Actinomyces bovis* in ruminants (Seifi et al., 2003; Songer and Post 2005). The SH phenomenon has not been associated with *Mycobacterium* spp. infection in deer (Fitzgerald et al., 2000). We did not observe foreign material in the retropharyngeal lymph nodes in any of the lesions, and we believe the lesions may have resulted from prior infection by bacteria from the oral cavity. Based on the combination of failure to find acid-fast bacteria and the negative PCR analysis for *Mycobacterium* spp. and *M. bovis*, we believe that is unlikely that the lesions in the deer we examined were caused by *Mycobacterium* spp.

ACKNOWLEDGMENTS

This study was funded by the Canadian Cooperative Wildlife Health Centre and Saskatchewan Environment. We acknowledge the valuable technical assistance provided by M. Zimmer, A. Tumber, and P. Dillman.

LITERATURE CITED

BIBERSTEIN, E. L., AND D. C. HIRSH. 2004. Filamentous bacteria: *Actinomyces*, *Nocardia*, *Dermato-*

philus, and *Streptobacillus*. In *Veterinary microbiology*, 2nd Edition, N. J. Hirsh, N. J. MacLachlan and R. L. Walker (eds.). Blackwell Publishing, Oxford, UK, pp. 215–222.

- FITZGERALD, S. D., J. B. KANEENE, K. L. BUTLER, K. R. CLARKE, J. S. FIERKE, S. M. SCHMITT, C. S. BRUNING-FANN, R. R. MITCHELL, D. E. BERRY, AND J. B. PAYEUR. 2000. Comparison of post-mortem techniques for the detection of *Mycobacterium bovis* in white-tailed deer (*Odocoileus virginianus*). *Journal of Veterinary Diagnostic Investigation* 12: 322–327.
- GRIFFIN, J. F., C. R. RODGERS, S. LIGGETT, AND C. G. MACKINTOSH. 2006. Tuberculosis in ruminants: characteristics of intra-tonsillar *Mycobacterium bovis* infection models in cattle and deer. *Tuberculosis* 86: 404–418.
- JOHNSON, E. B. 1976. Splendore-Hoepli phenomenon. In *Pathology of Tropical and Extraordinary Diseases*, C. H. Binford and D. H. Connor (eds.). Armed Forces Institute of Pathology, Washington, D.C., pp. 681–683.
- LARSON, I. S., AND R. D. TABER. 1980. Criteria of sex and age. In *Wildlife Management Techniques Manual*, 4th Edition, S. D. Schemnitz (ed.). The Wildlife Society, Washington, D.C., pp. 143–202.
- LUNA, L. G. 1968. *Manual of histologic staining methods of the armed forces institute of pathology*, 3rd Edition. McGraw-Hill Book Company, New York, New York, 258 pp.
- O'BRIEN, D. J., S. D. FITZGERALD, T. J. LYON, K. L. BUTLER, J. S. FIERKE, K. R. CLARKE, S. M. SCHMITT, T. M. COOLEY, AND D. E. BERRY. 2001. Tuberculous lesions in free-ranging white-tailed deer in Michigan. *Journal of Wildlife Diseases* 37: 608–613.
- PALMER, M. V., W. R. WATERS, AND D. L. WHIPPLE. 2002. Lesion development in white-tailed deer (*Odocoileus virginianus*) experimentally infected with *Mycobacterium bovis*. *Veterinary Pathology* 39: 334–340.
- READ, R. W., I. ZHANG, T. ALBINI, M. EVANS, AND N. A. RAO. 2005. Splendore-Hoepli phenomenon in the conjunctiva: Immunohistochemical analysis. *American Journal of Ophthalmology* 140: 262e1–262e7.
- SCHLOSSBERG, D., M. PANDEY, AND R. REDDY. 1998. The Splendore-Hoepli phenomenon in hepatic botryomycosis. *Journal of Clinical Pathology* 51: 399–400.
- SCHMITT, S. M., S. D. FITZGERALD, T. M. COOLEY, C. S. BRUNING-FANN, L. SULLIVAN, D. BERRY, T. CARLSON, R. B. MINNIS, J. B. PAYEUR, AND J. SIKARSKIE. 1997. Bovine tuberculosis in free-ranging white-tailed deer from Michigan. *Journal of Wildlife Diseases* 33: 749–758.
- SEIFI, H. A., S. SAIFZADEH, A. A. FARSHID, M. RAD, AND F. FARROKHI. 2003. Mandibular pyogranulomatous osteomyelitis in a Saanen goat. *Journal of Veterinary Medicine A* 50: 219–221.

- SONGER, J. G., AND K. W. POST. 2005. *Veterinary microbiology: Bacterial and fungal agents of animal disease*. Elsevier Saunders, Philadelphia, Pennsylvania, 434 pp.
- SPRAKER, T. R., K. I. O'ROURKE, A. BALACHANDRAN, R. R. ZINK, B. A. CUMMINGS, M. W. MILLER, AND B. E. POWERS. 2002. Validation of monoclonal antibody F99/97.6.1 for immunohistochemical staining of brain and tonsil in mule deer (*Odocoileus hemionus*) with chronic wasting disease. *Journal of Veterinary Diagnostic Investigation* 14: 3–7.
- STEFFEN, D. J., D. W. OATES, M. C. STERNER, AND V. L. COOPER. 1999. Absence of tuberculosis in free-ranging deer in Nebraska. *Journal of Wildlife Diseases* 35: 105–107.
- TELENTI, A., F. MARCHESI, M. BALZ, F. BALLY, E. C. BÖTTGER, AND T. BODMER. 1993. Rapid identification of mycobacteria to the species level by polymerase chain reaction and restriction enzyme analysis. *Journal of Clinical Microbiology* 31: 175–178.

Received for publication 21 September 2008.