



## **Multicentric T-cell Lymphosarcoma in a White-tailed Deer (*Odocoileus virginianus*)**

Authors: Madson, D. M., and Opriessnig, T.

Source: Journal of Wildlife Diseases, 45(3) : 791-794

Published By: Wildlife Disease Association

URL: <https://doi.org/10.7589/0090-3558-45.3.791>

---

BioOne Complete ([complete.BioOne.org](https://complete.BioOne.org)) is a full-text database of 200 subscribed and open-access titles in the biological, ecological, and environmental sciences published by nonprofit societies, associations, museums, institutions, and presses.

Your use of this PDF, the BioOne Complete website, and all posted and associated content indicates your acceptance of BioOne's Terms of Use, available at [www.bioone.org/terms-of-use](https://www.bioone.org/terms-of-use).

Usage of BioOne Complete content is strictly limited to personal, educational, and non - commercial use. Commercial inquiries or rights and permissions requests should be directed to the individual publisher as copyright holder.

---

BioOne sees sustainable scholarly publishing as an inherently collaborative enterprise connecting authors, nonprofit publishers, academic institutions, research libraries, and research funders in the common goal of maximizing access to critical research.

## Multicentric T-cell Lymphosarcoma in a White-tailed Deer (*Odocoileus virginianus*)

D. M. Madson<sup>1</sup> and T. Opriessnig<sup>1,2</sup> <sup>1</sup>Department of Veterinary Diagnostic and Production Animal Medicine, Iowa State University, Ames, Iowa 50011, USA; <sup>2</sup>Corresponding author (email: tanjaopr@iastate.edu)

**ABSTRACT:** An adult female white-tailed deer (*Odocoileus virginianus*) with a history of shaking, ataxia, and severe debilitation was submitted for examination. Macroscopic lesions included severe emaciation, severe abdominal and mesenteric lymphadenopathy, and several rumen-associated masses. Microscopically, the ruminal masses and lymph nodes were infiltrated by pleomorphic neoplastic lymphocytes. Similar lymphoblasts were associated with the leptomeninges, choroid plexus, and the intestinal mucosa; these cells were intensely positive for CD3 antigen, indicating their T-cell origin. Lymphoproliferative viruses (bovine leukemia virus and malignant catarrhal fever virus) or epizootic hemorrhagic disease virus were not detected by polymerase chain reaction. To our knowledge, this case represents the first report of the immunophenotype of a multicentric lymphosarcoma, metastasis involving the brain, and epitheliotropic lymphoblasts in a white-tailed deer.

**Key words:** Cervidae, lymphosarcoma, T-cell, white-tailed deer.

A live, free-ranging, approximately 1.5-year-old, 50-kg female white-tailed deer (*Odocoileus virginianus*) with a history of shaking, ataxia, and severe debilitation was submitted to the Iowa State University Veterinary Diagnostic Laboratory (Ames, Iowa, USA). At submission, the deer was extremely weak and nonambulatory and was humanely euthanized.

A complete necropsy revealed severe emaciation with low body fat stores. Gross lesions included severe abdominal and mesenteric lymphadenopathy (up to 4 times the normal size), and several infiltrative masses associated with the rumen. The cut surfaces of the masses and the lymph nodes were gray-white and soft. Tissue sections of brain, lung, thymus, heart, spleen, kidney, liver, rumen, retic-

ulum, omasum, abomasum, small intestine, colon, and lymph nodes (hepatic, ileocolic, and mesenteric) were collected and placed in 10% phosphate buffered formalin. Tissues fixed overnight were embedded in paraffin wax, cut into 4- $\mu$ m-thick sections, and stained with hematoxylin and eosin for routine microscopic examination. In addition, fresh tissue samples were collected for routine aerobic and anaerobic bacterial cultures and for virus identification by polymerase chain reaction (PCR).

No significant bacteria were isolated from cultured specimens. Fresh lymph node and spleen were negative for epizootic hemorrhagic disease virus, malignant catarrhal fever virus (MCFV), and bovine leukemia virus (BLV) by PCR, which was performed at the Veterinary Diagnostic Laboratory at Colorado State University (Fort Collins, Colorado, USA). The brain (obex) and retropharyngeal lymph nodes were found to be negative for chronic wasting disease (CWD) protein by immunohistochemistry (National Veterinary Services Laboratory Ames, Iowa, USA).

Microscopic evaluation of lymph node sections revealed that the nodal parenchyma was effaced by cellular infiltrates composed of highly pleomorphic lymphoblasts (Fig. 1). These cells contained variable amounts of lightly basophilic cytoplasm with round nuclei that often contained deeply basophilic nucleoli. Mitotic figures were frequently observed with up to 9 figures per 40 $\times$  field. Numerous tingible body macrophages and rare multinucleated giant cells were also observed within the tumors (Fig. 1).

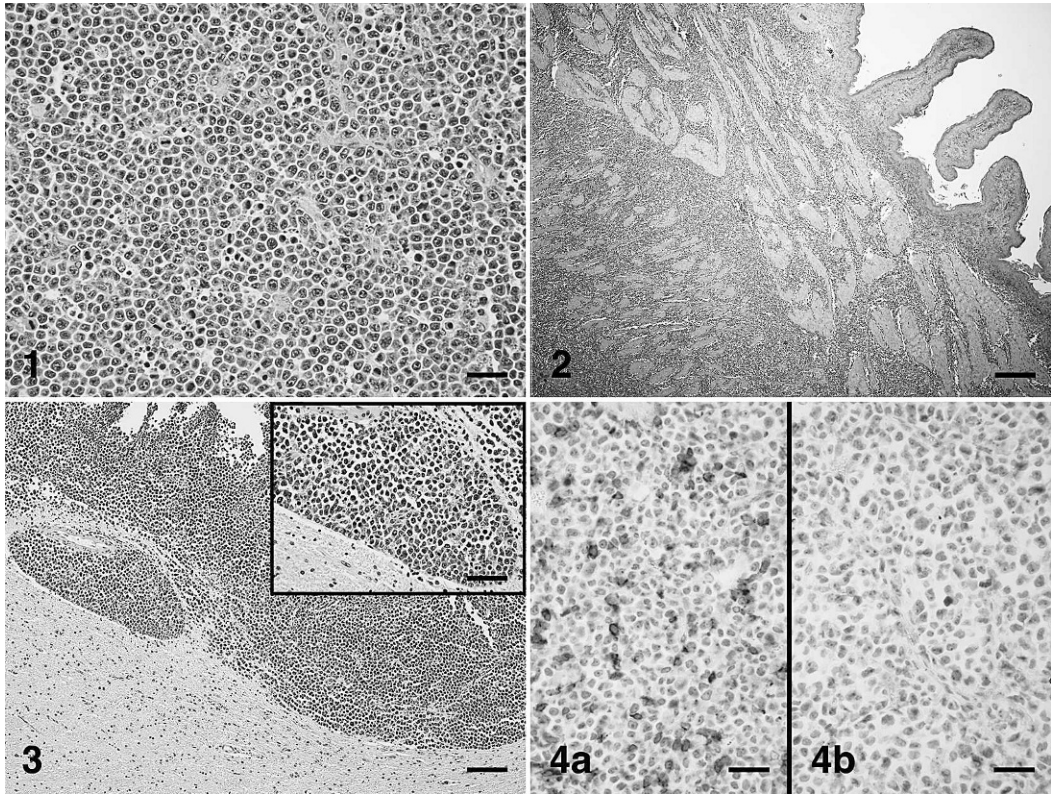


FIGURE 1. Lymph node. Highly pleomorphic and mitotic lymphoblasts efface the nodal parenchyma. Hematoxylin and eosin. Bar=40  $\mu$ m. FIGURE 2. Rumen. Lymphoblasts infiltrate and expand the tunica serosa, tunica muscularis, and submucosa. Hematoxylin and eosin. Bar=400  $\mu$ m. FIGURE 3. Cerebrum. Expanding the leptomeninges and impinging upon the cortical gray matter are highly pleomorphic lymphoblasts. Hematoxylin and eosin. Bar=150  $\mu$ m. Inset shows detail of the lymphoblasts. Bar=80  $\mu$ m. FIGURE 4. Lymph node. a. Immunohistochemical labeling for CD3 antigen. Streptavidin-biotin immunoperoxidase method, hematoxylin counterstain. Approximately 25% of the lymphoblasts are staining positive for CD3 with chromogen located on cellular membranes and with the cytoplasm. Bar=40  $\mu$ m. b. Immunohistochemical staining for CD79a antigen. Streptavidin-biotin immunoperoxidase method, hematoxylin counterstain. Lymphoblasts are negative for CD79 antigen. Bar=40  $\mu$ m.

Neoplastic cells also invaded the nodal capsule and were present in adjacent mesenchymal tissue. The rumen-associated masses were composed of similar lymphoblasts that infiltrated and expanded the tunica serosa, tunica muscularis, and to a lesser extent the submucosa and lamina propria (Fig. 2). In sections of brain, poorly delineated, densely cellular sheets of pleomorphic lymphoblasts similar to those seen in other tissues expanded the leptomeninges and impinged upon the cerebral cortical gray matter (Fig. 3). In addition, the lamina propria of multiple small intestinal segments was expanded by

cellular infiltrate composed of two distinct cell populations. Approximately two thirds of the cells were composed of mildly pleomorphic lymphoblasts that were frequently observed dispersed within the intestinal epithelium. The second population was composed of eosinophils. Microscopic evaluations of other tissues collected at necropsy were unremarkable.

Based on the gross and microscopic examinations and exclusion of infection with lymphoproliferative viruses (BLV and MCFV), epizootic hemorrhagic disease virus, and bacteria, lymphosarcoma was diagnosed. To characterize the tumor

cells, immunophenotyping was performed using immunohistochemistry. Stored tissues sections of lymph node and spleen from different white-tailed deer were used as a positive control for the immunohistochemical staining procedure. B-cells were identified by CD79a antibody (Dako North America, Inc., Carpinteria, California, USA) diluted 1:800; for T-cell identification, CD3 antibody (Dako) was diluted 1:100. The secondary biotinylated goat anti-rabbit antibody (Vector Laboratories, Burlingame, California, USA) was labeled with streptavidin horseradish peroxidase (BioGenex Laboratories, Inc., San Ramon, California, USA), and nova red (Invitrogen Corp., Carlsbad, California, USA) was used as the chromogen.

Approximately 25% of the neoplastic lymphoblasts in the lymph node sections stained positive for CD3 (Fig. 4a) but were negative for CD79a (Fig. 4b). Immunostaining of CD3 positive cells showed intense chromogen located on cellular membranes with lesser amounts of staining within the cytoplasm. Similar CD3 and CD79 staining characteristics were present within the ruminal masses, sections of brain, and the intestinal mucosal. The positive CD3 staining indicates T-cell origin of the lymphoblasts.

Solitary and multicentric forms of sporadic lymphosarcoma have been described in free-ranging (Debbie and Friend, 1967) and captive white-tailed deer (Lombard and Witte, 1959; Cosgrove et al., 1981). Of the cases of lymphosarcoma in white-tailed deer reported to date, most were multicentric and often involved thoracic and abdominal viscera (Debbie and Friend, 1967; Cosgrove et al., 1981). Only one solitary lymphosarcoma in the maxilla of a white-tailed deer was further immunophenotyped and determined to be of T-cell origin (Larsen et al., 2002). A unique finding in the present case was the involvement of the leptomeninges and choroid plexus. This finding is typical of metastatic lymphosarcomas involving the central nervous system in other species

(Koestner and Higgins, 2002) but has not been reported in a cervid species with solitary or multicentric lymphoma. In comparison, multicentric enzootic lymphosarcoma in domestic cattle often results in infiltration of the central nervous system (Jacobs et al., 2002). In contrast to multicentric forms, primary lymphosarcomas in the central nervous system are characterized by deep-seated solitary masses, and these tumors are generally of T-cell origin (Koestner and Higgins, 2002).

The multicentric T-cell lymphosarcoma in this case was epitheliotropic in intestinal segments. Epithelial tropism is common amongst T-cell lymphosarcomas and has been reported in bovine sporadic forms involving the skin and alimentary tract (Kadota et al., 2001). Interestingly, in dogs, alimentary forms of T-cell lymphosarcomas may have increased numbers of eosinophils within the lamina propria (Ozaki et al., 2006). A similar finding was evident in small intestinal sections. This observation may represent a paraneoplastic syndrome of intestinal T-cell lymphosarcomas as seen in dogs (Marchetti et al., 2005), but more cases are needed to determine whether this is a common finding in T-cell lymphosarcomas of cervids.

To our knowledge, the present case is the first report of a multicentric T-cell lymphosarcoma in a white-tailed deer, with metastasis involving the brain, and epitheliotropism of lymphoblasts. In the future, lymphosarcoma should be considered as a differential diagnosis for the clinical signs associated with central nervous system diseases such as CWD or MCFV in white-tailed deer.

#### LITERATURE CITED

- COSGROVE, G. E., L. C. SATTERFIELD, AND V. F. NETTLES. 1981. Neoplasia. *In* Diseases and parasites of white-tailed deer, W. R. Davidson, F. A. Hayes, V. F. Nettles and F. E. Kellogg (eds.). Miscellaneous Publication No. 7 Tall Timbers Research Station, Tallahassee, Florida, pp. 62–71.
- DEBBIE, J. G., AND M. FRIEND. 1967. Lymphosarcoma

- in a white-tailed deer. *Bulletin of Wildlife Disease Association* 3: 38–39.
- JACOBS, R. M., J. B. MESSICK, AND V. E. VALLI. 2002. Tumors of the hemolymphatic system. *In* Tumors in domestic animals, 4th Edition, D. J. Meuten (ed.). Iowa State Press, Ames, Iowa, pp. 119–198.
- KADOTA, K., Y. WADA, Y. ISHIKAWA, AND T. SHIBAHARA. 2001.  $\gamma\delta$  T-cell lymphoma with tropism for various types of epithelium in a cow. *Journal of Comparative Pathology* 124: 308–312.
- KOESTNER, A., AND R. J. HIGGINS. 2002. Tumors of the nervous system. *In* Tumors in domestic animals, 4th Edition, D. J. Meuten (ed.). Iowa State Press, Ames, Iowa, pp. 697–738.
- LARSEN, R. S., J. W. CARPENTER, G. A. KENNEDY, AND N. MORALES. 2002. Maxillary lymphosarcoma in a white-tailed deer (*Odocoileus virginianus*). *Journal of Wildlife Diseases* 38: 611–615.
- LOMBARD, L. S., AND E. J. WITTE. 1959. Frequency and types of tumors in mammals and birds of the Philadelphia Zoological Garden. *Cancer Research* 19: 127–141.
- MARCHETTI, V., C. BENETTI, S. CITI, AND V. TACCINI. 2005. Paraneoplastic hypereosinophilia in a dog with intestinal T-cell lymphoma. *Veterinary Clinical Pathology* 34: 259–263.
- OZAKI, K., T. YAMAGAMI, K. NOMURA, AND I. NARAMA. 2006. T-cell lymphoma with eosinophilic infiltration involving the intestinal tract in 11 dogs. *Veterinary Pathology* 43: 339–344.

*Received for publication 13 May 2008.*