



Laryngeal Snaring by Ingested Fishing Net in a Common Bottlenose Dolphin (*Tursiops truncatus*) Off the Israeli Shoreline

Authors: Levy, Alon M., Brenner, Ori, Scheinin, Aviad, Morick, Dan, Ratner, Eliana, et al.

Source: Journal of Wildlife Diseases, 45(3) : 834-838

Published By: Wildlife Disease Association

URL: <https://doi.org/10.7589/0090-3558-45.3.834>

BioOne Complete (complete.BioOne.org) is a full-text database of 200 subscribed and open-access titles in the biological, ecological, and environmental sciences published by nonprofit societies, associations, museums, institutions, and presses.

Your use of this PDF, the BioOne Complete website, and all posted and associated content indicates your acceptance of BioOne's Terms of Use, available at www.bioone.org/terms-of-use.

Usage of BioOne Complete content is strictly limited to personal, educational, and non - commercial use. Commercial inquiries or rights and permissions requests should be directed to the individual publisher as copyright holder.

BioOne sees sustainable scholarly publishing as an inherently collaborative enterprise connecting authors, nonprofit publishers, academic institutions, research libraries, and research funders in the common goal of maximizing access to critical research.

Laryngeal Snaring by Ingested Fishing Net in a Common Bottlenose Dolphin (*Tursiops truncatus*) Off the Israeli Shoreline

Alon M. Levy,^{1,2,4} Ori Brenner,¹ Aviad Scheinin,^{2,3} Dan Morick,² Eliana Ratner,^{2,3} Oz Goffman,^{2,3} and Dan Kerem^{2,3} ¹Weizmann Institute of Science, PO Box 12, Rehovot 76100, Israel; ²Israeli Marine Mammal Research & Assistance Center (IMMRAC), Michmoret 40297, Israel; ³Recanati Institute for Maritime Studies and Department of Maritime Civilizations, University of Haifa, Mount Carmel, Haifa 31905, Israel; ⁴Corresponding author (email: alon.levy@weizmann.ac.il)

ABSTRACT: We report an unusual snaring of the larynx in an adult, female common bottlenose dolphin (*Tursiops truncatus*). The dolphin was observed swimming and diving in Haifa Port, Israel, but was found dead the next day, 60 km south, on the coast. Postmortem examination revealed stranded-cordage, nylon filaments wrapped around the larynx, cutting through the soft tissue, and extending down into the forestomach, where a large mass of netting was found. The cachectic state of the dolphin and the subacute to chronic, hyperplastic response of soft tissue surrounding the filaments lodged around the larynx, suggest a prolonged period of starvation, which led to the final weakness and wasting of the dolphin.

Key words: Cetacea, gillnet, marine pollution, *Tursiops truncatus*.

The effect of plastic debris on marine mammals is a major environmental concern worldwide. Although entanglement in derelict fishing gear poses a major threat (Donohue et al., 2001), cetaceans often suffer from blockage of the alimentary tract due to ingested items (Laist, 1987, 1997; Derraik, 2002). We report an unusual, but possibly not uncommon, outcome of fishing net ingestion by a bottlenose dolphin off the Israeli coast.

On 2 February 2007, at 9 AM, a dolphin entered the Port of Haifa (32°49'39"N, 34°59'43"E), Israel, and swam between the breakwater and the passenger docks. The mature common bottlenose dolphin (*Tursiops truncatus*) was very thin and was observed swimming normally and actively, performing up to 2-min-long dives and apparently foraging. It was last reported inside the port at 3:30 PM. In late afternoon of the next day, the very fresh body of a

dolphin (intact glossy skin with fresh abrasions, clear corneas, fading rigor mortis) was reported floating in the breakers of Poleg Beach, 60 km south of the port of Haifa. Strong southwesterly winds were blowing throughout the day. It was identified as a mature, female common bottlenose dolphin and was transported that evening to a facility 25 km away, where it remained at ambient temperature (16 C) awaiting necropsy; the necropsy was performed early next morning. Comparison of external scars and dorsal fin notching pattern to photographs taken of the swimming dolphin (Fig. 1), confirmed that it was the same individual sighted inside Haifa Port on the previous day.

The dolphin measured 303 cm, the longest female ever documented by the Israeli Marine Mammal Research & Assistance Center (IMMRAC). Skin pigmentation, especially neck markings, was uncharacteristic of the Israeli coastal population. The dolphin was cachectic, showed epaxial muscle wasting and weighing only 180 kg, less than half the weight expected using an exponential equation derived from length-weight data of local beached specimens (IMMRAC, unpubl.). Later on, age determination (performed by P. Goldin, Vernadsky Taurida National University, Simferopol, Ukraine) indicated that the dolphin was 16 yr old.

On gross necropsy, the midlateral (in line with the anterior edge of the dorsal fin) blubber thickness was 15 mm, slightly less than the mean of 18 mm observed in apparently healthy individuals bycaught along the Israeli Mediterranean coast.

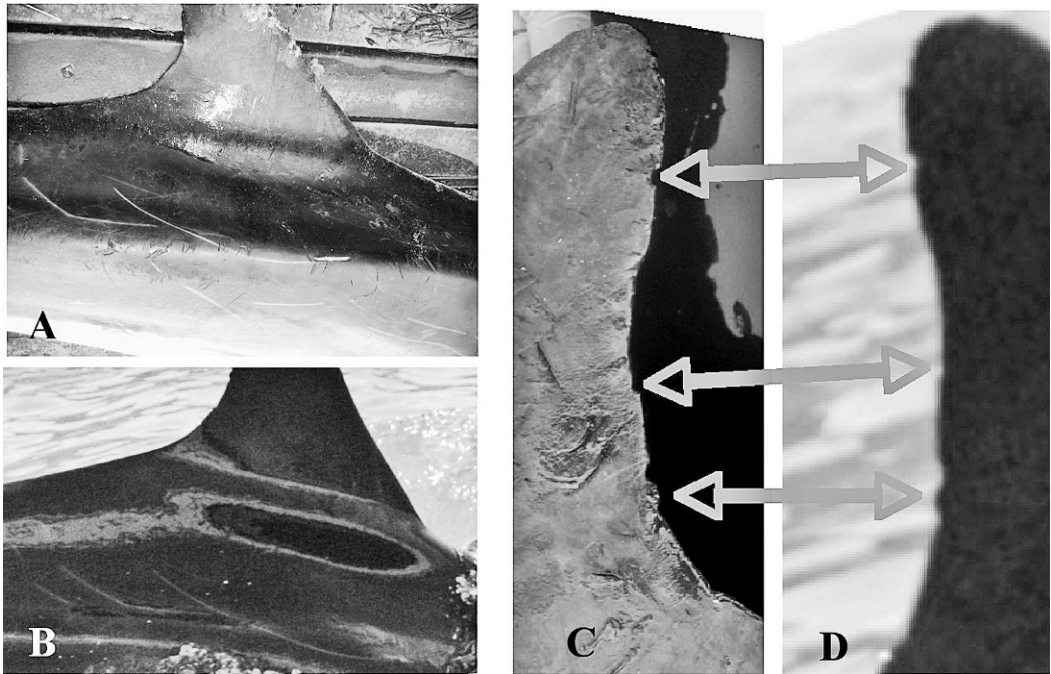


FIGURE 1. Matched scars and dorsal fin profile in swimming and autopsied common bottlenose dolphin (*Tursiops truncatus*). A. Scar marks on carcass. B. Scar marks on the swimming dolphin. C. Profile of the posterior edge of the dorsal fin—carcass. D. Profile of the posterior edge of the dorsal fin in the swimming dolphin.

There were no external lacerations, net marks, or subcutaneous hemorrhages. The dolphin was neither gravid nor lactating. Kidneys, liver, and heart were grossly unremarkable. Yellowish frothy liquid filled the airways.

There were two round, approximately 1.3-cm-diameter ulcers, on the tongue. When cut, the ulcer was found to consist of well-demarcated necrotic tissue, which extended approximately 1 cm deep. The main abnormal finding was the presence of stranded-cord, nylon, gillnet filaments wrapped around the larynx (Fig. 2A), just caudal to the ary-epiglottic tube (goose-neck). The filaments cut into the soft tissue and were located within a deep groove flanked by exuberant and irregular soft tissue proliferation. The epiglottis and plica ary-epiglottica were rounded and appeared swollen. The netting material extended down into the esophageal lumen and was attached to a 15-cm-diameter, solid mass

inside the forestomach (Fig. 2B). The mass was composed of netting, parasitic nematodes (*Anisakis* spp.), and brown, tar-like cement with four embedded, 2-cm-long fishhooks, each with an attached length of 2–5 cm monofilament fishing line. The hooks were neither pitted nor corroded. A single cephalopod beak was the only prey item found. The fundic and pyloric (second and third) gastric chambers and the intestines were empty and contained slimy, yellowish-green mucus.

When partially unraveled, the mass was found to be composed of sections of nine different types of gillnet with mesh sizes, ranging from 1.5×1.5 cm to 4×4 cm. The material of seven of the gillnet types was double/multiple-stranded, cotton chord; the other two were made of nylon monofilament line. Dominating the mass was the extension of the laryngeal snare, with an estimated size of 5 m². Upon inspection, local fishermen claimed that

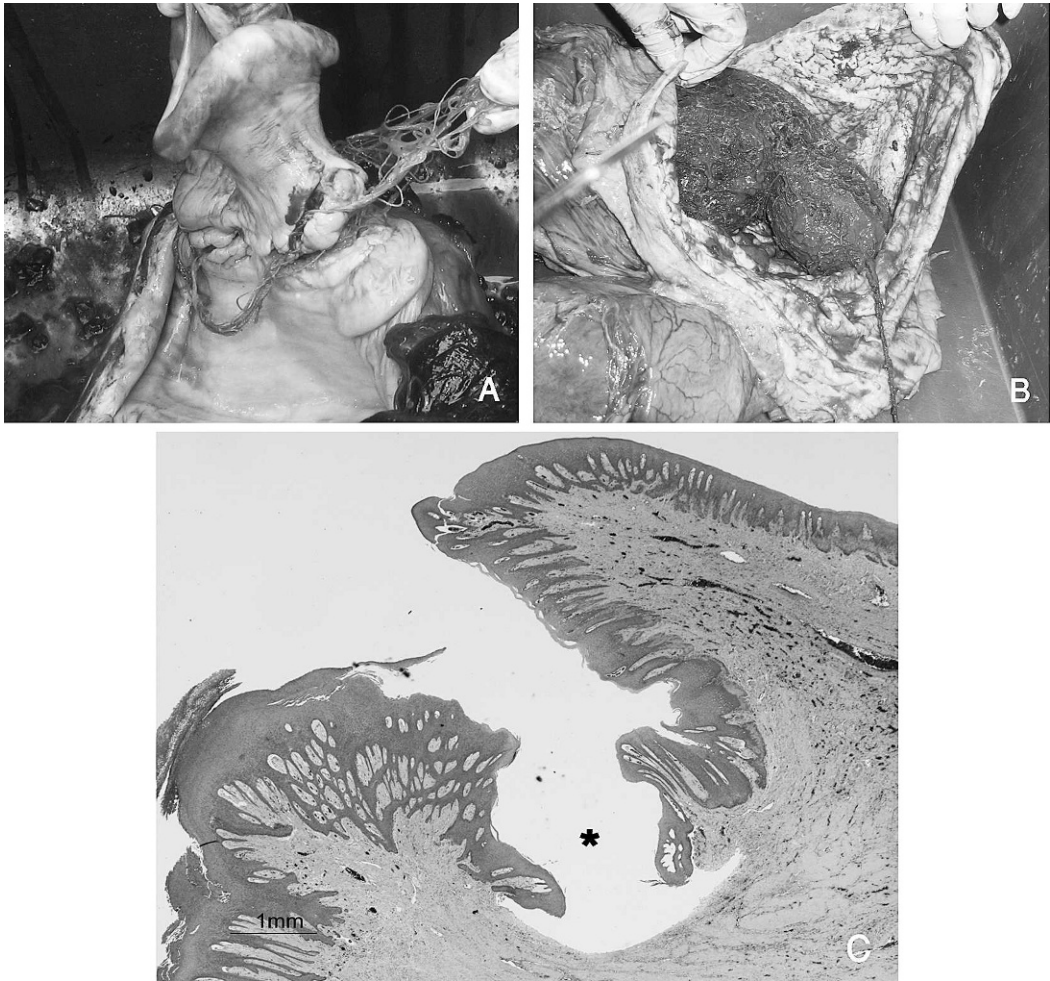


FIGURE 2. Main pathology. A. Macroscopic view of the larynx and the nylon filaments tightly wound around it and within the soft tissue. B. Macroscopic view of the mass of netting in the forestomach. C. Low-power view of the groove (asterisk) flanked by fibrous tissue covered with hyperplastic mucosa. H&E stain. 1X.

most of the net types were not being used by Israeli artisan fishermen.

Histologically, a sample from the caudoventral aspect of the larynx demonstrated a deep groove, flanked by marked submucosal fibrosis and mucosal hyperplasia (Fig. 2C). The deeper aspect of the groove was ulcerated with superficial necrosis; mild, mixed, inflammatory infiltration; and bacteria. The relatively mature fibrous tissue, covered with hyperplastic mucosa, indicated a subacute to chronic course. The lesions in the tongue (Fig. 3A, B) were well-demarcated areas of locally extensive,

coagulative necrosis and ulceration, separated from the surrounding normal tissue by neutrophilic infiltration, accumulation of necrotic cellular debris, and hemorrhage (Fig. 3C). The ulcerated surface was covered by innumerable, Gram-negative, filamentous bacteria admixed with Gram-positive cocci and coccobacilli. Multiple colonies of Gram-negative, filamentous bacteria were also present in the deep tissue (not shown). The pathologic features of the lesions in the tongue are typical of oral necrobacillosis, caused by *Fusobacterium necrophorum*, a Gram-negative, fila-

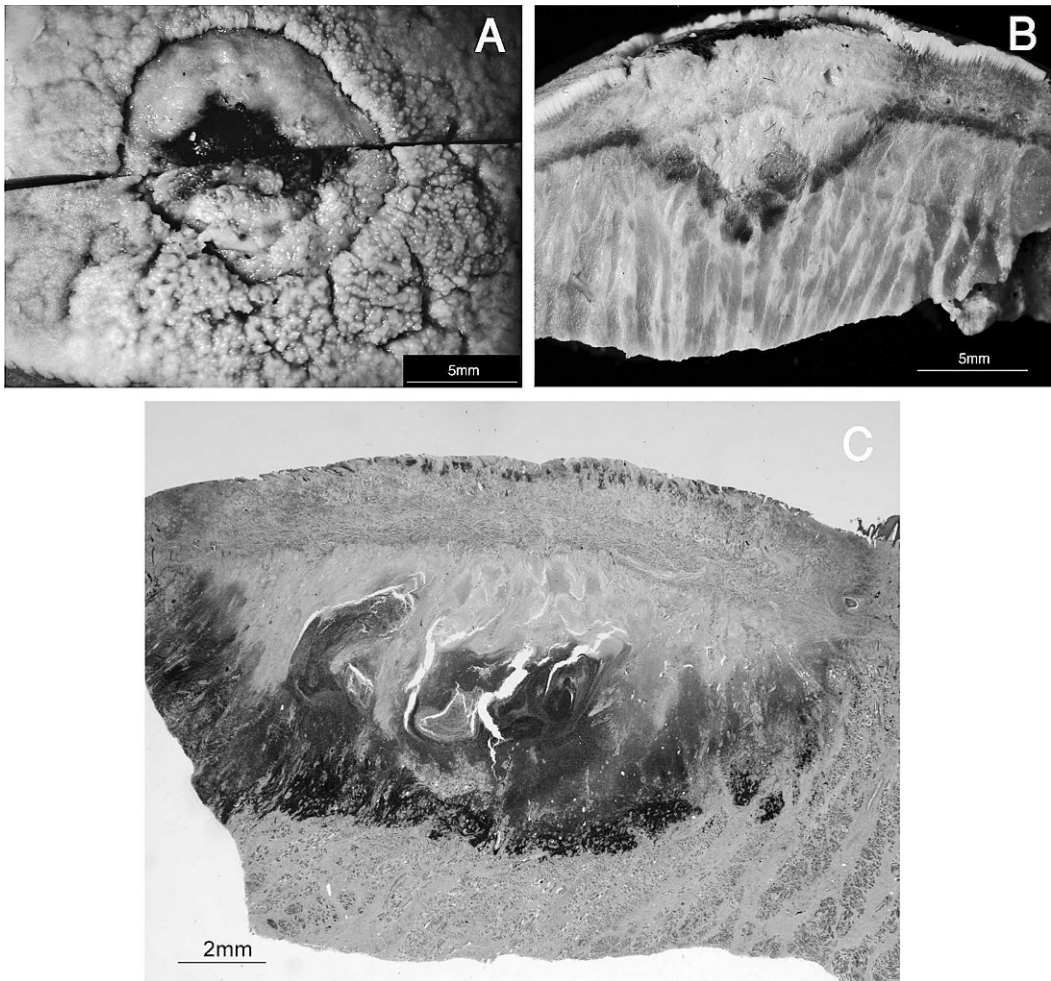


FIGURE 3. Tongue ulcer pathology. A. A close-up view of the macroscopic appearance of the superficial aspect of the lesion in the tongue. There is a well-demarcated focus of necrosis and ulceration. B. The cut surface of the lesion shown in A. In the center, there is a focus of coagulative necrosis (pale) surrounded by a darker band of hemorrhage. C. Low-power view of a histologic section of the lesion shown in B. The central area is pale because of coagulative necrosis. It is separated from the surrounding normal tissue by neutrophilic infiltration, cellular debris, and hemorrhage. H&E stain. 0.5 \times .

mentous anaerobe (Brown et al., 2007). There were no significant findings in the remaining organs examined.

The cetacean larynx protrudes into the glottis up to the soft palate, where it is inserted into the lower (bony) naris and held in place by the palatopharyngeal sphincter (Reidenberg and Laitman, 1987). This arrangement completely separates the respiratory and alimentary tracts from each other, allowing simultaneous swallowing and breathing/vocalizing

without risk of aspiration. Ingestion of hooked fish with attached nylon monofilaments or lures, which get tied around the larynx, is not uncommonly found in common bottlenose dolphins residing in an area with extensive angling and/or long-line fishing activity (Gorzelay, 1988).

The circumstances under which the netting material was ingested by this dolphin are obscure. The wide assortment of net types, and the snagged hooks could either point to a mass of debris that was

balled-up before being ingested (i.e., Secchi and Zarzur, 1999) or, as suggested by the condition of the hooks, that the dolphin was in the habit of wresting prey items from active fishing gear and accumulated the mass over time. Puncture wounds from the fishing hooks may well have been the source of the observed tongue ulcers, as can happen in domestic animals. In cattle and sheep, oral ulcers often result from puncture wounds of thorny fiber or metal, which disrupt the integrity of the oral mucosa (Langworth, 1977; Yeruham and Elad, 2004).

It is likely that feeding and swallowing was impaired in this animal because every contraction of the stomach pulled on the filaments, causing them to cut deeper into the larynx. Judging by its final weight, it must have been severely starved and dehydrated, although its surprising mobility during its last day makes the direct cause of death uncertain.

LITERATURE CITED

- BROWN, C., D. BAKER, AND I. BARKER. 2007. Alimentary system. In Jubb, Kennedy & Palmer's pathology of domestic animals, 5th Edition, M. G. Maxie (ed.). Saunders Ltd., Philadelphia, Pennsylvania, pp. 1–296.
- DERRAIK, J. G. 2002. The pollution of the marine environment by plastic debris: A review. *Marine Pollution Bulletin* 44: 842–852.
- DONOHUE, M. J., R. C. BOLAND, C. M. SRAMEK, AND G. A. ANTONELIS. 2001. Derelict fishing gear in the northwestern Hawaiian Islands: Diving surveys and debris removal in 1999 confirm threat to coral reef ecosystems. *Marine Pollution Bulletin* 42: 1301–1312.
- GORZELANY, J. F. 1988. Unusual deaths of two free-ranging Atlantic bottlenose dolphins (*Tursiops truncatus*) related to ingestion of recreational fishing gear. *Marine Mammal Science* 14: 614–617.
- LAIST, D. W. 1987. Overview of the biological effects of lost and discarded plastic debris in the marine environment. *Marine Pollution Bulletin* 18: 319–326.
- . 1997. Impacts of marine debris: entanglement of marine life in marine debris including a comprehensive list of species with entanglement and ingestion records. In *Marine debris: Sources, impacts, and solutions*, J. M. Coe and D. B. Rogers (eds.). Springer Ltd., New York, New York, pp. 99–139.
- LANGWORTH, B. F. 1977. *Fusobacterium necrophorum*: Its characteristics and role as an animal pathogen. *Bacteriological Reviews* 41: 373–390.
- REIDENBERG, J. S., AND J. T. LAITMAN. 1987. Position of the larynx in Odontoceti (toothed whales). *Anatomical Record* 218: 98–106.
- SECCHI, E. R., AND S. ZARZUR. 1999. Plastic debris ingested by a Blainville's beaked whale, *Mesoplodon densirostris*, washed ashore in Brazil. *Aquatic Mammals* 25: 21–24.
- YERUHAM, I., AND ELAD, D. 2004. Necrotizing stomatitis associated with *Fusobacterium necrophorum* in two goats. *Journal of Veterinary Medicine B* 51: 46–47.

Received for publication 1 April 2008.