



Multiple Congenital Cardiac Abnormalities in an Atlantic Bottlenose Dolphin (*Tursiops truncatus*)

Authors: Powell, James W. B., Archibald, Ryan T., Cross, Cheryl A., Rotstein, David S., Soop, Valerie M., et al.

Source: Journal of Wildlife Diseases, 45(3) : 839-842

Published By: Wildlife Disease Association

URL: <https://doi.org/10.7589/0090-3558-45.3.839>

BioOne Complete (complete.BioOne.org) is a full-text database of 200 subscribed and open-access titles in the biological, ecological, and environmental sciences published by nonprofit societies, associations, museums, institutions, and presses.

Your use of this PDF, the BioOne Complete website, and all posted and associated content indicates your acceptance of BioOne's Terms of Use, available at www.bioone.org/terms-of-use.

Usage of BioOne Complete content is strictly limited to personal, educational, and non - commercial use. Commercial inquiries or rights and permissions requests should be directed to the individual publisher as copyright holder.

BioOne sees sustainable scholarly publishing as an inherently collaborative enterprise connecting authors, nonprofit publishers, academic institutions, research libraries, and research funders in the common goal of maximizing access to critical research.

Multiple Congenital Cardiac Abnormalities in an Atlantic Bottlenose Dolphin (*Tursiops truncatus*)

James W. B. Powell,^{1,7} Ryan T. Archibald,² Cheryl A. Cross,³ David S. Rotstein,^{4,5} Valerie M. Soop,⁶ and Wayne E. McFee¹ ¹National Oceanic and Atmospheric Administration, National Ocean Service, Center for Coastal Environmental Health and Biomolecular Research, 219 Ft. Johnson Road, Charleston, South Carolina 29412, USA; ²University Corporation for Atmospheric Research, 2407 River Drive, Knoxville, Tennessee 37996, USA; ³Center for Wildlife Health, University of Tennessee, 2407 River Drive, Knoxville, Tennessee 37996, USA; ⁴College of Veterinary Medicine, Department of Pathobiology, University of Tennessee, 2407 River Drive, Knoxville, Tennessee 37996, USA; ⁵National Oceanic and Atmospheric Administration, Cooperative Center for Marine Animal Health, 2407 River Drive, Knoxville, Tennessee 37996, USA; ⁶Department of Biology, College of Charleston, 58 Coming Street, Charleston, South Carolina 29401, USA; ⁷Corresponding author (email: james.powell@noaa.gov)

ABSTRACT: Necropsy of an Atlantic bottlenose dolphin (*Tursiops truncatus*) neonate that stranded dead on Folly Beach, Charleston County, South Carolina, USA, on 17 November 2007, revealed multiple congenital heart malformations. Cardiac anomalies included a hypertrophic right ventricle, ventricular septal defect (VSD), aortic dilation, atrial septal defect (ASD) between a functionally common atrium and a left atrial remnant, subvalvular pulmonic stenosis, and a hypoplastic pulmonary artery and mitral valve. Few incidences of abnormal cardiac development in cetaceans have been published. The case study serves to document a novel congenital heart malformation not previously reported, to our knowledge, in free-ranging bottlenose dolphins.

Key words: Atlantic bottlenose dolphin, cardiac anomalies, congenital, heart, malformations, *Tursiops truncatus*.

Other than cardiomyopathy and myocardial degeneration in *Kogia breviceps* and *Kogia sima* (Bossart et al., 2007), few incidences of abnormal cardiac development in cetaceans have been reported. Malformations and congenital anomalies of the heart are rarely observed in Atlantic bottlenose dolphins (*Tursiops truncatus*) or other delphinids. Necropsy of an unborn fetus from a bottlenose dolphin that died in dystocia at Sea-Arama Marineworld in Galveston, Texas, USA, revealed a transposition of the pulmonary artery and aorta, as well as an interventricular foramen (Gray and Conklin, 1974). Persistent ductus arteriosus (PDA), atrial septal defect (ASD), and right ventricular hypertrophy

(RVH) were reported in a captive-born *T. truncatus* that survived for 7 days in a German zoological park (Neurohr, 1982).

On 17 November 2007, a male, 105 cm, 16.8 kg *T. truncatus* stranded, dead, on Folly Beach, Charleston County, South Carolina, USA (32°39'3.24"N, 79°56'51"W). Researchers from the US National Oceanic and Atmospheric Administration (NOAA) Center for Coastal Environmental Health and Biomolecular Research (CCEHBR) in Charleston, South Carolina, USA, conducted a full necropsy according to established protocols (Geraci and Lounsbury, 2005) on the moderately decomposed (code 3) carcass. The carcass exhibited the following characteristics typical of a neonate: Umbilicus was unhealed, dorsal fin and flukes lacked rigidity, teeth were not erupted, and fetal folds were prominent. During necropsy, both lungs were excised and placed in a water bath to determine whether the pulmonary alveoli had expanded. Both lungs floated, thereby demonstrating the stranded dolphin lived at least long enough to breathe.

Gross internal findings included hemorrhagic and moderately congested lungs, hepatic lobular atrophy, multiple splenic infarcts, hydropericardium, and a malformed heart. Congenital cardiac malformations observed included a hypertrophic right ventricle (RVH; Fig. 1), ventricular septal defect (VSD; Fig. 2), aortic dilation,

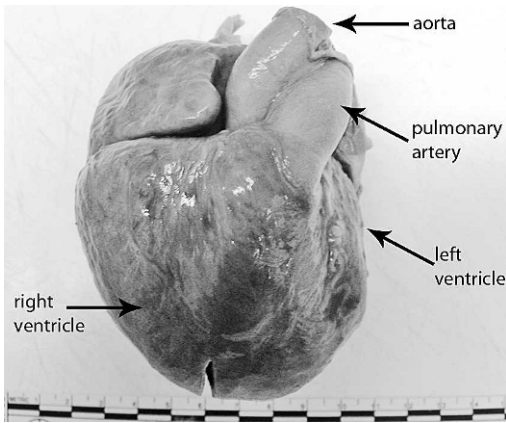


FIGURE 1. Ventral view of heart. Note single (right) atrial appendage and hypertrophic right ventricle.

atrial septal defect (ASD) between a functionally common atrium (Fig. 3) and a left atrial remnant, subvalvular pulmonic stenosis, and a hypoplastic pulmonary artery and mitral valve. There was a 0.5 cm, irregular, round opening connecting the right atrium to the diminutive left atrium. The ventricular septal defect was 1.1 cm wide. The ductus arteriosus, which constricts at or shortly after birth, was closed, and the foramen ovale, an interatrial valve in the fetal heart, was patent, providing supportive evidence of age because previous studies have demonstrat-

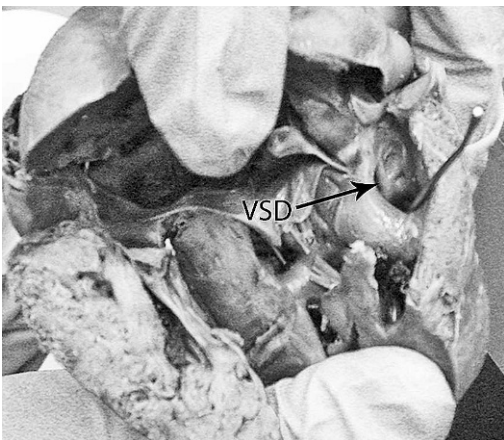


FIGURE 2. There is a 1.1 cm opening between the left and right ventricle (ventricular septal defect).

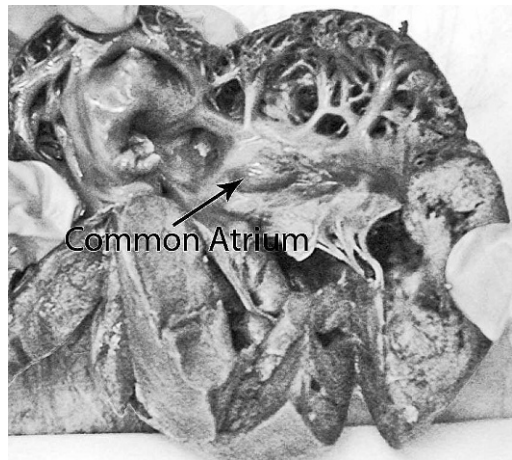


FIGURE 3. There is a common atrium, with the left atrium diminished in size and connected to the right atrium by a 0.5 cm opening.

ed that the postnatal foramen ovale remains open for up to 10 days in the common porpoise (*Phocaena phocaena*) narrowing drastically by 2–3 months, and closing completely in nearly all individuals by 14 mo (Slijper, 1961).

Cardiac measurements were obtained, including ventricular thickness and valvular and vascular circumference. The thickness of the left and right ventricles and interventricular septum was 1.5 cm, 1.0 cm, and 1.0 cm, respectively. The circumference of the left and right atrioventricular valves was 1.0 cm for both regions. The circumference of the aorta was 4.0 cm. The pulmonary artery circumference at three points (subvalvular, valvular, and supra-valvular) was 2.0 cm, 2.4 cm, and 3.0 cm, respectively.

Sections of atria, great vessels, and ventricles were preserved in 10% neutral-buffered formalin, routinely processed, embedded in paraffin, sectioned at 5 μ m, and stained with hematoxylin and eosin. There was cardiomyocyte hypertrophy and random cardiomyocyte disarray. Inflammation was not observed.

Gross external observations included two large, concave areas covered in pox-like lesions located midlaterally, caudal to the left and right pectoral fins. Sections of

the focal, erosive skin lesions had multifocal, hydropic degeneration and spongiosis. Histologic findings were suggestive of poxvirus infection; however, viral inclusion bodies consistent with poxvirus were not evident in examined skin sections. No other notable external findings were observed.

The findings observed in this case do not have an existing correlate in either humans or animals. In humans and domestic species, there are few conditions described that have multiple cardiac and vascular anomalies. One such condition is tetralogy of Fallot, which is characterized by an overriding aorta, an obstruction of right ventricular outflow, ventricular septal defect, and right ventricular hypertrophy. Collectively, these defects cause a reduction of blood flow to the lungs and allow mixing of blood from both sides of the heart, resulting in oxygen-poor blood circulating from the heart to the rest of the body (Anderson and Weinberg, 2005). In humans, congenital cardiac anomalies are not uncommon. Ventricular septal defect alone occurs at a frequency of approximately 11 per 10,000 human births (Cotran et al., 1999).

Causes of congenital cardiac anomalies are typically idiopathic. In humans, poor maternal nutrition, viral illnesses, chromosomal abnormalities, and genetic disorders have been associated with congenital heart anomalies (Borgaonkar 1994; Cotran et al., 1999). Maternally contracted viral infections, specifically rubella, have been implicated in causing numerous malformations, including tetralogy of Fallot (Cotran et al., 1999). Viral studies are not limited to humans. Diseases such as morbillivirus, papillomavirus, and poxvirus are among the most prevalent emerging and resurging diseases in cetaceans (Miller et al., 2001). Effects of specific viral diseases on the developing cetacean heart are unknown. Infectious diseases can be transferred to the calf during different periods of gestation. In humans, regarding all viruses, the gestational age at which maternal infection occurs is critical in determining the effect

on the fetus. For example, the period of greatest risk for rubella infection extends from immediately before conception to the 16th week of pregnancy, drastically reducing with each subsequent trimester (Cotran et al., 1999). Necropsy of a stranded, striped dolphin (*Stenella coeruleoalba*) calf revealed congenital cardiac anomalies similar to those observed in the present case study (Troncone and Zizzo, 1994). The authors noted that the stranding coincided with a period of increased morbillivirus-related cetacean mortalities and suggested that such infectious diseases could hinder or alter normal cardiac development during the first months of gestation.

Other factors that could detrimentally affect fetal cardiac development include transplacental transfer of contaminants. Female bottlenose dolphins and other cetaceans have demonstrated transplacental transfer of toxicants, resulting in an increased level of contaminants in the developing fetus (Salata et al., 1995). Unfortunately, because of the condition of the carcass in this case, contaminant analysis and viral tests were not performed. Conducting comprehensive analyses for potential teratologic agents, such as viruses and toxicants, on stranded cetaceans demonstrating cardiac malformations would provide a better understanding of potential anthropogenic effects on marine mammal prenatal development. The findings from the stranding reported here serve to document a novel congenital heart malformation not previously observed, to our knowledge, in free-ranging bottlenose dolphins.

The authors would like to thank J. Bemiss, P. Fair, and E. Zolman for National Ocean Service internal review and A. Mancina for assistance with translation of references. The research was made possible through NOAA's responsibility under the Marine Mammal Health and Stranding Response Act, Section 109(h) of the Marine Mammal Protection Act as well as a cooperative research agreement with the College of Veterinary Medicine at

the University of Tennessee. This publication does not constitute an endorsement of any commercial product or intend to be an opinion beyond scientific or other results obtained by the National Oceanic and Atmospheric Administration (NOAA). No reference shall be made to NOAA, or this publication furnished by NOAA, to any advertising or sales promotion which would indicate or imply that NOAA recommends or endorses any proprietary product mentioned herein, or which has as its purpose an interest to cause the advertised product to be used or purchased because of this publication.

LITERATURE CITED

- ANDERSON, R. H., AND P. M. WEINBERG. 2005. The clinical anatomy of tetralogy of Fallot. *Cardiology in the Young* 15 (Suppl 1): 38–47.
- BORGAONKAR, D. S. 1994. Chromosomal variation in man: A catalog of chromosomal variants and anomalies, 8th Edition. Wiley-Liss, Inc., New York, New York, 1175 pp.
- BOSSART, G. D., G. HENSLEY, J. D. GOLDSTEIN, K. KROELL, C. A. MANIRE, R. H. DEFRAN, AND J. S. REIF. 2007. Cardiomyopathy and myocardial degeneration in stranded pygmy (*Kogia breviceps*) and dwarf (*Kogia sima*) sperm whales. *Aquatic Mammals* 33: 214–222.
- COTRAN, R. S., V. KUMAR, T. COLLINS, AND S. ROBBINS. 1999. Robbin's pathologic basis of disease. W.B. Saunders Company, Philadelphia, Pennsylvania, 1425 pp.
- GERACI, J. R., AND V. J. LOUNSBURY. 2005. Marine mammals ashore: A field guide for strandings, 2nd Edition. National Aquarium in Baltimore, Baltimore, Maryland, 371 pp.
- GRAY, K. N., AND R. H. CONKLIN. 1974. Multiple births and cardiac anomalies in the bottlenosed dolphin. *Journal of Wildlife Diseases* 10: 155–157.
- MILLER, D. L., R. Y. EWING, AND G. D. BOSSART. 2001. Emerging and resurging diseases. In *CRC Handbook of marine mammal medicine*, L. A. Dierauf and F. M. D. Gulland (eds.). CRC Press, Boca Raton, Florida, pp. 15–19.
- NEUROHR, B. 1982. Herzfehler bei einem große tünmler (*Tursiops truncatus*). *Verhandlungsbericht des International Symposiums uber die Erkarankungen der Zootiere* 24: 55–56.
- SALATA, G. G., T. L. WADE, J. L. SERICANO, J. W. BROOKS, AND J. M. BROOKS. 1995. Analysis of Gulf of Mexico bottlenose dolphins for organochlorine pesticides and PCBs. *Environmental Pollution* 88: 167–175.
- SLIJPER, J. 1961. Foramen ovale and ductus arteriosus Botalli in aquatic mammals. *Mammalia* 25: 528–570.
- TRONCONE, A., AND N. ZIZZO. 1994. Malformazione cardiovascolare in un delfino (*Stenella coeruleoalba*—Meyen 1883). *Obiettivi e Documenti Veterinari* 15: 67–68.

Received for publication 10 April 2008.