

## **Investigation of a Mass Stranding Event Reveals a Novel Pattern of Cascading Comorbidities in Northern Fulmars (*Fulmarus glacialis*)**

Authors: Greenwald, Katherine M., Gible, Corinne M., Miller, Melissa A., Donnelly-Greenan, Erica, and Kudela, Raphael M.

Source: Journal of Wildlife Diseases, 60(1) : 171-178

Published By: Wildlife Disease Association

URL: <https://doi.org/10.7589/JWD-D-23-00008>

---

BioOne Complete ([complete.BioOne.org](https://complete.BioOne.org)) is a full-text database of 200 subscribed and open-access titles in the biological, ecological, and environmental sciences published by nonprofit societies, associations, museums, institutions, and presses.

Your use of this PDF, the BioOne Complete website, and all posted and associated content indicates your acceptance of BioOne's Terms of Use, available at [www.bioone.org/terms-of-use](https://www.bioone.org/terms-of-use).

Usage of BioOne Complete content is strictly limited to personal, educational, and non - commercial use. Commercial inquiries or rights and permissions requests should be directed to the individual publisher as copyright holder.

---

BioOne sees sustainable scholarly publishing as an inherently collaborative enterprise connecting authors, nonprofit publishers, academic institutions, research libraries, and research funders in the common goal of maximizing access to critical research.

## Investigation of a Mass Stranding Event Reveals a Novel Pattern of Cascading Comorbidities in Northern Fulmars (*Fulmarus glacialis*)

Katherine M. Greenwald,<sup>1,4,6</sup> Corinne M. Gible,<sup>1,6</sup> Melissa A. Miller,<sup>1</sup> Erica Donnelly-Greenan,<sup>2,5</sup> and Raphael M. Kudela<sup>3</sup> <sup>1</sup>California Department of Fish and Wildlife, Office of Spill Prevention and Response, Marine Wildlife Veterinary Care and Research Center, 151 McAllister Way, Santa Cruz, California 95060, USA; <sup>2</sup>Moss Landing Marine Laboratories, 8272 Moss Landing Rd., Moss Landing, California 95039, USA; <sup>3</sup>University of California Santa Cruz, 1156 High St., Santa Cruz, California 95064, USA; <sup>4</sup>Current address: California Energy Commission, 1516 9th St, Sacramento, California 95814 USA; <sup>5</sup>Current address: Save Our Shores, 345 Lake Ave., Suite A, Santa Cruz, California 95062, USA; <sup>6</sup>Corresponding authors: (email: katherine.greenwald@energy.ca.gov; corinne.gible@wildlife.ca.gov)

**ABSTRACT:** During 2018, a seabird mortality event occurred in central California, US, that affected Northern Fulmars (*Fulmarus glacialis*), Common Murres (*Uria aalge*), and Cassin's Auklets (*Ptychoramphus aleuticus*). An increase in beachcast birds were reported on standardized surveys in conjunction with an increased number of live-stranded birds admitted to rehabilitation centers. Neurologic symptoms were noted during intake examination for some birds. Coincident with the mortality event, increased levels of the harmful algal bloom toxins domoic acid and saxitoxin were recorded in Monterey Bay and Morro Bay. Birds that died in care and beachcast carcasses were submitted to the California Department of Fish and Wildlife–Marine Wildlife Veterinary Care and Research Center for postmortem examination ( $n=24$ ). All examined birds were emaciated. Examined Common Murres and Cassin's Auklets had no gross evidence of preexisting disease; however, all examined Northern Fulmars exhibited severe pyogranulomatous inflammation of the urogenital system at gross postmortem exam. Tissues from nine Northern Fulmars were examined by histopathology, and samples from two Northern Fulmars were tested for the presence of domoic acid and saxitoxin. Histopathology revealed moderate to severe kidney infection by *Eimeria* sp. and gram-negative bacteria, intratubular urate stasis, ureter rupture, and emaciation. Additionally, domoic acid and saxitoxin were detected simultaneously in tissues of some tested birds. This communication highlights a novel pattern of cascading comorbidities in native seabirds from a mass stranding event.

**Key words:** Bacterial infection, domoic acid, *Eimeria*, harmful algal blooms, pyogranulomatous nephritis, renal coccidia, saxitoxin, seabirds.

During February and early March 2018, numerous live-stranded birds entered two wildlife care centers: The Society for the Prevention of Cruelty to Animals for Monterey (MSPCA) in Monterey County, California, US, and Pacific

Wildlife Care (PWC) in San Luis Obispo County, California, US. Affected species included Northern Fulmars (*Fulmarus glacialis*), Common Murres (*Uria aalge*), and Cassin's Auklets (*Ptychoramphus aleuticus*). Some birds entering rehabilitative care exhibited opisthotonos, seizures, paresis, and ambulatory or locomotor deficits. Concurrent with this increased intake of live, sick birds, the Coastal Ocean Mammal and Bird Education and Research Surveys (BeachCOMBERS) program reported increased deposition of dead Common Murres, Northern Fulmars, and Cassin's Auklets on Monterey and San Luis Obispo County beaches. Blooms of toxigenic phytoplankton (*Pseudo-nitzschia* spp. and *Alexandrium* spp.) occurred in the same coastal regions (Monterey Bay and Morro Bay, California; R. Kudela pers. comm.) coincident with this mortality event. The counties in which birds were found is shown in Figure 1.

Birds that died ( $n=4$ ) or were euthanized ( $n=4$ ) in rehabilitative care plus beachcast carcasses collected by biologists at the Oceano Dunes State Vehicular Recreation Area, California, ( $n=16$ ) were submitted to the California Department of Fish and Wildlife–Marine Wildlife Veterinary Care and Research Center, Santa Cruz, California, US. These 24 necropsied birds (Northern Fulmars,  $n=16$ ; Cassin's Auklets,  $n=4$ ; Common Murres,  $n=4$ ; Table 1) were from Monterey and San Luis Obispo counties. Histopathology was performed for selected Northern Fulmars only ( $n=7/24$ ); tissues were fixed in 10% neutral buffered formalin, processed as described (Batac et al. 2020) and stained with H&E. Selected tissues were analyzed with Brown and Brenn stains to assess the characteristics of

CALIFORNIA

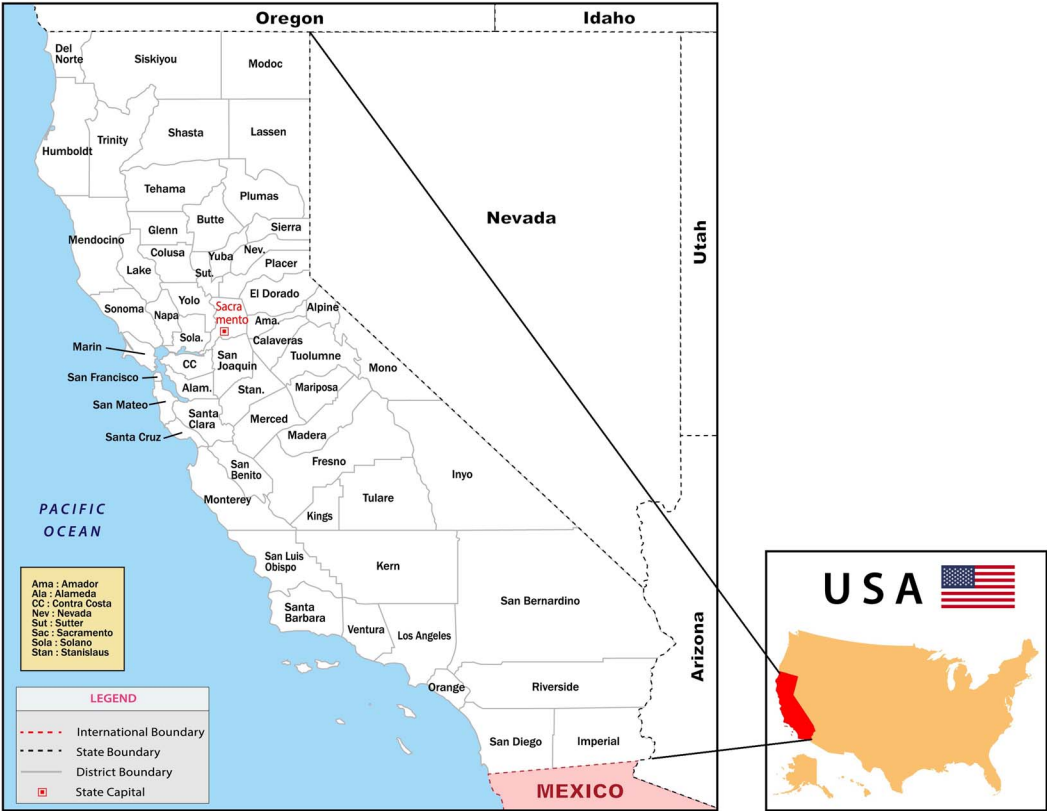


FIGURE 1. Map showing the counties within the state of California, USA; Northern Fulmars (*Fulmarus glacialis*), Common Murres (*Uria aalge*), and Cassin’s Auklets (*Ptychoramphus aleuticus*) were recovered in the coastal areas of Santa Cruz, Monterey, and San Luis Obispo counties during a 2018 mortality event.

intralesional bacteria revealed by Gram staining.

The occurrence of an avian mass stranding event coincident with blooms of toxigenic phytoplankton prompted biochemical assessment of liver and kidney from stranded birds for the harmful algal bloom (HAB) toxins domoic acid (DA;  $n=8$ ) and saxitoxin (STX;  $n=8$ ) for four birds (two Common Murres and Northern Fulmars each; Table 2) at the University of California, Santa Cruz. Samples for biotoxin assessment were held at  $-20\text{ }^{\circ}\text{C}$  until processed, when 0.1–1.5 g of tissue was extracted in 50% methanol, cleaned with ISOLUTE SAX SPE columns (Biotage, Uppsala, Sweden) as described by Peacock et al. (2018), and analyzed with an Agilent 6130 liquid chromatography–mass spectrometry

system (Agilent Technologies, Santa Clara, California, USA) and a Phenomenex Kinetex 2.6- $\mu\text{m}$  100  $\times$  2.1-mm C18 column (Phenomenex, Torrance, California, USA). Domoic acid was quantified by peak area and retention time with the use of an external standard curve with Nuclear Regulatory Commission single-bond Canadian certified reference materials. Sample subsets were analyzed after standard addition of Nuclear Regulatory Commission single-bond Certified Reference Material DA to confirm peak identity and check for matrix effects. The method detection limit (MDL) was 0.30 ng/g for 1 g of tissue, with the MDL for specific samples dependent on sample weight.

Samples assessed for STX were processed following the mussel extraction protocol provided

TABLE 1. Seabirds examined during February and March 2018 from the Central California Coast, USA. Birds were determined to be unknown in sex or age class when the carcass was too decomposed for designation at gross postmortem examination.<sup>a</sup>

MWVCRC ID	Species <sup>b</sup>	Date collected	Location	Age class <sup>c</sup>	Sex	Histopathology	HAB test
18-0025	COMU	2/10/2018	Monterey Bay	JUV	Male	No	Yes
18-0026	COMU	2/12/2018	Monterey Bay	JUV	Male	No	Yes
18-0088	NOFU	2/10/2018	Oceano	JUV	Male	Yes	Yes
18-0089	NOFU	2/6/2018	Oceano	JUV	Female	No	No
18-0090	NOFU	2/9/2018	Oceano	UNK	UNK	No	No
18-0091	NOFU	2/10/2018	Oceano	JUV	Female	Yes	Yes
18-0092	NOFU	2/10/2018	Oceano	UNK	UNK	No	No
18-0093	NOFU	2/8/2018	Oceano	UNK	UNK	No	No
18-0094	NOFU	2/7/2018	Oceano	JUV	Male	No	No
18-0095	NOFU	2/9/2018	Oceano	UNK	UNK	No	No
18-0096	CAAU	2/10/2018	Oceano	AD	Female	No	No
18-0097	CAAU	2/10/2018	Oceano	UNK	UNK	No	No
18-0098	CAAU	2/10/2018	Oceano	UNK	UNK	No	No
18-0234	NOFU	2/21/2018	Monterey Bay	AD	Male	Yes	No
18-0235	NOFU	2/21/2020	Monterey Bay	JUV	Female	Yes	No
18-0236	NOFU	2/20/2018	Monterey Bay	JUV	Female	Yes	No
18-0237	NOFU	3/1/2018	Morro Bay	JUV	Female	Yes	No
18-0238	NOFU	3/2/2018	Morro Bay	JUV	Female	Yes	No
18-0239	NOFU	3/15/2018	Oceano	UNK	UNK	No	No
18-0240	NOFU	3/15/2018	Oceano	JUV	Male	No	No
18-0242	NOFU	3/21/2018	Oceano	JUV	Male	No	No
18-0243	COMU	2/9/2018	Oceano	AD	UNK	No	No
18-0244	CAAU	2/9/2018	Oceano	AD	Female	No	No
18-0245	COMU	2/20/2018	Monterey Bay	JUV	Male	No	No

<sup>a</sup> MWVCRC = Marine Wildlife Veterinary Care and Research Center (Santa Cruz, California, USA); HAB = harmful algal bloom.  
<sup>b</sup> COMU = Common Murre (*Uria aalge*); NOFU = Northern Fulmar (*Fulmarus glacialis*); CAAU = Cassin's Auklet (*Ptychoramphus aleuticus*).  
<sup>c</sup> JUV = juvenile; UNK = unknown; AD = adult.

by the manufacturer, with extracts stored at 4 C up to 1 wk, then diluted with diluent provided by Bioo Scientific and analyzed via the MaxSignal Saxitoxin (PSP) ELISA test kit (Bioo Scientific, Austin, Texas, USA). All samples, standards, and controls were plated in duplicate. A standard curve was fitted with a five-parameter logistic curve model and standard curve manufacturer-supplied matrix standards, per manufacturer protocols by the software provided with the plate reader (SoftMax Pro v5, Molecular Devices, San Jose, California, USA). The working range was determined by I20 and I80 values from the calibration curve to minimize errors in quantifying the signal. The I20 and I80 values are where 20% and 80% inhibition of the signal, respectively, is achieved; areas below and above those values are long tails in the curve, making for large errors in results.

All values over I80 were considered above the MDL, and values less than I20 were diluted further and rerun for accuracy. The MDL was 3.00 ng/g for 1 g of tissue; MDLs for individual samples varied by sample weight.

At postmortem examination, all Common Murres, Cassin's Auklets, and Northern Fulmars except individual 18-0235 were emaciated, with total depletion of subcutaneous and internal adipose, diffuse marked muscle atrophy, and empty gastrointestinal tracts (except animals fed while in care). All birds also had intestinal melena, indicative of prolonged stress (Selye 1973; Gelis 2005). Other than emaciation and melena, examined Cassin's Auklets and Common Murres had

TABLE 2. Domoic acid (DA) and saxitoxin (STX) results for representative seabirds examined during February and March 2018 from the Central California Coast, USA. The DA and STX results are also described in Gobble et al. (2021) with analytical details.

MWVCRC <sup>a</sup> ID	Species <sup>b</sup>	Tissue	DA (ng/g) <sup>c</sup>	STX (ng/g) <sup>c</sup>
18-0025	COMU	Liver	4.907	Low
	COMU	Kidney	20.973	Low
18-0026	COMU	Liver	0.000	Low
	COMU	Kidney	20.546	4.868
18-0088	NOFU	Liver	Low	6.870
	NOFU	Kidney	Low	8.831
18-0091	NOFU	Liver	Low	20.946
	NOFU	Kidney	5.551	9.634

<sup>a</sup> Marine Wildlife Veterinary Care and Research Center (Santa Cruz, California, USA).

<sup>b</sup> COMU = Common Murre (*Uria aalge*); NOFU = Northern Fulmar (*Fulmarus glacialis*).

<sup>c</sup> Low is below the minimum detection limit (4 ng/g) but not considered nondetected.

no significant gross pathology other than moderate diffuse congestion and jugular vein distension and enlarged adrenal glands for two Common Murres that stranded early in the event (individuals 18-0025 and 18-0026).

In contrast, all examined Northern Fulmars ( $n=16$ ) had grossly apparent renal, ureteral, and cloacal pyogranulomas (Fig. 2). Affected ureters were distended and plugged by pale yellow to tan friable material, in some cases

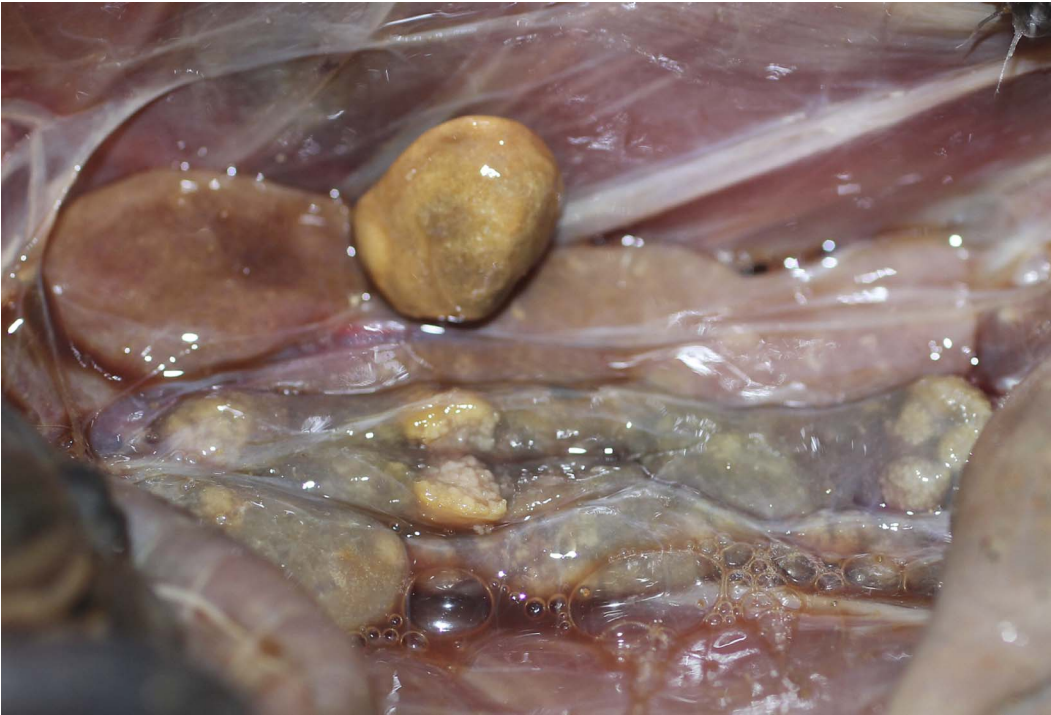


FIGURE 2. Gross pathology of urogenital system in frozen-thawed Northern Fulmars (*Fulmarus glacialis*) from a 2018 mortality event in central California, USA, showing multifocal irregular yellow-tan pyogranulomas in renal parenchyma and within markedly dilated, debris-filled ureters and the cloaca.



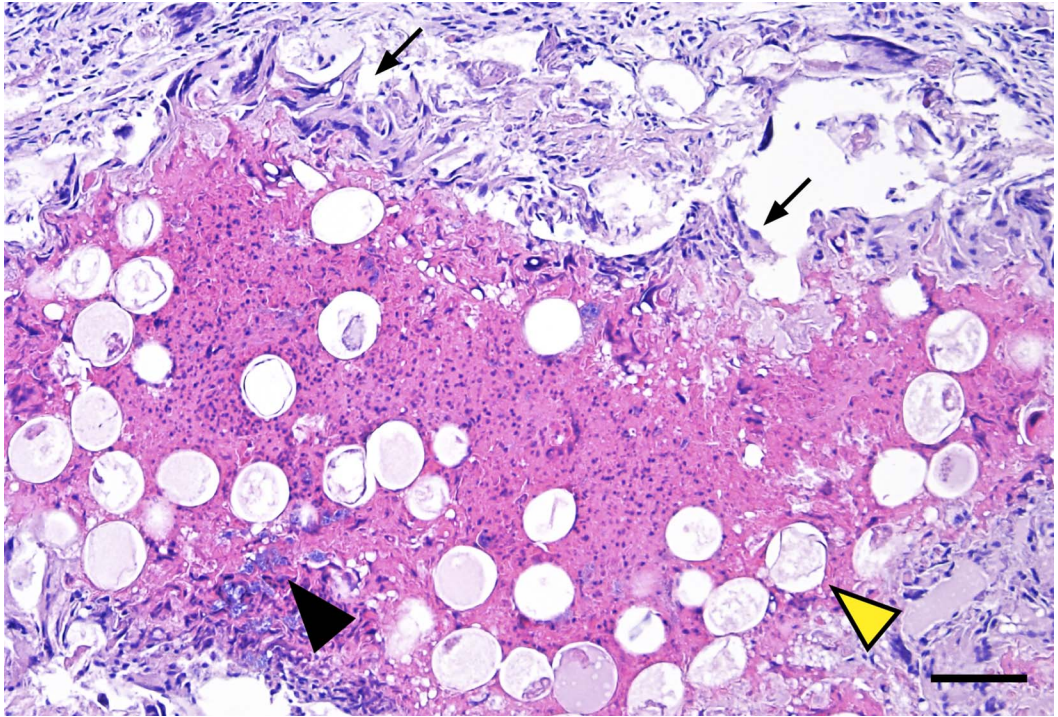


FIGURE 3. Parasite- and bacteria-associated renal histopathology in frozen-thawed Northern Fulmars (*Fulmarus glacialis*) from a 2018 mortality event in central California, USA. A medullary collecting duct is effaced and obstructed by pyogranulomatous inflammation with intraluminal clusters of bacterial rods (black arrowhead) and admixed *Eimeria* sp. oocysts (yellow arrowhead). The duct is partially ulcerated, with the lining epithelium replaced by a thick outer band of multinucleated giant cells (slender black arrows). H&E stain. Bar=45  $\mu$ m.

with secondary ureter rupture. Microscopic examination revealed severe pyogranulomatous and necrotizing pyelonephritis with intraepithelial protozoal macro- and microgamonts, schizonts, and luminal oocysts (Figs. 3, 4). Also present were intraluminal clusters of gram-negative bacterial rods, inspissated masses of necrotic epithelium and urate crystals, and perilesional multinucleated giant cells. On the basis of parasite morphology, size, and location, the protozoan was identified as *Eimeria* sp. The *Eimeria* sp. infection (i.e., renal coccidiosis or eimeriosis) was associated with epithelial hypertrophy, necrosis, sloughing, and partial obstruction and dilation of the collecting ducts and ureters (Fig. 3). Gram-negative bacterial proliferation (pyelonephritis) exacerbated this damage and further impaired renal and ureteral clearance, compounded by intraluminal urate deposition from dehydration.

Biochemical test results provided additional insight. Domoic acid (0.00–20.973 ng/g) was detected in seven of eight samples (88%) from all four tested birds (Table 2). Saxitoxin (>MDL–20.946) was also detected in all eight samples from the four birds (Table 2). Domoic acid and STX were detected concurrently in 3/4 (75%), and 7/8 samples (88%; Table 2).

Wildlife health is often multifactorial, and fully understanding the related ecology of a mortality event requires significant resources. On the basis of all findings from postmortem examination and biochemical testing, all Common Murre and Cassin's Auklet deaths were attributed to emaciation, with HAB intoxication a potential contributing factor. Mortality events for seabirds attributed to emaciation are quite common, and prey availability and timing of food resources, adverse or extreme weather events, and other environmental anomalies

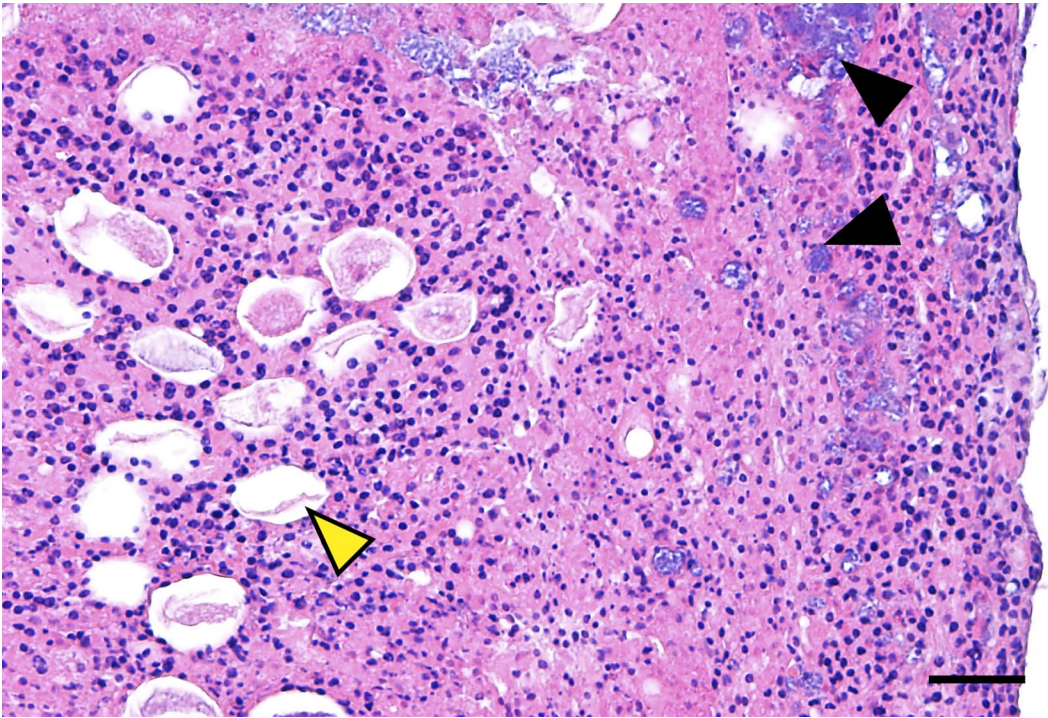


FIGURE 4. Parasite- and bacteria-associated pathology of caseonecrotic material from an obstructed and ruptured ureter in a Northern Fulmar (*Fulmarus glacialis*) from a 2018 mortality event in central California, USA, showing that the densely packed material is composed of numerous eosinophils and heterophils, necrotic cell debris, clusters of bacterial rods (black arrowhead), and admixed *Eimeria* sp. oocysts (yellow arrowhead). H&E stain. Bar=30  $\mu$ m.

may all contribute to these events (Newman et al. 2007, 2009; Jones et al. 2019; Diamond et al. 2020; Piatt et al. 2020), and findings of emaciation concurrent with secondary HAB interactions are consistent with other documented seabird wrecks (Gibble et al. 2018; Piatt et al. 2020; Van Hemert et al. 2020). In contrast, the Northern Fulmars were affected by multiple concurrent processes, including renal coccidiosis, bacterial pyelonephritis, dehydration with urate stasis, ureteral rupture, and emaciation. Although unconfirmed, concurrent HAB toxin exposure may have reduced the Northern Fulmars' resistance to renal coccidiosis, bacterial infection, or both. Emaciation also may have played a role by affecting resistance both to HAB exposure and to the infectious agents.

*Eimeria* spp.-associated renal coccidiosis has been reported from many avian genera (Nation and Wobeser 1977; Tuggle and Crites 1984; Leighton and Gajadhar 1986; Gajadhar

and Leighton 1988; Yabsley et al. 2002). Pathogenicity varies from incidental infection to mass mortality due to parasite-associated nephropathy, characterized by epithelial hyperplasia, necrosis, sloughing, and tubular dilation (Tuggle and Crites 1984; Leighton and Gajadhar 1986; Yabsley et al. 2002; Morgan et al. 2013; Jankovsky et al. 2017). *Eimeria* spp. are the usual cause; these parasites are often taxon-specific and include many undescribed species. Infection occurs by consumption of sporocysts or sporulated oocysts shed in the urate fraction of avian feces. Parasites transmitted through oral-fecal exposure may be especially problematic for birds that are highly stressed by migration or use of crowded breeding and foraging areas (Rifkin et al. 2012). Biotxin exposure may cause fatal intoxication or worsen the health effects from opportunistic parasites and bacteria.

Although fatal avian toxicosis has been reported, and lethal HAB doses have been



established experimentally for avian exposure to DA and STX, pathophysiologic and pharmacodynamic associations are underevaluated (Shumway et al. 2003; Gible et al. 2021). Dusek et al. (2021) estimated the median oral lethal dose (LD<sub>50</sub>) of STX in mallards (*Anas platyrhynchos*) as 167 µg/kg, and Silvagni (2003) established the intracoelomic LD<sub>50</sub> for DA as 900 µg/kg for pigeons (*Columba livia*), 4,000 µg/kg in mallards, and 4,100 µg/kg in Common Murres. However, intracoelomic toxin administration is not necessarily comparable to oral exposure. Although our DA and STX values (Table 2) are below the reported LD<sub>50</sub> for both toxins, they represent a single perimortem snapshot that does not account for rapid postexposure toxin clearance. Additionally, Silvagni (2003) demonstrated that LD<sub>50</sub> values can vary widely between avian species, and potential synergistic effects between HAB toxins and opportunistic pathogens are uncharacterized.

Our finding of concurrent renal coccidiosis, bacterial pyelonephritis, and HAB toxin exposure in Northern Fulmars illustrates how cascading comorbidities may exacerbate avian losses during mortality events. This compounding effect often underlies the detrimental effects of environmental degradation on seabird health. Although concurrent emaciation and DA intoxication have been noted previously during an avian mortality event (Gible et al. 2018, 2021), emaciated birds are often not tested for HAB exposure because of the cost and limited laboratory availability and because the toxins are relatively ephemeral in avian tissues and gastrointestinal samples are often unavailable. However, recent studies demonstrating consistent HAB toxin detection in avian tissues (Van Hemert et al. 2020; Gible et al. 2021) confirm the value of tissue screening for emaciated birds from mass strandings that coincide with HAB events. Without this testing, population-level HAB effects, risks from chronic sublethal toxin exposure and HAB-pathogen synergy, and emerging seabird health effects are likely to be missed. Continued investigation of mortality events is critical to optimize the collective understanding of coexisting threats for wild-life populations.

We thank all the staff and volunteers at The Society for the Prevention of Cruelty to Animals

for Monterey, Pacific Wildlife Care, and Coastal Ocean Mammal and Bird Education and Research Surveys for their efforts to recover and document stranded seabirds. We also thank Jessie Beck for assistance with postmortem examinations, Kendra Negrey for University of California Santa Cruz Laboratory support, Chris Gardiner for parasite identification guidance, and Angelina Reed for final image formatting.

## LITERATURE CITED

- Batac FI, Miller MA, Moriarty ME, Shen Z, Fox JG, Ottemann KM. 2020. *Helicobacter* spp. in necropsied southern sea otters (*Enhydra lutris nereis*) is associated with gastric ulcers and sensitive to multiple antibiotics. *Front Mar Sci* 7:413.
- Diamond AW, McNair DB, Ellis JC, Rail JF, Whidden ES, Kratter AW, Courchesne SJ, Pokras MA, Wilhelm SI, et al. 2020. Two unprecedented auk wrecks in the northwest Atlantic in winter 2012/13. *Mar Ornithol* 48:185–204.
- Dusek RJ, Smith MM, Van Hemert C, Shearn-Bochsler VI, Hall S, Ridge CD, Hardison DR, Kaler RSA, Bodenstein BL, et al. 2021. Acute oral toxicity and tissue residues of saxitoxin in the mallard (*Anas platyrhynchos*). *Harmful Algae* 109:102109.
- Gajadhar AA, Leighton FA. 1988. *Eimeria wobeseri* sp. n. and *Eimeria goelandi* sp. n. (Protozoa: Apicomplexa) in the kidneys of herring gulls (*Larus argentatus*). *J Wildl Dis* 24:538–546.
- Gelis S. 2005. Evaluating and treating the gastrointestinal system. In: *Clinical avian medicine*, Harrison G, Lightfoot T, editors. Spix Publishing Inc., Palm Beach, Florida, pp. 411–440.
- Gible C, Duerr R, Bodenstein B, Lindquist K, Lindsey J, Beck J, Henkel L, Roletto J, Harvey J, Kudela R. 2018. Investigation of a largescale common murre (*Uria aalge*) mortality event in California, USA, in 2015. *J Wildl Dis* 54:569–574.
- Gible CM, Kudela RM, Knowles S, Bodenstein B, Lefebvre KA. 2021. Domoic acid and saxitoxin in seabirds in the United States between 2007 and 2018. *Harmful Algae* 103:101981.
- Jankovsky JM, Brand M, Gerhold RW. 2017. Identification of a novel renal coccidian (Apicomplexa: *Eimeriidae*) from the great-horned owl (*Bubo virginianus*), USA. *J Wildl Dis* 53:368–371.
- Jones T, Divine LM, Renner H, Knowles S, Lefebvre KA, Burgess HK, Wright C, Parrish JK. 2019. Unusual mortality of Tufted puffins (*Fratercula cirrhata*) in the eastern Bering Sea. *PloS One* 14:e0216532.
- Leighton FA, Gajadhar AA. 1986. *Eimeria fraterculae* sp. n. in the kidneys of Atlantic puffins (*Fratercula arctica*) from Newfoundland, Canada: Species description and lesions. *J Wildl Dis* 22:520–526.
- Morgan KJ, Alley MR, Pomroy WE, Gartrell BD, Castro I, Howe L. 2013. Extra-intestinal coccidiosis in the kiwi (*Apteryx* spp.). *Avian Pathol* 42:137–146.



- Nation PN, Wobeser, G. 1977. Renal coccidiosis in wild ducks in Saskatchewan. *J Wildl Dis* 13:370–375.
- Newman SH, Chmura A, Converse K, Kilpatrick AM, Patel N, Lammers E, Daszak P. 2007. Aquatic bird disease and mortality as an indicator of changing ecosystem health. *Mar Ecol Prog Ser* 352:299–309.
- Newton KM, Croll DA, Nevins HM, Benson SR, Harvey JT, Tershy BR. 2009. At-sea mortality of seabirds based on beachcast and offshore surveys. *Mar Ecol Prog Ser* 392:295–305.
- Peacock MB, Gobble CM, Senn DB, Cloern JE, Kudela RM. 2018. Blurred lines: Multiple freshwater and marine algal toxins at the land-sea interface of San Francisco Bay, California. *Harmful Algae* 73:138–147.
- Piatt JF, Parrish JK, Renner HM, Schoen SK, Jones TT, Arimitsu ML, Kuletz KJ, Bodenstein B, García-Reyes M, et al. 2020. Extreme mortality and reproductive failure of common murrelets resulting from the northeast Pacific marine heatwave of 2014–2016. *PLoS One* 15:e0226087.
- Rifkin JL, Nunn CL, Garamszegi LZ. 2012. Do animals living in larger groups experience greater parasitism? A meta-analysis. *Am Nat* 180:70–82.
- Selye H. 1973. The evolution of the stress concept. *Am Sci* 61:692–699.
- Shumway SE, Allen SM, Boersma PD. 2003. Marine birds and harmful algal blooms: Sporadic victims or under-reported events? *Harmful Algae* 2:1–17.
- Silvagni PA. 2003. *Comparative pathology and diagnosis of domoic acid toxicity*. PhD Dissertation, University of California, Davis, California, 139 pp.
- Tuggle BN, Crites JL. 1984. Renal coccidiosis in interior Canada Geese, *Branta canadensis* interior Todd, of the Mississippi Valley population. *J Wildl Dis* 20:272–278.
- Van Hemert C, Schoen SK, Litaker RW, Smith MM, Arimitsu ML, Piatt JF, Holland WC, Hardison DR, Pearce JM. 2020. Algal toxins in Alaskan seabirds: Evaluating the role of saxitoxin and domoic acid in a large-scale die-off of Common Murres. *Harmful Algae* 92:101730.
- Yabsley MJ, Gottdenker NL, Fischer JR. 2002. Description of a new *Eimeria* sp. and associated lesions in the kidneys of double-crested cormorants (*Phalacrocorax auritus*). *J Parasitol* 88:1230–1233.

Submitted for publication 12 January 2023.

Accepted 6 September 2023.