

Otodectic Otoacariasis in Free-Ranging Eurasian Lynx in Sweden

Authors: Degiorgis, Marie-Pierre, Hård af Segerstad, Carl, Christensson, Bodil, and Mörner, Torsten

Source: Journal of Wildlife Diseases, 37(3) : 626-629

Published By: Wildlife Disease Association

URL: <https://doi.org/10.7589/0090-3558-37.3.626>

BioOne Complete (complete.BioOne.org) is a full-text database of 200 subscribed and open-access titles in the biological, ecological, and environmental sciences published by nonprofit societies, associations, museums, institutions, and presses.

Your use of this PDF, the BioOne Complete website, and all posted and associated content indicates your acceptance of BioOne's Terms of Use, available at www.bioone.org/terms-of-use.

Usage of BioOne Complete content is strictly limited to personal, educational, and non - commercial use. Commercial inquiries or rights and permissions requests should be directed to the individual publisher as copyright holder.

BioOne sees sustainable scholarly publishing as an inherently collaborative enterprise connecting authors, nonprofit publishers, academic institutions, research libraries, and research funders in the common goal of maximizing access to critical research.

Otodectic Otoacariasis in Free-Ranging Eurasian Lynx in Sweden

Marie-Pierre Degiorgis,^{1,4} Carl Hård af Segerstad,² Bodil Christensson,³ and Torsten Mörner¹ ¹ Department of Wildlife, National Veterinary Institute, S-751 89 Uppsala, Sweden; ² Department of Pathology, National Veterinary Institute, S-751 89 Uppsala, Sweden; ³ Department of Parasitology, National Veterinary Institute, S-751 89 Uppsala, Sweden; ⁴ Corresponding author (e-mail: mpdegiorgis@swissonline.ch).

ABSTRACT: An infestation with *Otodectes cynotis*, the ear mite of cats and dogs, was observed in three free-ranging Eurasian lynx (*Lynx lynx*) killed in Sweden. The ear canals were obstructed by waxy secretions and exfoliated epithelium. Histologically, there were hyperkeratosis and acanthosis, and the epithelial surface was overlain by hyperkeratotic and parakeratotic crusts with mites, mite detritus and cerumen. In the subcutis there was a slight to moderate infiltration of lymphocytes and macrophages. The ceruminous glands were hypertrophic and hyperplastic, and there was also an hyperplasia of the sebaceous glands. The lesions seemed to correlate with the degree of infestation. To our knowledge, this is the first report of otoacariasis in free-ranging lynx.

Key words: Case report, ear mange, *Lynx lynx*, otoacariasis, *Otodectes cynotis*.

The ear mite *Otodectes cynotis* is the most common parasite affecting the ear canals of domestic dogs and cats and is responsible for producing “ear mange” in these species (Berg and Shomer, 1963). The mite also may cause lesions on contact with humans (Van den Broek and Thoday, 1994). *Otodectes cynotis* is an obligate, relatively large, non-burrowing mite and the commonest cause of otitis externa in cats, especially kittens. Occasionally it causes cutaneous lesions elsewhere, notably on the head, interscapular area, base of the tail and paws (Van den Broek and Thoday, 1994) which are associated with varying degrees of pruritus. *Otodectes cynotis* has been described as a common parasite of captive wild felids (Fowler, 1986; Behlert, 1995). However, to our knowledge this is the first report in the Eurasian lynx (*Lynx lynx*).

The Eurasian lynx is found in most parts of Sweden, and in 1998 the population was estimated to be about 1,500 (Swedish Hunter's Association, pers. comm.). After 4 yr of full protection, the Swedish lynx

population has been hunted since 1995. The main disease affecting lynx in Sweden is sarcoptic mange, caused by the itch mite *Sarcoptes scabiei*. The first case was observed in 1980, 10 yr after the start of a dramatic epidemic in the red fox (*Vulpes vulpes*), and this disease was suspected to be an important factor in the decrease of the lynx population during the following decade (Mörner, 1992). These findings lead to an interdisciplinary research project about diseases and other causes of mortality in lynx in Sweden. Therefore, lynx carcasses are systematically submitted to the National Veterinary Institute (SVA, Uppsala, Sweden) for necropsy, and their pelts (if present) carefully examined for the presence of mites.

A free-ranging female lynx was shot by a hunter on 15 February 1999 in the county of Dalarna, Sweden (60°45'N, 14°45'E). The body of the skinned animal was submitted within two days to SVA for a standard complete necropsy. The 14 kg female was determined to be 1-yr-old by counting cementum annuli of a canine tooth (conducted by Matson's Laboratory, Milltown, Montana, USA). It was in a poor body condition. The left ear canal was obstructed with dark hard secretions; in the right ear, the canal was filled with a crumbly, light brown material. The shot had caused numerous traumatic lesions in the head and thorax. In the lungs, there were multiple foci of endogenous lipid pneumonia, which is known to be a common finding in domestic cats (Dungworth, 1993).

On 11 July 1999, a male lynx was hit by a car in the county of Gävleborg (Sweden; 60°45'N, 16°45'E). The entire carcass was submitted to SVA for necropsy. The 17 kg animal was in good body condition and determined to be 1-yr-old. Both ear canals

were filled with black waxy secretions and exfoliated epithelium. Mandibular, retropharyngeal, cervical and axillar lymph nodes were moderately to severely enlarged. Except the traumatic lesions, endogenous lipid pneumonia and moderate lung emphysema, no further pathological changes were detected.

A juvenile male was found dead on 29 November 1999, on the side of the highway in the country of Örebro (Sweden; 59°15'N, 14°30'E). The entire carcass of the 6-mo-old, 10 kg kitten was submitted to SVA for necropsy. It was in a good body condition and presented traumatic lesions typical of a traffic accident. The inner side of the pinnae was covered with waxy material, and both ear canals were filled with exfoliated epithelium, debris and waxy secretions. The left axillar, both popliteal and the mesenterial lymph nodes were slightly enlarged. There was a moderate amount of ascarids in the small intestine. A small whitish focus was noticed in the cortex of one kidney.

In all three animals, the examination of the pinnae and of the secretions in the ear canals revealed the presence of mites, which were identified as *O. cynotis* on the basis of typical morphological characters (Sloss and Kemp, 1978). Representative specimens of *O. cynotis* are deposited in the Department of Parasitology collection (National Veterinary Institute, Uppsala, Sweden; accession number V150/99). Hundreds of mites were visible on the present parts of the pinnae of the female and the young male, whereas in the older male, only a few parasites were found in the secretion material. Both 1-yr-old lynx were tested serologically for *S. scabiei* infection (Bornstein, 1995), and the results were negative.

The histological examination of the female's ears revealed mild hyperkeratosis and moderate to focally severe acanthosis (Fig. 1). Multifocal erosions and pustules also were present. The epithelial surface was overlain by hyperkeratotic and parakeratotic crusts with mites, mite detritus

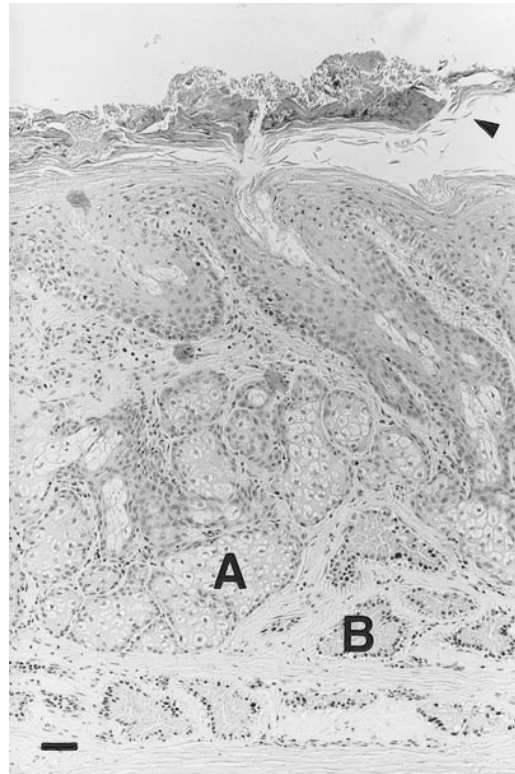


FIGURE 1. Photomicrograph of skin of external auditory meatus from a Eurasian lynx severely infested with *Otodectes cynotis*. Notice layer of exfoliated debris over the epithelium surface (arrowhead), hyperkeratosis, acanthotic thickening of epithelium, hyperplastic sebaceous glands (A), hypertrophic and hyperplastic ceruminous glands (B). H&E stain. Bar = 25 μ m.

and cerumen. In the subcutis there was a slight to moderate infiltration of lymphocytes and macrophages. The ceruminous glands were severely hypertrophic and hyperplastic. There also was a marked hyperplasia of the sebaceous glands. In the 1-yr-old male, the histological changes in the ear canals were similar but milder than in the female. Multifocal hydropic degeneration of epidermal cells was observed, but there were no pustules and only one focal erosion with crust and mite debris. In this area, acanthosis, hyperkeratosis and gland proliferation were more marked, and there was a moderate mononuclear infiltration of mainly lymphocytes in the subcutis. The histological changes in the ear of the

young male were comparable to those in the female. The whitish focus noticed in the renal cortex consisted in a focal interstitial mononuclear inflammatory reaction.

The histological changes, as well as the macroscopical findings, correspond to the symptoms described in chronic cases of otoacariasis in domestic cats (Weisbroth et al., 1974), and these changes appeared to be correlated with the degree of mite infestation. Since the carcass of the female was sent without the skin, it was not possible to exclude a generalized otoacariasis which could have explained the poor body condition. However, if obvious mange lesions were present, the hunter would probably have submitted it for necropsy as well. Weisbroth et al. (1974) suggested that older cats developing clinical otoacariasis represent a minority with defective immune (or physiologic) responses and with consequently less natural defensive ability to control the mite. Therefore, a poor body condition due to malnutrition or any cause which could not be detected at necropsy, might have predisposed the animals to parasite infestation. The enlargement of the lymph nodes in both males was probably not in relation with the otoacariasis, since these changes were not noticed in the female, which was heavily infested and in a poorer condition. However, like the female, the males might have been submitted to a stressful situation prior to mite infestation, which might have predisposed them to otoacariasis.

Of 121 lynx examined at SVA from January to December 1999, only three animals (<3%) originating from different geographic areas (about 150 km apart) presented signs of otoacariasis. A few more lynx with slightly enhanced secretion in the ears were examined for the presence of mites, but none were detected. In previous reports of lynx necropsies performed at SVA, an infestation with *O. cynotis* was noticed only once, in an adult female in a poor body condition and affected with sarcoptic mange. This animal had been found dead in February 1989 in the county of

Västmanland (60°05'N, 15°55'E), but no details concerning the lesions were mentioned in the report and no material was saved for histological examination. Infestations with *O. cynotis* are common in domestic cats in Sweden, but evidently are rare in the lynx. The solitary life style of the lynx (Haglund, 1966; Haller and Breitenmoser, 1986) could explain why the parasite, which is transmitted through direct contact (Kutzer, 1992; Behlert, 1995), is seldom found in this species. Since lynx occasionally prey on domestic cats (Pulliainen et al., 1985; Jobin, 1998), a contact between an infested cat and a lynx cannot be excluded as the source of the mite.

In domestic cats, it is assumed that most individuals are exposed early in life to other mite-bearing cats and thus become infested themselves. It has been conjectured that these animals develop an "immunity," which would explain why ear mites are most prevalent in young animals. Domestic cats appear to tolerate a significant population of otodectic mites without showing clinical signs, and only when a large colony is present do they show marked evidence of irritation (Lane, 1994). The situation might be similar in wild felids and therefore, it is not excluded that more lynx are infested than it appears. The systematic examination of lynx kittens during the marking procedures of on-going population studies might bring further informations on the prevalence of this parasite in free-ranging lynx.

This work was supported by the Swiss National Science Foundation and the Swedish National Veterinary Institute.

LITERATURE CITED

- BEHLERT, O. 1995. Feliden. In *Krankheiten der Zoo- und Wildtiere*. Göldenboth, R., and H.-G. Klös (eds.). Blackwell Wissenschafts-Verlag, Berlin, Germany, pp. 78–105.
- BERG, P., AND R. SHOMER. 1963. Otocariasis in the dog and cat. *Journal of the American Veterinary Medical Association* 143: 1224–1226.
- BORNSTEIN, S. 1995. *Sarcoptes scabiei* infections of the domestic dog, red fox and pig: Clinical and serodiagnostic studies. Ph.D. Dissertation, Swedish University of Agricultural Sciences, and the

- National Veterinary Institute, Uppsala, Sweden, 127 pp.
- DUNGWORTH, D. L. 1993. The respiratory system. *In* Pathology of domestic animals. 4th Edition, K. F. V. Jubb, P. C. Kennedy, and N. Palmer (eds.). Academy Press, Inc., New York, New York, pp. 539–699.
- FOWLER, M. E. 1986. Felidae. *In* Zoo and Wild Animal Medicine. 2nd Edition. M. E. Fowler (ed.). W. B. Saunders Company, Philadelphia, Pennsylvania, pp. 832–841.
- HAGLUND, B. 1966. De stora rovdjurens vintervanor I. *Viltrevy* 4: 1–283.
- HALLER, H., AND U. BREITENMOSER. 1986. Zur Raumorganisation der in den Schweizer Alpen wiederangesiedelten Population des Luchses (*Lynx lynx*). *Zeitschrift für Säugetierkunde* 51: 289–311.
- JOBIN, A. 1998. Predation patterns of Eurasian lynx in the Swiss Jura Mountains. Ph.D. Dissertation, University of Berne, Berne, Switzerland, 75 pp.
- KUTZER, E. 1992. Parasitosen von Hund und Katze: Arthropoden. *In* Veterinärmedizinische Parasitologie. 4th Edition, J. Eckert, E. Kutzer, M. Rommel, H.-J. Bürger, and W. Körting (eds.). Verlag Paul Parey, Hamburg, Germany, pp. 629–645.
- LANE, J. G. 1994. The Ear. *In* Feline Medicine and Therapeutics. 2nd Edition, E. A. Chandler, C. J. Gaskell, and R. M. Gaskell (eds.). Blackwell Science, Oxford, UK, pp. 360–381.
- MÖRNER, T. 1992. Sarcoptic mange in Swedish wildlife. *Revue Scientifique et Technique de l'Office International des Epizooties* 11: 1115–1121.
- PULLIAINEN, E., E. LINDGREN, AND P. S. TUNKKARI. 1995. Influence of food availability and reproductive status of the diet and body condition of the European lynx in Finland. *Acta Theriologica* 40: 181–196.
- SLOSS, M. W., AND R. L. KEMP. 1978. Veterinary clinical parasitology. 5th Edition. Iowa State University Press, Ames, Iowa, 274 pp.
- VAN DEN BROEK, A. H. M., AND K. L. THODAY. 1994. The skin. *In* Feline Medicine and Therapeutics. 2nd Edition, E. A. Chandler, C. J. Gaskell, and R. M. Gaskell (eds.). Blackwell Science, Oxford, UK, pp. 3–83.
- WEISBROTH, S. H., M. B. POWELL, L. ROTH, AND S. SCHER. 1974. Immunopathology of naturally occurring otodectic otoacariasis in the domestic cat. *Journal of the American Veterinary Medical Association* 165: 1088–1094.

Received for publication 16 May 2000.