



Thyroid Gland Development in a Neotenic Goby (Ice Goby, *Leucopsarion petersii*) and a Common Goby (Ukigori, *Gymnogobius urotaenia*) during Early Life Stages

Authors: Harada, Yasuko, Harada, Shigeo, Kinoshita, Izumi, Tanaka, Masaru, and Tagawa, Masatomo

Source: Zoological Science, 20(7) : 883-888

Published By: Zoological Society of Japan

URL: <https://doi.org/10.2108/zsj.20.883>

BioOne Complete (complete.BioOne.org) is a full-text database of 200 subscribed and open-access titles in the biological, ecological, and environmental sciences published by nonprofit societies, associations, museums, institutions, and presses.

Your use of this PDF, the BioOne Complete website, and all posted and associated content indicates your acceptance of BioOne's Terms of Use, available at www.bioone.org/terms-of-use.

Usage of BioOne Complete content is strictly limited to personal, educational, and non - commercial use. Commercial inquiries or rights and permissions requests should be directed to the individual publisher as copyright holder.

BioOne sees sustainable scholarly publishing as an inherently collaborative enterprise connecting authors, nonprofit publishers, academic institutions, research libraries, and research funders in the common goal of maximizing access to critical research.

Thyroid Gland Development in a Neotenic Goby (Ice Goby, *Leucopsarion petersii*) and a Common Goby (Ukigori, *Gymnogobius urotaenia*) during Early Life Stages

Yasuko Harada^{1*}, Shigeo Harada², Izumi Kinoshita³, Masaru Tanaka¹
and Masatomo Tagawa¹

¹Division of Applied Biosciences, Graduate School of Agriculture, Kyoto University,
Kitashirakawaoiwake-cho, Sakyo-ku, Kyoto 606-8502, Japan

²Fisheries Division, Department of Agriculture, Forestry and Fisheries,
1-1 Komatubara-douri, Wakayama 640-8585, Japan

³Usa Marine Biological Institute, Kochi University, Ijiri 194, Usa-cho,
Tosa, Kochi 781-1164, Japan

ABSTRACT—In order to study the characteristics of neoteny in teleosts, development of the thyroid system and digestive tract of a neotenic goby (ice goby, *Leucopsarion petersii*) and a non-neotenic goby (ukigori, *Gymnogobius urotaenia*) were compared. In juvenile ukigori, the intestine was found to be convoluted once in the antero-midpart, and gastric glands were present. In the ice goby, the alimentary canal was straight, and no gastric gland was observed even in adult, suggesting that the ice goby retains larval features, not only in appearance but also in internal organs. A marked difference was also found in the thyroid system. In ukigori, activity of the thyroid gland and thyroid stimulating hormone (TSH) cells increased between flexion and postflexion larval phases. However, in the ice goby, thyroid glands remained inactive, and no TSH cells were observed. A delayed development of the thyroid system was suggested as a major factor contributing to neoteny in the ice goby.

Key words: neoteny, ice goby (*Leucopsarion petersii*), ukigori (*Gymnogobius urotaenia*), thyroid, digestive tract

INTRODUCTION

During the life history, many gobies change their life style from nektonic to benthic, and their appearance from a larval to an adult form (metamorphosis) between the larval and juvenile periods. Air bladders are only present in the larval period, while pigmentation, scale formation, and extension of the pelvic fin occur during metamorphosis. Consequently, the typical appearance of gobies is completed in the early juvenile stage (Dotsu and Uchida, 1979). However, some gobies retain a nektonic life style for their entire life, and the ice goby (*Leucopsarion petersii*) is a typical example. The ice goby has a transparent body with a small pelvic fin and an air bladder, and scales are not present, even in adult individuals. Since these characteristics are only observed in larval stages in ordinary gobies, the ice goby is

considered as neotenic (Dotsu and Uchida, 1979; Kitano, 2002). In amphibians, many studies have been done on the neoteny of urodeles, and it has become clear that thyroid hormones or thyroid hormone receptors do not fully function in these species (Rosenkilde and Ussing, 1996). However, no physiological studies have been carried out on neoteny in teleosts.

In a previous study using adult ice gobies (Harada *et al.*, 2003), the impotency of thyroid hormone in inducing metamorphosis was shown. The presence of well-developed thyroid glands in maturing individuals as well as activation during the spawning season was reported (Tamura and Honma, 1970, Kitano *et al.*, unpublished observations), but there is no information concerning thyroid activity of the ice goby during early life stages. It is possible that the development of thyroid systems in neotenic fish is different from that of most teleosts undergoing metamorphosis.

The present study first deals with the estimation of a “metamorphosis-equivalent” phase in the ice goby, and the confirmation that the digestive organs of the ice goby still

* Corresponding author: Tel. +81-75-753-6222;
FAX. +81-75-753-6229.
E-mail: yasuko@kais.kyoto-u.ac.jp

maintain larval characteristics. Secondly, the development of thyroid follicles and thyroid stimulating hormone (TSH) producing cells were examined in the ice goby during this period, and compared to that in ukigori (*Gymnogobius urotaenia*) which is a non-neotenic but nektonic goby.

MATERIALS AND METHODS

The ice goby spawns in nests under stones, and the fertilized eggs are arranged on the bottom surface of the stone. Once laid, the eggs are cared for by male ice gobies until hatching. Therefore, the fertilized eggs of ice gobies were identified by the presence of stones accompanied by a male. These stones with egg clusters deposited on their surface were collected in the Isazu River in April 2000. They were carefully transported to the Fisheries Research Station of Kyoto University, and placed in plastic tanks (30 liters) containing fresh water until hatching. Hatched larvae were collected, and transferred to a tank containing 100 liters of flow-through seawater. They were reared under natural temperature (14–24°C) and photoperiod, and fed S-type rotifers (*Brachionus rotundiformis*) every morning and evening.

Twenty fish were fixed in Bouin's solution and in 10% neutral formalin at 2–3 days intervals from hatching up to 50 days after hatching (DAH). In addition, several fish were also fixed at 140 DAH.

Morphological development was observed using 10 fish fixed in 10% neutral formalin. The development of the thyroid gland was examined histologically using 3 fish fixed in Bouin's solution, taken from each day. The whole body of the fish was embedded in paraffin, sectioned at 5 μ m intervals, and stained with hematoxylin-eosin. All follicles were examined in the fish from 0 to 50 DAH, and 10 follicles were randomly selected in fish taken at 140 DAH. In order to describe the development and activity of the thyroid, the long and short diameters of each thyroid follicle were measured, and the height of epithelial cells was measured at four different parts of the follicle. The mean value was used as the representative value for each follicle. The number of follicles containing vacuoles in the colloid were also counted. Morphological changes of the digestive organs were also examined histologically.

In order to examine whether the developmental processes found in the ice goby are specific or general among gobies, ukigori (a non-neotenic, but nektonic goby) was used as a control. Larvae and juveniles of ukigori were captured at the Hishiki-River (April 2000; 13.2°C) and Hinuma-Lake (May 2000; 20.6°C) in Ibaragi prefecture, and fixed in 10% formalin. Three fish from each developmental group (newly hatched larva, flexion larva, postflexion larva, and juvenile stage) were used for histological examination. All thyroid follicles were measured in the fish of newly hatched, flexion, and postflexion phases, and 10 follicles were randomly selected from the juvenile period. Thyroid follicles and digestive organs were examined as described for the ice goby.

The serial sections of the pituitary were prepared from two ice goby specimens from each phase (preflexion, flexion, postflexion) and ukigori (flexion and postflexion), and the TSH immunoreactivity was examined using the same procedure used for adult ice gobies (Harada *et al.*, 2003). Due to the low number of fish specimens, TSH immunoreactivity was not examined at the juvenile period.

Developmental stages were determined according to Kendall *et al.* (1984). Significant differences of thyroid follicle diameter and epithelial cell height among developmental phases were tested by Scheffe test after Kruskal-Wallis test and those between different species were tested by Wilcoxon-Mann-Whitney test, and those of the number of follicles containing vacuoles were tested by Fisher's exact probability test using FreeJSTAT 8.2 for Windows (<http://www.vector.co.jp/vpack/filearea/win/business/calc/index.html>).

RESULTS

Development and growth of the ice goby and ukigori

Fig. 1 indicates the growth and development of the ice goby from hatching to 140 DAH. The hypural bones appeared at 12 DAH (TL 5.4 ± 0.4 mm), the tip of the notochord flexed at 20 DAH (6.8 ± 0.1 mm), and the posterior margin of the hypural bones became vertical at 30 DAH (7.5 ± 0.2 mm). Therefore, the fish 12–20 DAH were categorized as being in the prefixion phase, 20–30 DAH as in the flexion phase, and 30–50 DAH as in the postflexion phase. Although the pelvic fin was undeveloped, all other fins were completed at 140 DAH, so fish 140 DAH were categorized as juveniles. The developmental phase of wild-caught ukigori was also determined, and the total length of ukigori was plotted against the equivalent developmental phase.

The total length of the ice goby was 0–20% smaller than that of ukigori in the equivalent developmental phase until the postflexion phase.

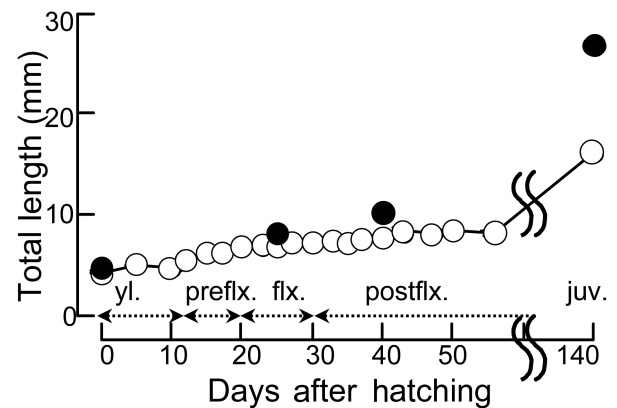


Fig. 1. Growth and development of the laboratory-reared ice goby (open circle) from larval to juvenile period. The total lengths of wild ukigori (closed circle) were also plotted against the equivalent developmental stage. yl: yolk-sac phase, preflx: prefixion phase, flx: flexion phase, postflx: postflexion phase, juv: juvenile phase. Mean \pm SEM (n=10). SEM is within the symbols.

Digestive organs

In the newly hatched larvae of the ice goby, the mouth and the anus opened. The alimentary canal was straight and well differentiated into the pharynx, esophagus, stomach, small intestine and rectum (Fig. 2A), but no gastric gland was observed. The straight arrangement of the alimentary canal and the absence of a gastric gland were similarly observed in juvenile (data not shown) and even adult (Fig. 2B, C).

In the newly hatched larvae of ukigori, the condition of the alimentary canal was similar to that in the ice goby (opened mouth and anus, straight and differentiated into stomach etc, and the absence of a gastric gland) (Fig. 2D). However, in the juvenile stage, the intestine convoluted once in its antero-midpart (Fig. 2E), and gastric glands were observed in the mucosa of stomach (Fig. 2F).

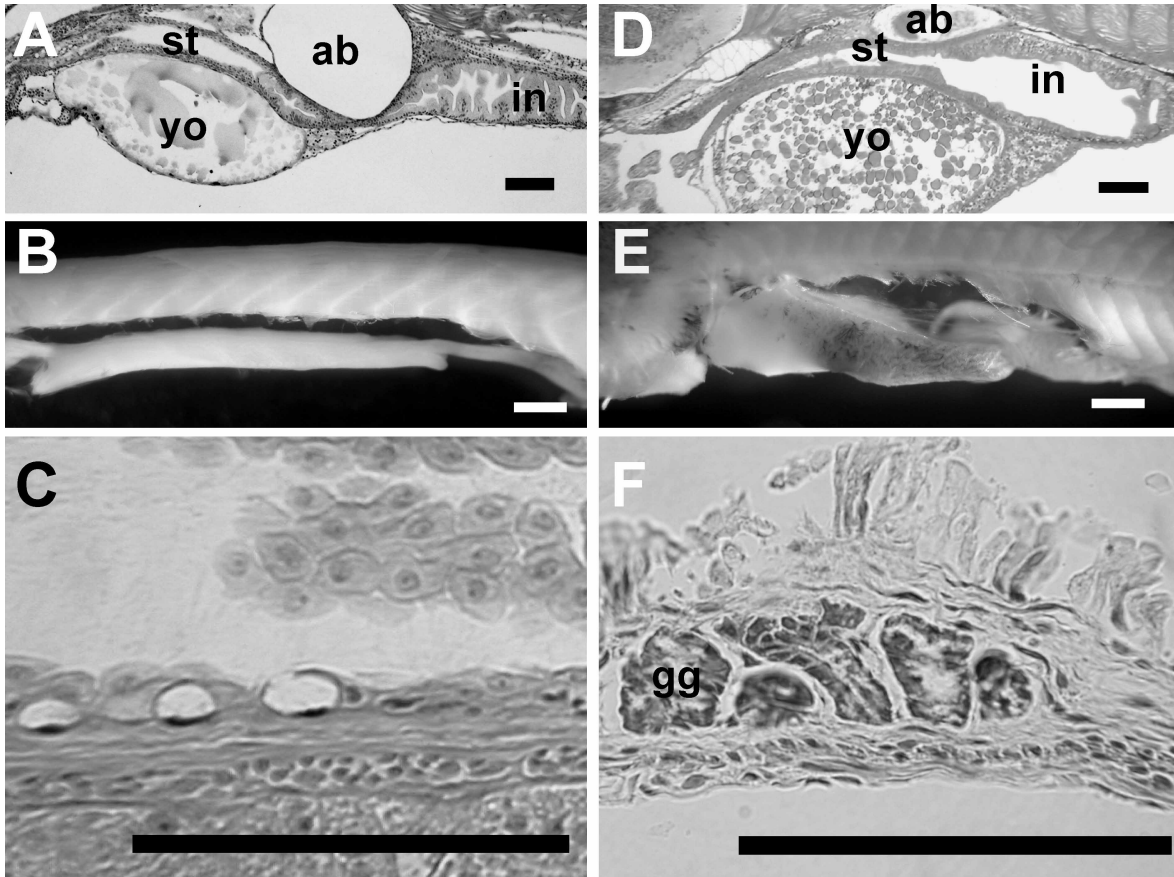


Fig. 2. Digestive tract of the ice goby (A–C) and ukigori (D–F). A and D: newly hatched larva, B: straight arrangement of alimentary canal of adult fish, C: higher magnification of stomach, showing the absence of a gastric gland in adult fish, E: convoluted arrangement of the alimentary canal of juvenile fish, F: gastric glands of juvenile fish. ab: air bladder, in: intestine, st: stomach, yo: yolk, gg: gastric gland. Bars represent (B, E: 1 mm; A, C, D, F: 100 μ m).

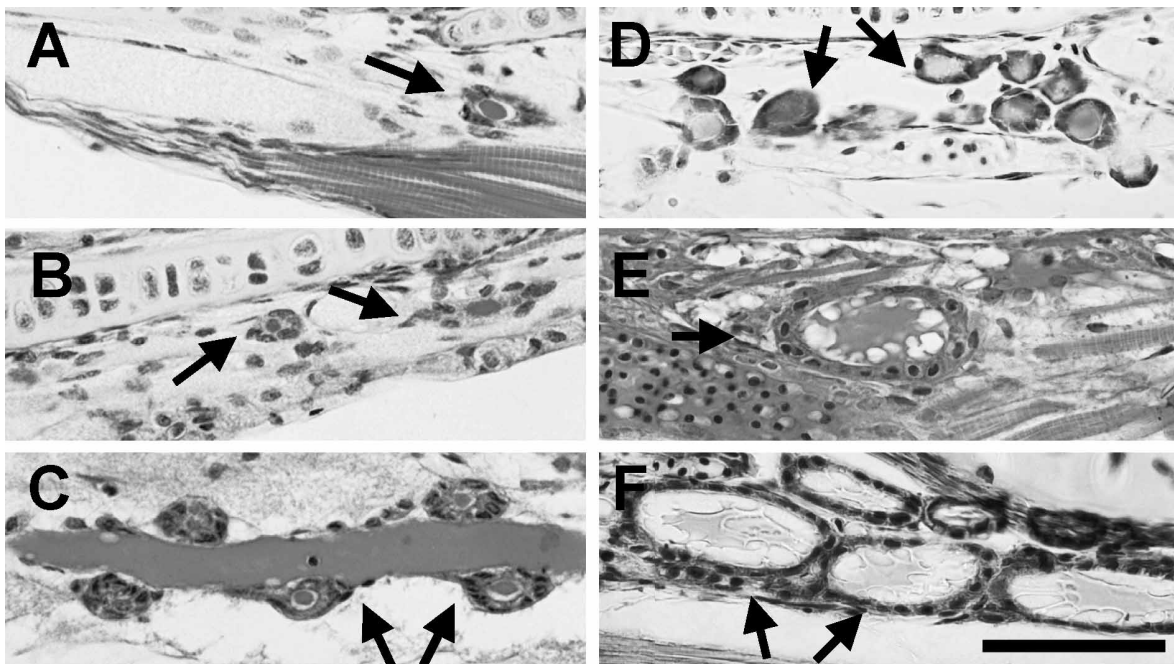


Fig. 3. Photomicrographs of the thyroid glands (arrows) of the ice goby (A–C) and ukigori (D–F) during early development. A and D: flexion phase, B and E: postflexion phase, C and F: juvenile stage. Bar represents 50 μ m.

Development of the thyroid gland

In the ice goby, the size of the thyroid follicles was consistently very small (Fig. 3A–C) during development until 140 DAH. Moreover, only a small number of ovoid epithelial cells surrounded the colloid, and there was no vacuole inside at the flexion and postflexion phases (Fig. 3A, B). The outer boundary of follicles became clear during the juvenile period (140 DAH) due to the change in the epithelial cells from ovoid to cuboid, although no vacuoles were found (Fig. 3C). In ukigori, follicles of a similar size to those in the ice goby were present in flexion larvae (Fig. 3D). However, they grew larger and contained many vacuoles at the postflexion phase (Fig. 3E), similar in appearance to that observed in juvenile period (Fig. 3F).

Changes in the follicle diameter, epithelial cell height, and percentage of thyroid follicles containing vacuoles are shown in Fig. 4. The follicle diameter was constant from preflexion phase of larvae through the juvenile period at about 16 μm in the ice goby (Fig. 4A). The height of the epithelial cells was also constant during the larval period (1.8–2.2 μm), whereas it increased during the juvenile period (3.1

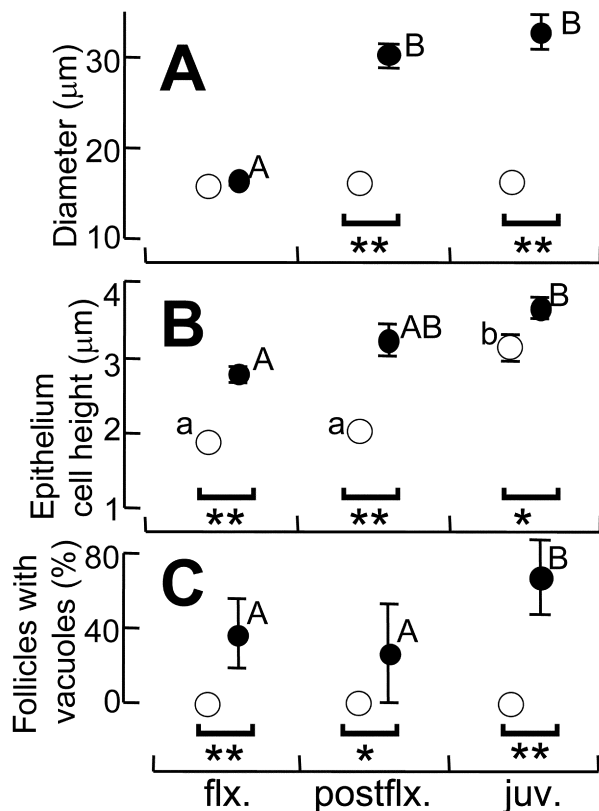


Fig. 4. Development of thyroid follicles in the ice goby (open circle) and ukigori (closed circle). A: diameter of follicles, B: epithelial cell height, and C: percentage of thyroid follicles containing vacuoles. Abbreviations of the stages are shown in Fig. 1. All (flexion and postflexion) or ten (juveniles) follicles were examined in 3 individuals. Mean \pm SEM. SEM is within the symbols in some cases. Means accompanied by the different letter (A and B, a and b) differ significantly each other ($P < 0.05$). *, **: significant difference between the ice goby and ukigori at $P < 0.05$ and $P < 0.01$, respectively.

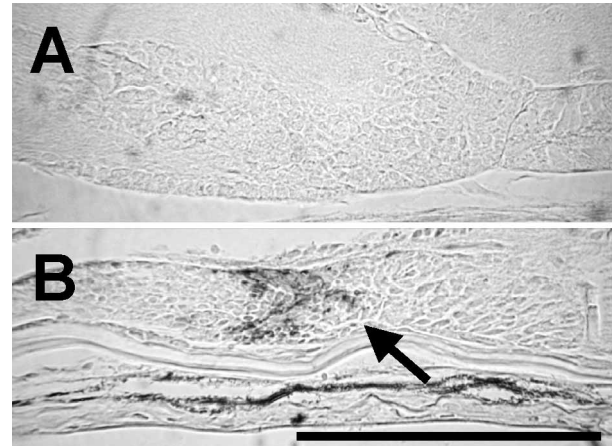


Fig. 5. Serial sagittal sections of the pituitary gland stained with TSH β antisera preadsorbed with salmon GTH/TSH- α subunit, showing the absence and presence (arrow) of TSH immunoreactivity in postflexion larvae of the ice goby (A) and ukigori (B), respectively. Bar indicates 100 μm .

μm) (Fig. 4B). No follicles containing vacuoles were present until the juvenile period in the ice goby (Fig. 4C). In ukigori, the follicle diameter at the flexion phase was 16.5 μm , a value similar to that of the ice goby at the equivalent phase (Fig. 4A). It became significantly larger in the postflexion phase (30.1 μm), and the higher value was maintained during the juvenile period (32.7 μm) (Fig. 4A). The epithelial cell height increased from flexion phase to juvenile period, and was significantly higher than that of the ice goby (Fig. 4B). Vacuoles were present in 30–40% of the follicles after the flexion phase, and in 70% during the juvenile period.

TSH cells

No TSH immunoreactivity was detected in individuals in preflexion and flexion phases of the ice goby, and the flexion phase of ukigori. During the postflexion phase, TSH immunoreactivity was still absent in the ice goby (Fig. 5A), but began to appear in the ukigori (Fig. 5B).

DISCUSSION

In many teleosts, marked development in morphology and physiology occur during the transformation from larvae to juvenile, including the commencement of the adult way of life (Blaxter, 1988; Youson, 1988). However, no such drastic change in morphology is observed with the ice goby, and therefore this species is regarded as a neotenic fish (Dotsu, 1979). Although it is difficult to use a single event to determine the timing for the larva to juvenile transformation among teleosts in general, this transformation is known to start soon after the upward flexion of the notochord end and be completed swiftly (Kendall *et al.*, 1984). When the development of the ice goby was examined (Fig. 1), the flexion of the notochord end occurred between 20–50 DAH at a comparative, although smaller, size than the ukigori. Therefore, this timing may correspond with the larval to juvenile trans-

formation of other teleosts and metamorphosis of other gobies. In other words, if the ice goby was “not” a neotenic species, it would be expected that they would undergo metamorphosis during this period, and would become goby-like in appearance.

In order to confirm that the ice goby has neotenic characteristics with respect to internal organs, the development of the digestive system was examined. The digestive tract of newly hatched larvae of both the ice goby and ukigori were found to be already differentiated (Fig. 2A, D). This feature is commonly observed in larvae derived from demersal eggs (Tanaka, 1969). Thereafter, in ukigori, convolution of the intestine and formation of the gastric glands occurred (Fig. 2E, F). These events are widely observed among teleosts during the larva to juvenile transformation phase, and are one of the most significant events that occur during metamorphosis (Tanaka, 1971). However, no additional qualitative changes occurred in digestive tract of the ice goby, even at the adult stage (Fig. 2B, C). These indicate that the ice goby retains external larval features and internal organs also retain a larval appearance.

The thyroid glands play an important role in the metamorphosis of amphibians and fish (Bentley, 1998). The development of the thyroid gland and TSH cells of neotenic fish was first examined in this study. Thyroid follicles of the ice goby were consistently very small until the juvenile stage (Figs. 3 and 4A). Although the epithelial cell height of thyroid follicles increased between the postflexion phase and early juvenile period (Fig. 4B), no vacuole was observed in the colloid of these follicles (Figs. 3 and 4C). No TSH immunoreactive cells were found during the larval period (Fig. 5). Consequently, the thyroid axis was not considered to be active during the “metamorphosis-equivalent” phase in the ice goby. In other teleosts, thyroid follicles show activation during metamorphosis (Japanese flounder, Miwa and Inui, 1987; conger eel, Yamano *et al.*, 1991). TSH immunoreactive cells also appear during the early larval period, for example, the preflexion period in Japanese flounder (Miwa and Inui, 1987), medaka *Oryzias latipes* (Egawa *et al.*, 1980), and the leptocephalus period in the South Pacific eel and Indian short-finned eel (Ozaki *et al.*, 2000). Moreover, thyroid follicles of ukigori, a non-neotenic goby, became large and active during the late larval period (Figs. 3 and 4) and TSH cells also appeared at the same time as the activation of the thyroid gland (Fig. 5). Therefore, it can be suggested that absence of thyroid activation and TSH immunoreactive cells during the “metamorphosis-equivalent” phase are a specific characteristic of this neotenic fish.

In mature adult ice gobies, well-developed thyroid follicles and TSH cells were found (Tamura and Honma, 1970; Harada *et al.*, 2003). Therefore, the thyroid system of the ice goby is considered to be activated sometime between the juvenile and adult period. An activation of thyroid glands of this fish was reported during the spawning migration from the sea to river (Tamura and Honma, 1970), and an increase in the whole body thyroid hormone level was

shown just before the migration size in laboratory reared fish (Kitano, unpublished observation), probably a phenomenon similar to salmonid migration (Leatherland *et al.*, 1989; Youngson and Webb, 1993). From this information, the thyroid system of the ice goby is considered to develop and become functional just before spawning; a timing very late in the life history in teleosts. If larval tissues of the ice goby can respond to thyroid hormones only during the “metamorphosis-equivalent” phase, the possible deficiency of thyroid hormones due to the “delayed” thyroid activation may prevent the transformation of the “ordinary goby” style.

The results of this study suggest that the development of the thyroid gland and TSH cells are delayed in a neotenic fish, the ice goby. Although the absence of 3,5,3'-triiodothyronine (T3) responsiveness was shown in adult ice gobies in a previous study (Harada *et al.*, 2003), no information is available concerning other developmental stage and/or period, including the “metamorphosis-equivalent” phase. Further experiments where “larval” ice gobies are treated with T3 are necessary to clarify the physiological mechanisms for the ice goby to be neotenic.

ACKNOWLEDGEMENTS

We thank Mr. T. Tsukimi, the president of Maizuru Freshwater Fisheries Association, for kindly supplying the ice goby eggs. We are grateful to Dr. S. Moriyama, Laboratory of Molecular Endocrinology, School of Fisheries Sciences, Kitasato University, Japan, for supplying the antiserum to coho salmon TSH. We are also grateful to Dr. T. Kaneko, Ocean Research Institute, University of Tokyo for immunochemical staining protocols. We are also grateful to the staff and graduate students at the Graduate School of Agriculture, Kyoto University, for their assistance in collecting eggs, rearing fish and experiments. This study was supported in part by grants-in-aid from the Ministry of Education, Culture, Sports and Science, and from the Ministry of Agriculture, Forestry, and Fisheries to M. T.

REFERENCES

- Bentley PJ (1998) Comparative Vertebrate Endocrinology. Third Edition. Cambridge Univ Press, Cambridge
- Blaxter JHS (1988) Pattern and variety in development. In “Fish Physiology vol. 11 (Part A)” Ed by WS Hoar, DJ Randall, Academic Press, New York
- Dotsu Y (1979) On eggs, larvae and juveniles of Gobioid fishes. Marine Sciences 11: 111–116 (in Japanese)
- Dotsu Y, Uchida T (1979) Outline of life history of gobioid fishes exemplified by the ice-goby. Aquabiology 3: 9–16 (in Japanese)
- Egawa K, Aoki K, Yamamoto Y (1980) Development of the pituitary and thyroid gland in the medaka, *Oryzias latipes*. Zool Magazine 89: 104–110
- Harada Y, Harada S, Kinoshita I, Tanaka M, Tagawa M (2003) Response of a neotenic goby, ice goby (*Leucopsarion petersii*), to thyroid hormone and thiourea treatments. Zool Sci 20: 877–882
- Kendall AW Jr, Ahlstrom EH, Moser HG (1984) Early life stages of fishes and their characters. In “Ontogeny and Systematics of Fishes Spec Publ No 1” Ed by Moser HG, Richards WJ, Cohen DM, Fahay MP, Kendall AW Jr, Richardson SL, Am Soc Ichthyol Herpetol, Lawrence, pp 11–22

- Kitano T (2002) Morphogenesis of the ice goby, *Leucopsarion petersii*, under rearing condition. J Sch Mar Sci Tech Tokai Univ 54: 37–48 (in Japanese with English abstract)
- Leatherland JF, Down NE, Donaldson EM, Dye HM (1989) Changes in plasma thyroid hormone levels in pink salmon, *Oncorhynchus gorbuscha*, during their spawning migration in the Fraser River (Canada). J Fish Biol 35: 199–205
- Miwa S, Inui Y (1987) Histological changes in the pituitary-thyroid axis during spontaneous and artificially-induced metamorphosis of larvae of the flounder *Paralichthys olivaceus*. Cell Tissue Res 249: 117–123
- Ozaki Y, Okumura H, Kazeto Y, Ikeuchi T, Ijiri S, Nagae M, Adachi S, Yamauchi K (2000) Developmental changes in pituitary-thyroid axis, and formation of gonads in leptocephali and glass eels of *Anguilla* spp. Fish Sci 66: 1115–1122
- Rosenkilde P, Ussing AP (1996) What mechanisms control neoteny and regulate induced metamorphosis in urodeles? Int Dev Biol 40: 665–673
- Tamura E, Honma Y (1970) Histological changes in the organs and tissues of the gobiid fishes throughout the life-span – 2 The hypophyseal target organs of the ice-goby, *Leucopsarion petersii* Hilgendorf. Jpn J Ichthyol 17: 29–36
- Tanaka M (1969) Studies on the structure and function of the digestive system in teleost larvae – 1 Development of the digestive system during prelarval stage. Jpn J Ichthyol 16: 1–9 (in Japanese with English abstract)
- Tanaka M (1971) Studies on the structure and function of the digestive system in teleost larvae – 3 Development of the digestive system during postlarval stage. Jpn J Ichthyol 18: 164–174 (in Japanese with English abstract)
- Yamano K, Tagawa M, Jesus EG, Hirano T, Miwa S, Inui Y (1991) Changes in whole body concentrations of thyroid hormones and cortisol in metamorphosing conger eel. J Comp Physiol B 161: 371–375
- Youngson AF, Webb JH (1993) Thyroid hormone levels in Atlantic salmon (*Salmo salar*) during the return migration from the ocean to spawn. J Fish Biol 42: 293–300
- Youson JH (1988) First metamorphosis. In "Fish Physiology vol. 11 (Part B)" Ed by WS Hoar and DJ Randall, Academic press, New York

(Received March 11, 2003 / Accepted April 28, 2003)