

## **Histological Observation of the Urogenital Papillae in the Bi-Directional Sex-Changing Gobiid Fish, *Trimma okinawae***

Authors: Yasuhisa Kobayashi, Takeshi Usami, Tomoki Sunobe, Hisaya Manabe, Yoshitaka Nagahama, et. al.

Source: Zoological Science, 29(2) : 121-126

Published By: Zoological Society of Japan

URL: <https://doi.org/10.2108/zsj.29.121>

---

BioOne Complete ([complete.BioOne.org](https://complete.BioOne.org)) is a full-text database of 200 subscribed and open-access titles in the biological, ecological, and environmental sciences published by nonprofit societies, associations, museums, institutions, and presses.

Your use of this PDF, the BioOne Complete website, and all posted and associated content indicates your acceptance of BioOne's Terms of Use, available at [www.bioone.org/terms-of-use](http://www.bioone.org/terms-of-use).

Usage of BioOne Complete content is strictly limited to personal, educational, and non-commercial use. Commercial inquiries or rights and permissions requests should be directed to the individual publisher as copyright holder.

---

BioOne sees sustainable scholarly publishing as an inherently collaborative enterprise connecting authors, nonprofit publishers, academic institutions, research libraries, and research funders in the common goal of maximizing access to critical research.

# Histological Observation of the Urogenital Papillae in the Bi-directional Sex-changing Gobiid Fish, *Trimma okinawae*

Yasuhisa Kobayashi<sup>1,2\*</sup>, Takeshi Usami<sup>2,3</sup>, Tomoki Sunobe<sup>4</sup>, Hisaya Manabe<sup>5</sup>,  
Yoshitaka Nagahama<sup>2,3</sup>, and Masaru Nakamura<sup>1,2</sup>

<sup>1</sup>Tropical Biosphere Research Center, Sesoko Station, University of the Ryukyus, 3422 Sesoko,  
Motobu, Okinawa 905-0227, Japan

<sup>2</sup>Solution-Oriented Research for Science and Technology (SORST),  
Japan Science and Technology Corporation, Kawaguchi, Saitama 332-0012, Japan

<sup>3</sup>Laboratory of Reproductive Biology, National Institute for Basic Biology,  
Okazaki 444-8585, Japan

<sup>4</sup>Tateyama Station, Field Science Center, Tokyo University of Marine Science and Technology,  
670 Banda, Tateyama 294-0308, Japan

<sup>5</sup>Education Center, Kagoshima University, 1-24-30 Korimoto,  
Kagoshima 890-0065, Japan

The gobiid fish *Trimma okinawae* changes its sex bi-directionally according to its social status. Morphological changes in the urinogenital papillae (UGP) of this fish have been reported during sex change. However, there have been no detailed observations of such changes. Here, we histologically examined the UGP structure of male- and female-phase fish. UGPs of fish in female and male phase contained both oviducts and sperm ducts. Both ducts were coalesced into one duct within the posterior region of the UGP. Female-phase fish had many longitudinal folds in the hypertrophied tunica mucosa of the oviduct, which was found to be responsible for the transport of eggs and the removal of follicular cells from the oocyte. In contrast, male-phase fish had an immature oviduct and a mature sperm duct in the UGP. In the male-phase fish, the co-existence of spermatozoa and fibrillar secretions was observed in the sperm duct during spermiation.

**Key words:** gobiid fish, genital duct, urogenital papillae, sperm duct, oviduct, sex change

## INTRODUCTION

Sequential hermaphroditism (sex change) is a widely documented phenomenon in animals (Devlin and Nagahama, 2002). Various coral-reef fishes change their sex according to their social status. Sex change typically occurs in one of two manners, namely, protogyny (sex change from female to male) and protandry (sex change from male to female) (Frisch, 2004). Protandrous and protogynous sex change are generally irreversible. However, recently, sex change in both directions (bi-directional sex change), from female to male and vice versa, has been reported in several species of fish (Frisch, 2004).

The Okinawa rubble goby (*Trimma okinawae*, Pieces: Gobiidae) was the first fish reported to undergo bi-directional sex change fish (Sunobe and Nakazono, 1993). This fish has a polygynous mating system in which a harem normally consists of one dominant male and one or more females. Removal of the dominant male from the harem results in

female-to-male sex change in the largest female. If the dominant male is returned to the harem, the fish that underwent the sex change is transformed into a female again. Field observations and aquarium experiments have confirmed this phenomenon (Sunobe and Nakazono, 1993; Manabe et al., 2007). As bi-directional sex change can be manipulated, this gobiid fish provides an excellent animal model for elucidating the general mechanisms of sex change.

We have previously described the detailed gonadal structure of *T. okinawae* (Kobayashi et al., 2005). The gonadal structure of this fish differs fundamentally from that of other fish that undergo sex change. All gonads that were examined, including those from female- and male-phase fish, unambiguously contained both ovaries and testes attached to an accessory gonadal structure (AGS). In short, this fish is equipped to respond to its social status by possessing both ovary and testis, even though only one gonad remains active at a given time. This unique gonadal structure makes it possible for this fish to change sex in both directions.

During the sex change period, the fish changes not only its gonadal sex, but also its behavior (Nakashima et al., 2000), brain (Godwin, 2010), and body coloration (Sakai et al., 2003; Wittenrich and Munday, 2005) among other char-

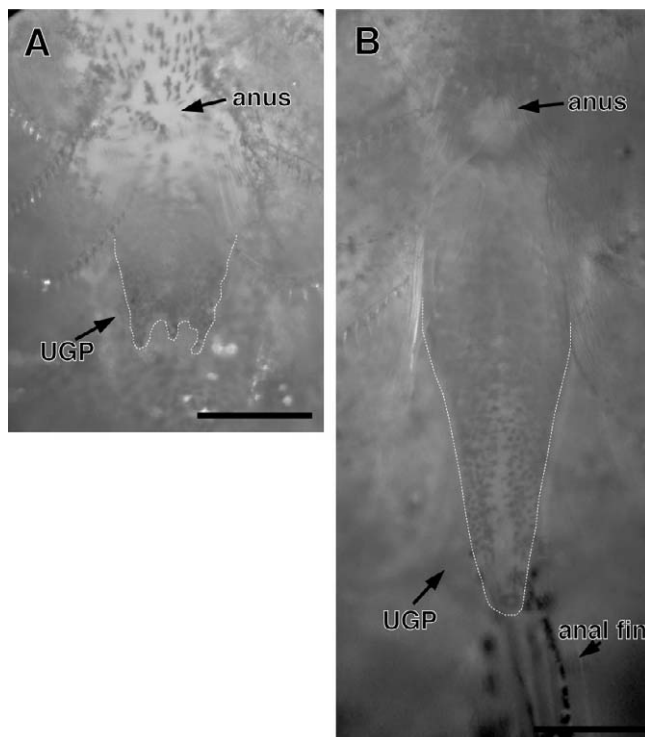
\* Corresponding author. Tel. : +81-980-47-6072;  
Fax : +81-980-47-6072;  
E-mail: yasu\_cob@amber.plala.or.jp  
doi:10.2108/zsj.29.121

acteristics. We have confirmed that *T. okinawae* rapidly changes its sexual behavior and expression of two gonadotropin receptors in the gonads (Kobayashi et al., 2009) after induction of sex change. However, we have been unable to observe sexual dimorphic features of females and males except for the change in the urinogenital papillae (UGP). In this report, we justify the UGP instead of the genital duct. The UGP is located on the ventral surface of the fish, caudal to the anus (Fig. 1). The UGP consists of a urinary duct and a genital duct, and it is well known that gametes produced by gonads are carried through the UGP to the genital ducts. Morphological changes in the UGP have been reported in *T. okinawae* (Grober and Sunobe, 1996) and in other gobioid species (Reavis and Grober, 1999) during sex change. However, no histological examination has been performed on the UGP.

In this study, we histologically examined the UGP structure in male- and female-phase fish of *T. okinawae*, and additionally investigated the role of UGP in reproduction.

## MATERIALS AND METHODS

*Trimma okinawae* were collected with a hand net from their natural habitat in the Okinawa Prefecture, Japan in June 2008. The fishes were transferred to the laboratory and maintained in an aquarium under constant conditions (sea water at 27°C, 14 h light: 10 h dark) at the Sesoko station, University of the Ryukyus. A total of 17 fish (20.3–35.0 mm in total length) were used in this study. All fish were anesthetized with 2-phenoxyethanol (Wako chemicals, Osaka, Japan) before tissue collection. After the measurement of total length, fish were euthanized by decapitation. The reproductive



**Fig. 1.** Ventral views of urinogenital papillae (UGP; broken line) of an adult female-phase (A) and male-phase (B) gobioid fish, *Trimma okinawae*. The UGP in females is short and wide. In contrast, the male UGP is long and sharp. UGP, urinogenital papillae. Bars indicate 0.5 mm.

tracts of the fish were fixed in freshly prepared Bouin's solution overnight at room temperature, then processed in a graded alcohol series and Lemosol Coagulant (Wako), and finally embedded in paraplast (Sigma Chemical Co., St. Louis, MO). Transverse sections of 5–7 µm thickness were cut with a rotatory microtome (Leica, Stockholm, Sweden) and stained with hematoxylin and eosin.

All animal handling and experiments were conducted in accordance with the Guide for Care and Use of Laboratory Animals approved by the University of the Ryukyus.

## RESULTS

### Morphological observation of urinogenital papillae of gobioid fish

External views of UGPs of *T. okinawae* are shown in Fig. 1. As reported previously (Sunobe and Nakazono, 1993; Grober and Sunobe, 1996), the UGP of females is short and wide and has several processes at the papillae opening (Fig. 1A.  $n = 10$ ). Male-phase fish have a long and sharply tapering papillae (Fig. 1B.  $n = 7$ ). Many well-developed vitellogenic oocytes at various stages are seen in the ovaries of female-phase fish. Testes of male-phase fish consisted of many lobules containing spermatogenic germ cells, such as spermatogonia, spermatocytes, spermatids, and sperm. The ovaries of male-phase fish contained only pre-vitellogenic oocytes (data not shown). Fish in the sex-changing phase were not included in this study.

### Histological observation of genital ducts of male-phase fish

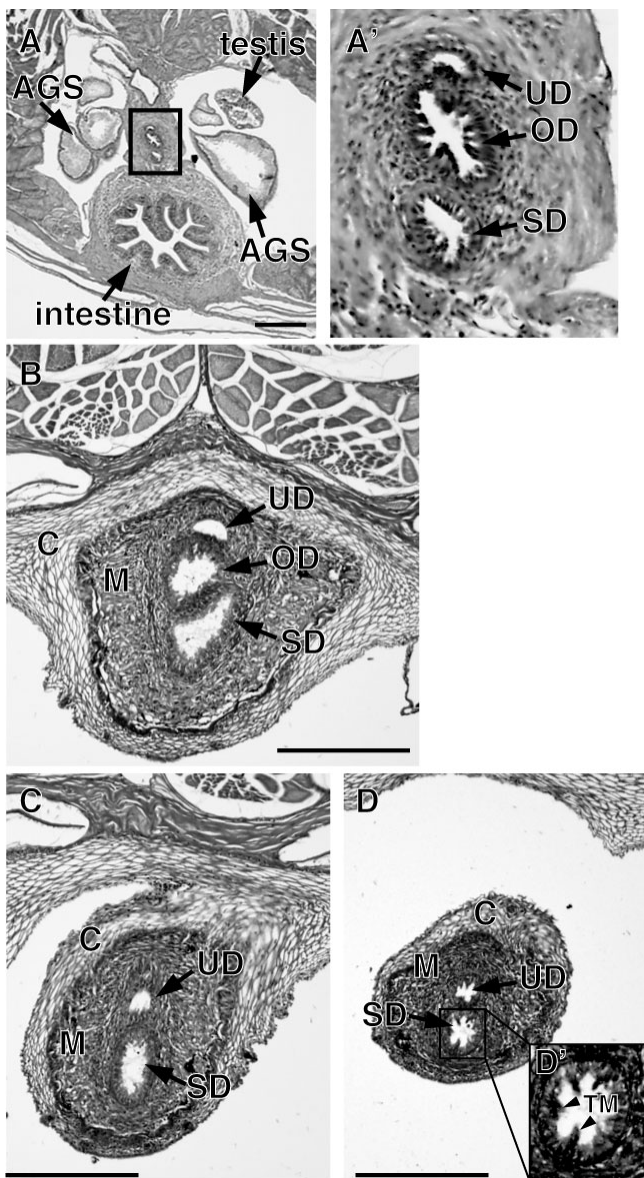
At the posterior end of the testis, a well developed accessory gonadal structure (AGS) attached with genital ducts was observed (Fig. 2A). At the upper part of the intestine, a urinary duct, an oviduct, and a sperm duct passed separately through the UGP (Fig. 2A). At the posterior region of the anus, the UGP was well developed (Fig. 2B). The UGP consisted of a cortex and a medulla. Each oviduct and sperm duct was joined at the middle part of the UGP (Fig. 2C). A few short, longitudinal folds were observed in the tunica mucosa of the sperm duct (Fig. 2D).

### Histological observation of reproductive tracts of female-phase fish

In female-phase fish, three ducts were observed at the dorsal region of the intestine and anus, as in the male (Fig. 3A, B). In the posterior region of the anus, the medulla of the UGP was extremely swollen (Fig. 3C). At the posterior region of the UGP, an oviduct was coalesced with a sperm duct into single genital duct (Fig. 3D). At the end of the oviduct, several processes were observed (Fig. 3E). In the tunica mucosa of the oviduct, a number of hypertrophied longitudinal folds were observed (Fig. 3A–D). In contrast, the sperm duct was smooth and narrow.

### Reproductive role of urinogenital papillae on spermiation and ovulation

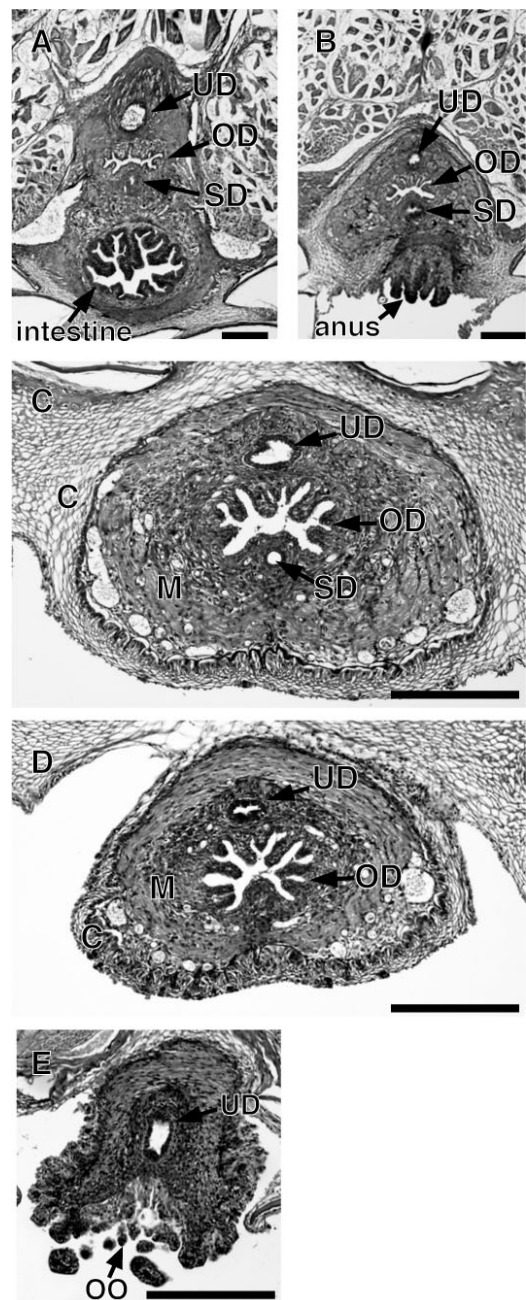
To clarify the involvement of the UGP in ovulation and spermiation, the UGPs of two pairs of male and female fish during spawning were histologically examined. A previous observation (Sunobe and Nakazono, 1990) revealed that spawning occurred in the morning. We set up an aquarium with one male and one female, with a vinyl chloride pipe to



**Fig. 2.** Transverse sections of urinogenital papillae (UGP) in male-phase gobiid fish, *Trimma okinawae* (A–D). (A' and D') Higher magnification of rectangle in A and D. The urinary duct (UD), oviduct (OD) and sperm duct (SD) are enclosed in UGP. AGS, accessory gonadal structure; C, cortex of UGP; M, medulla of UGP; TM, tunica mucosa. Bars indicate 200  $\mu$ m.

serve as their nest. Samples were collected in the early morning (5:00–6:00 AM) during spawning.

Spermiation was observed in the male UGP (Fig. 4A). Spermatozoa and fibrillar secretions stained with Eosin filled the sperm duct of the male (Fig. 4B). AGS of male-phase fish were also filled with spermatozoa and fibrillar secretions (Fig. 4C). In the female, ovulation was observed, with eggs being spawned one by one from the UGP (Fig. 4D). In the oviduct of the female, three or four oocytes were moved along by longitudinal folds of the tunica mucosa (Fig. 4E). Removal of the ovarian follicle cell layer was observed in the oviduct of the middle part of UGP (Fig. 4E). However, the frequency of follicle cell layer separation was unknown. In

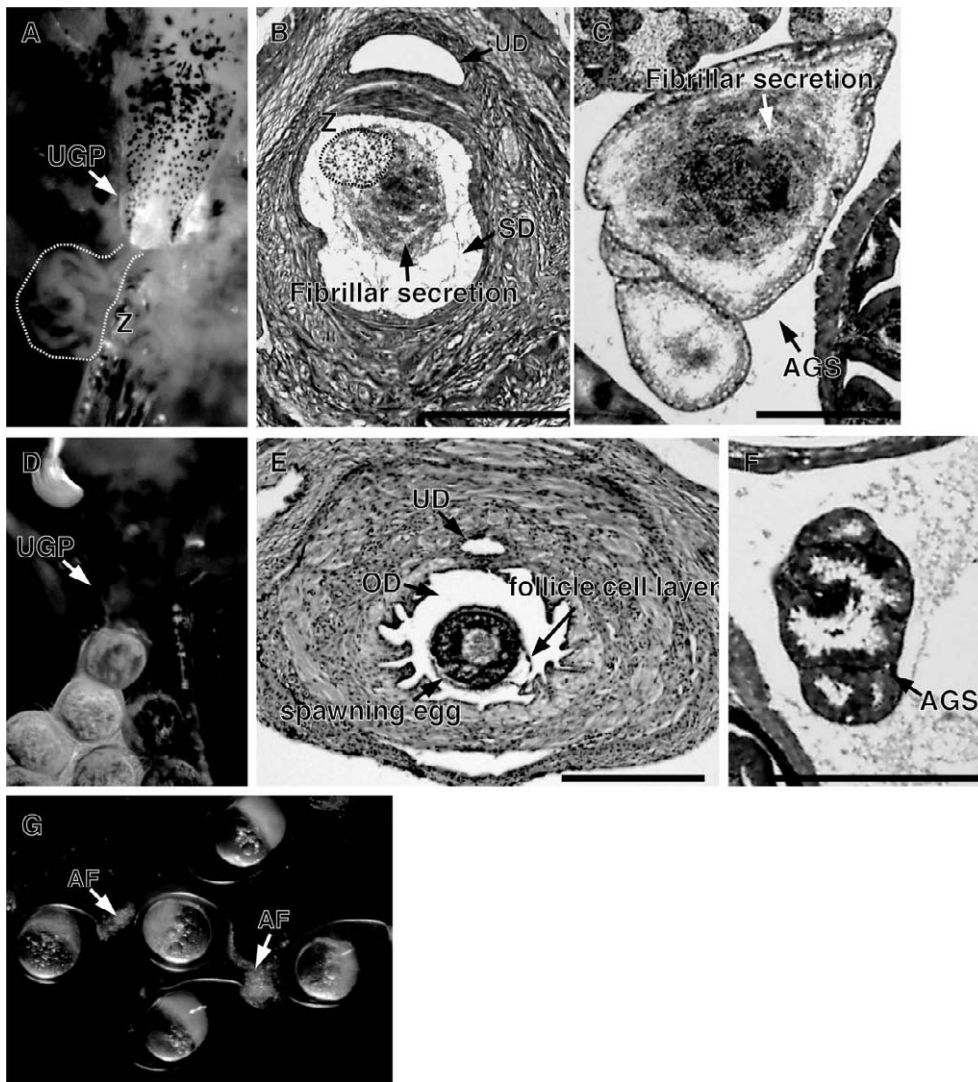


**Fig. 3.** Transverse sections of urinogenital papillae (UGP) in female-phase gobiid fish, *Trimma okinawae* (A–D). The urinary duct (UD), well-developed oviduct (OD), and sperm duct (SD) are enclosed in UGP. In the tunica mucosa of oviduct, a number of hypertrophied longitudinal folds were observed. C, cortex of UGP; M, medulla of UGP; OO, oviduct opening. Bars indicate 200  $\mu$ m.

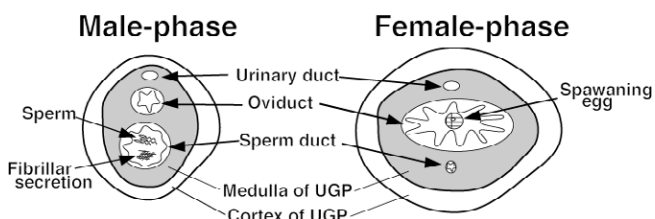
contrast to male, AGS of female was not developed and there are no fibrillar secretions (Fig. 4F). Although spawned eggs had no attachment filaments (Fig. 4D), fertilized eggs were elliptical and adhered to the nest wall with attachment filaments (Fig. 4G).

## DISCUSSION

Many studies of sexual plasticity in the brain (Godwin, 2010) and gonad (Nakamura and Kobayashi, 2005) (Frisch,



**Fig. 4.** Morphological and histological observations of urinogenital papillae (UGP) and accessory gonadal structure of sperminating male- (A–C) and ovulating female- (D–F) phase gobiid fish, *Trimma okinawae*. Fertilized eggs with attachment filaments were observed in the nest (G). AGS, accessory gonadal structure; UD, urinary duct; OD, oviduct; SD, sperm duct; Z, spermatozoa (broken line); AF, attachment filaments. Bars indicate 200  $\mu$ m.



**Fig. 5.** Schematic diagrams of urinogenital papillae structure (UGP) in the bi-directional sex changing gobiid fish, *Trimma okinawae*. Both oviducts and sperm ducts were enclosed in UGP simultaneously.

2004) have been conducted in sex-changing fish. Few studies, however, have focused on changes in the genital ducts. Thus, this study reports and characterizes genital duct structures of male- and female-phase fish of the bi-directional sex changing species *Trimma okinawae* (Fig. 5).

Although two genital ducts were coalesced at the posterior

region of the UGP, all fish examined, including male- and female-phase fish, distinctly possessed both a permanent oviduct and sperm duct. This supports a previous report on the gonadal structure of this species (Kobayashi et al., 2005). These results suggest that each of the two genital ducts is able to carry oocytes and sperm, respectively. In the medaka, the development of the genital ducts of females and males have been described (Suzuki and Shibata, 2004). This study indicated that the caudal part of the oviduct, which the authors termed the genital pore lip, and the ventral region of the urethra mesenchyme are important for the formation of the intra- and extra-genital ducts. The authors also suggested that the developmental processes of the genital duct differ between female and male fish (Suzuki and Shibata, 2004). As the larvae of *T. okinawae* died three days after hatching in a previous study (Sunobe, 1995), at present, we have no data on the developmental processes of the gonads and genital ducts in this species. Further studies are needed to understand how *T. okinawae* develop two genital ducts simultaneously.

Similar to *T. okinawae*, the mangrove killifish, *Kryptolebias marmoratus*, is also known to have ovarian tissue and testicular tissue simultaneously (Sakakura et al., 2006). However, the number of genital ducts are different between species, as killifish have only one genital duct (Sakakura et al., 2006). This difference may be due to the differences in reproductive biology and gonad formation between the species. Killifish are the only known naturally self-fertilizing hermaphrodites (Taylor et al., 1995) and testicular tissues have been shown to make up only a small portion of the gonad (Sakakura et al., 2006). In contrast, *T. okinawae* do not self-fertilize and they do produce only one gamete type at a time according to their social condition. Therefore, the two genital ducts system of gobiid fish may contribute to its inability to self-fertilize.

In our study, the morphology and histology of reproductive ducts in male and female *T. okinawae* revealed sexual dimorphism, similar to previous observations in this (Sunobe and Nakazono, 1993) and other fish species (Meisner et al.,

2000; Spadella et al., 2008). These results suggest that UGPs and their genital ducts are changed during the bi-directional sex change process in *T. okinawae*, as well as in another bi-directional gobiid species, *Lythrypnus dalli* (Carlisle et al., 2000). Treatment with androgens (testosterone or 11-keto-testosterone, which is a major androgen in teleost fish) in the female results in morphological changes of the UGP from the female type to the male type in gobiid fishes (Egami, 1959; Carlisle et al., 2000). Thus, changes of the UGPs in this fish during sex change may be dependent on sex steroid hormones, especially androgens, produced by the gonads.

We observed well-developed oviductal mucosal folds in the UGPs of female-phase fish. These longitudinal folds are thought to assist in the transport of oocytes (ovum transport) to the opening of the oviduct, similar to mammalian tubal peristalsis (Shafik et al., 2005). Interestingly, dissociation of the follicle cell layer from the oocyte was observed in the oviduct at the UGP region. In oviparous teleosts, postovulatory follicles have been shown to be present in the ovary after ovulation (Nagahama, 1994). However, in our previous study, we did not observe postovulatory follicles in the ovary of *T. okinawae* during the spawning cycle (Kobayashi et al., 2004). Thus, we report here the new characterization of oviduct of this fish, which may play an important role in the removal of ovarian follicles as the final step of oocyte maturation, unlike in other teleosts.

Several teleost species, including gobiid fish, are known to have attachment filaments distributed over the eggs (Iwamatsu et al., 2008; Kramer and Patzner, 2008). In the medaka, rudiments of attachment filaments have been clearly shown in the area where granulosa cells connect with the oocyte (Iwamatsu and Nakashima, 1996). However, rudiments of attachment filaments were not observed in ovary of *T. okinawae* (Kobayashi et al., 2005). In addition, attachment filaments were not observed in ovulated eggs from females of *T. okinawae* in this study. However, fertilized eggs were elliptical and adhered to the nest wall with attachment filaments. Histological observations showed that sperm ducts were filled with spermatozoa surrounded by a secretory fibrillar fluid. Therefore, we hypothesize that this secretory fluid is the source of the attachment filaments of the fertilized eggs in *T. okinawae*. This observation raises the question of where the secretory fluid enters into the sperm duct. We observed fibrillar fluid in AGS of male, but not in AGS of female. In another gobiid species (*Gobiodon okinawae*), fibrillar and colloidal secretions were also found in lobes of an AGS attached to the testis (Cole and Hoese, 2001). The AGS is also termed "seminal vesicle", "seminal gland", "sperm-duct gland", or "accessory glandular structure". Various shapes of this structure have been observed in the testes of gobies (Fishelson, 1991), indicating AGSs are common structures among gobiid fishes. Histological observation for gobiid fish AGSs showed high similarity to mammalian seminal vesicle (Aumuller and Riva, 1992). However, AGS is not derived from the Wolffian duct in at least some fishes (Weisel, 1949). For this reason, AGS are not homologous to the mammalian seminal vesicle and accessory glands (Weisel, 1949) but rather a close analogy between AGSs and mammalian seminal vesicle.

As steroid biosynthesis was observed in the AGS of the

*urohaze* goby (Asahina et al., 1989) and the round goby (Jasra et al., 2007), the role of the AGS was predicted to include the production of reproductive pheromones. However, these studies did not provide evidence for direct pheromone effects in gobiid fishes. Therefore, the exact function of the AGS is still unknown at the present. Here, we hypothesized a newly role of the AGS as the production organ of the attachment filaments of fertilized eggs. An investigation of the attachment filaments and AGSs of male gobiid fish will help test our hypothesis.

In conclusion, this study has shown that the bi-directional sex changing gobiid fish have two genital ducts simultaneously. The developmental state of oviducts and sperm ducts correlates to the sexual phase of the fish. Furthermore, we characterized the reproductive role of UGPs in gobiid fish. Female UGPs not only play a role in transportation of eggs, but also in the removal of the ovarian follicle of pre-ovulation oocytes. Attachment filaments of fertilized eggs may be produced by AGSs of the male-phase fish and transported through the sperm duct to the eggs.

## REFERENCES

- Asahina K, Suzuki K, Hibiya T, Tamaoki B (1989) Structure and steroidogenic enzymes of the seminal vesicles of the urohaze-goby (*Glossogobius olivaceus*). *Gen Comp Endocrinol* 74: 385–391
- Aumuller G, Riva A (1992) Morphology and functions of the human seminal vesicle. *Andrologia* 24: 183–196
- Carlisle SL, Marxer-Miller SK, Canario AVM, Oliveira RF, Carneiro L, Grober MS (2000) Effects of 11-ketotestosterone on genital papilla morphology in the sex changing fish *Lythrypnus dalli*. *J Fish Biol* 57: 445–456
- Cole KS, Hoese DF (2001) Gonad morphology, colony demography and evidence for hermaphroditism in *Gobiodon okinawae* (Teleostei, Gobiidae). *Environ Biol Fish* 61: 161–173
- Devlin RH, Nagahama Y (2002) Sex determination and sex differentiation in fish: an overview of genetic, physiological, and environmental influences. *Aquaculture* 208: 191–364
- Egami N (1959) Effect of testosterone on the sexual characteristics of the gobiid fish, *Pterogobius zonoleucus*. *Annot Zool Japon* 32: 123–128
- Fishelson L (1991) Comparative cytology and morphology of seminal vesicles in male gobiid fishes. *Ichthyol Res* 38: 17–30
- Frisch A (2004) Sex-change and gonadal steroids in sequentially-hermaphroditic teleost fish. *Rev Fish Biol Fisher* 14: 481–499
- Godwin J (2010) Neuroendocrinology of sexual plasticity in teleost fishes. *Front Neuroendocrinol* 31: 203–216
- Grober MS, Sunobe T (1996) Serial adult sex change involves rapid and reversible changes in forebrain neurochemistry. *Neuroreport* 7: 2945–2949
- Iwamatsu T, Nakashima S (1996) Dynamic growth of oocytes of the medaka, *Oryzias latipes*. 1. A relationship between establishment of the animal-vegetal axis of the oocyte and its surrounding granulosa cells. *Zool Sci* 13: 873–882
- Iwamatsu T, Kobayashi H, Sato M, Yamashita M (2008) Reproductive role of attaching filaments on the egg envelope in *Xenopoecilus sarasinorum* (Adrianichthidae, Teleostei). *J Morphol* 269: 745–750
- Jasra SK, Arbuckle WJ, Corkum LD, Li W, Scott AP, Zielinski B (2007) The seminal vesicle synthesizes steroids in the round goby *Neogobius melanostomus*. *Comp Biochem Physiol A Mol Integr Physiol* 148: 117–123
- Kobayashi Y, Kobayashi T, Nakamura M, Sunobe T, Morrey CE, Suzuki N, et al. (2004) Characterization of two types of cytochrome P450 aromatase in the serial-sex changing gobiid fish,

- Trimma okinawae*. Zool Sci 21: 417–425
- Kobayashi Y, Sunobe T, Kobayashi T, Nagahama Y, Nakamura M (2005) Gonadal structure of the serial-sex changing gobiid fish *Trimma okinawae*. Devel Growth Diffe 47: 7–13
- Kobayashi Y, Nakamura M, Sunobe T, Usami T, Kobayashi T, Manabe H, et al. (2009) Sex change in the gobiid fish is mediated through rapid switching of gonadotropin receptors from ovarian to testicular portion or vice versa. Endocrinology 150: 1503–1511
- Kramer A, Patzner RA (2008) Morphological and developmental studies on the eggs of four *Coryphopterus* species (Actinopterygii: Gobiidae) in the Caribbean Sea. Acta Ichthyologica Et Piscatoria 38: 97–102
- Manabe H, Ishimura M, Shinomiya A, Sunobe T (2007) Field evidence for bi-directional sex change in the polygynous gobiid fish *Trimma okinawae*. J Fish Biol 70: 600–609
- Meisner AD, Burns JR, Weitzman SH, Malabarba LR (2000) Morphology and histology of the male reproductive system in two species of internally inseminating South American catfishes, *Trachelyopterus lucenai* and *T-galeatus* (Teleostei: Auchenipteridae). J Morphol 246: 131–141
- Nagahama Y (1994) Endocrine regulation of gametogenesis in fish. Int J Dev Biol 38: 217–229
- Nakamura M, Kobayashi Y (2005) Sex change in coral reef fish. Fish Physiol Biochem 31: 117–122
- Nakashima Y, Sakai Y, Karino K, Kuwamura T (2000) Female-female spawning and sex change in a harem coral-reef fish, *Labroides dimidiatus*. Zool Sci 17: 967–970
- Reavis RH, Grober MS (1999) An integrative approach to sex change: social, behavioural and neurochemical changes in *Lythrypnus dalli* (Pisces). Acta Ethologica 2: 51–60
- Sakai Y, Karino K, Kuwamura T, Nakashima Y, Maruo Y (2003) Sexually dichromatic protogynous angelfish *Centropyge ferrugata* (Pomacanthidae) males can change back to females. Zool Sci 20: 627–633
- Sakakura Y, Soyano K, Noakes DLG, Hagiwara A (2006) Gonadal morphology in the self-fertilizing mangrove killifish, *Kryptolebias marmoratus*. Ichthyol Res 53: 427–430
- Shafik A, El Sebai O, Shafik AA, Shafik I (2005) Oviduct contractile response to vaginal distension: identification of vagino-tubal reflex. Arch Gynecol Obstet 271: 148–151
- Spadella MA, Oliveira C, Quagio-Grassiotto I (2008) Morphology and histology of male and female reproductive systems in the inseminating species *Scoloplax distolothrix* (Ostariophysi: Siluriformes: Scoloplacidae). J Morphol 269: 1114–1121
- Sunobe T (1995) Embryonic-development and larvae of three gobiid fish, *Trimma okinawae*, *Trimma grammistes* and *Trimmatom* sp. Jpn J Ichthyol 42: 11–16
- Sunobe T, Nakazono A (1990) Polygynous mating system of *Trimma okinawae* (Pisces: Gobiidae) at Kagoshima, Japan with a note on sex change. Ethology 84: 133–143
- Sunobe T, Nakazono A (1993) Sex change in both directions by alteration of social dominance in *Trima okinawae* (Pisces: Gobiidae). Ethology 94: 339–345
- Suzuki A, Shibata N (2004) Developmental process of genital ducts in the medaka, *Oryzias latipes*. Zool Sci 21: 397–406
- Taylor DS, Davis WP, Turner BJ (1995) *Rivulus marmoratus* – Ecology of distributional patterns in Florida and the central Indian River Lagoon. Bull Mar Sci 57: 202–207
- Weisel GF (1949) The seminal vesicles and testes of *Gillichthys*, a marine teleost. Copeia 2: 101–110
- Wittenrich ML, Munday PL (2005) Bi-directional sex change in coral reef fishes from the family pseudochromidae: An experimental evaluation. Zool Sci 22: 797–803

(Received April 26, 2011 / Accepted August 30, 2011)