

FUNGAL NEPHRITIS IN A GREY-HEADED ALBATROSS

Authors: V. L. THAM, D. A. PURCELL, and D. J. SCHULTZ

Source: Journal of Wildlife Diseases, 10(4) : 306-309

Published By: Wildlife Disease Association

URL: <https://doi.org/10.7589/0090-3558-10.4.306>

BioOne Complete (complete.BioOne.org) is a full-text database of 200 subscribed and open-access titles in the biological, ecological, and environmental sciences published by nonprofit societies, associations, museums, institutions, and presses.

Your use of this PDF, the BioOne Complete website, and all posted and associated content indicates your acceptance of BioOne's Terms of Use, available at www.bioone.org/terms-of-use.

Usage of BioOne Complete content is strictly limited to personal, educational, and non-commercial use. Commercial inquiries or rights and permissions requests should be directed to the individual publisher as copyright holder.

BioOne sees sustainable scholarly publishing as an inherently collaborative enterprise connecting authors, nonprofit publishers, academic institutions, research libraries, and research funders in the common goal of maximizing access to critical research.

FUNGAL NEPHRITIS IN A GREY-HEADED ALBATROSS

V. L. THAM and D. A. PURCELL, Division of Veterinary Pathology, Institute of Medical and Veterinary Science, Box 14, Rundle Street Post Office, Adelaide, South Australia, Australia 5000

D. J. SCHULTZ, 30 Belair Road, Hawthorn, South Australia, Australia, 5062

Abstract: Fungal nephritis was found in a grey-headed albatross, *Diomedea chrysotoma*. The fungus was identified as a member of the *Aspergillus flavus-oryzae* group.

INTRODUCTION

There are numerous descriptions of fungal infections of birds.^{2,3,5} *Aspergillus fumigatus* is the most common fungal species associated with disease in domestic poultry, and has also been isolated from a variety of wild birds. In the authors' experience, localised infections involving lungs and air-sacs, bones or central nervous system are most frequently seen, whilst generalised infections are only rarely encountered.

This report describes the occurrence of fungal nephritis in a grey-headed albatross.

CLINICAL FINDINGS

The albatross was found in a moribund condition on the coast of South Australia in the vicinity of Adelaide. It was killed and submitted for necropsy.

GROSS PATHOLOGY

The bird was emaciated. The left lobe of the liver was ruptured, and a small quantity of blood was present in the body cavity. There was also a recent fracture, apparently traumatic, of the sixth and seventh ribs on the left side. In both kidneys a moderate number of discrete yellow foci approximately 2mm in diameter were visible beneath the kidney capsules. When the kidney was incised, the lesions were seen to be scattered throughout the kidney substance and were of a fairly hard consistency.

The other organs of the body were examined in detail and all appeared normal.

DIAGNOSTIC PROCEDURE

Material for histological examination was taken from the kidneys, lungs, air-sacs, liver, spleen, brain and spinal column. Smears were prepared from the granular lesions in the kidney and were stained using the method described by McKenzie.⁶ Several of the small granular lesions from the kidney were placed on a dry microscope slide. One drop of a working solution, composed of 10ml of blue-black ink and 20ml of 20% KOH, was placed directly on the sample on the slide. A cover slip was applied and the slide was gently heated. When examined under the microscope, fungal structures stained blue, whilst the tissues remained unstained. Portions of the liver, spleen, kidneys, brain and lungs were also inoculated onto sheep blood agar and Sabourad's agar media and incubated at 37C for evidence of bacterial and fungal infections.

RESULTS

Microbiology

Fungal hyphae were seen in the smears prepared from the kidney lesions. The fungus, in pure culture, was isolated only from the kidney and was identified on its growth and morphological characteristics on Sabourad's agar as a member of

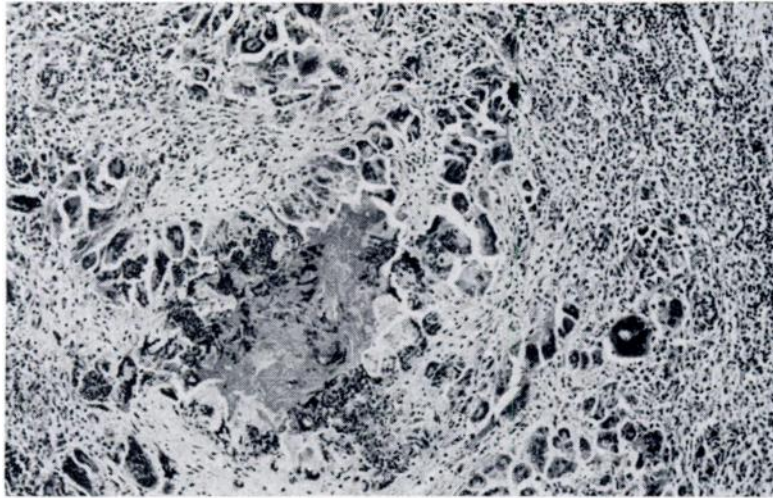


FIGURE 1. A necrotic focus in the region of the medullary collecting ducts. Haematoxylin and eosin X III

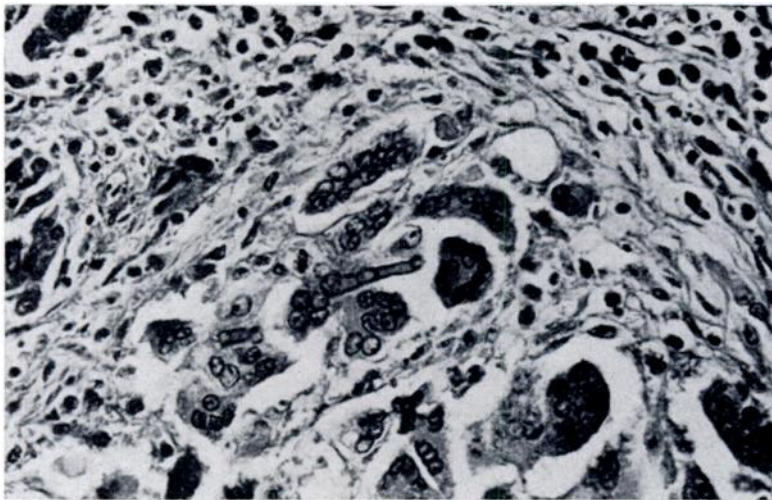


FIGURE 2. Granulomatous reaction around a fungal hypha. Haematosylin and eosin X 444

the *Aspergillus flavus-oryzae* group.³ Colonies which formed within 48 hours at 37C were flat, white and slightly fuzzy. When the conidia developed, a yellow-green colour was produced. The vesicle was shaped like an inverted flask with a rounded bottom and long drawn-out neck. A single row of sterigmata bore chains of conidia which were yellowish-green and had slightly rough walls.

Small numbers of non-haemolytic coliform and *Proteus sp.* organisms were isolated from the liver, spleen and kidneys.

Histology

Foci of coagulative necrosis, surrounded by a pronounced cellular reaction composed of macrophages and multinucleate giant cells and an extensive band of fibrous tissue, were seen scattered throughout the kidneys. Smaller granulomata composed of a few multinucleate giant cells only, often aggregated around a single fungal hypha, were also present and were most numerous in the region of the medullary collecting ducts and around the larger branches of the ureters. Using the periodic acid Schiff and Grocott's techniques,⁴ only an occasional fungal hypha was demonstrated in the necrotic centres of the larger granulomata. Both here and in the smaller lesions, the fungus was only poorly demon-

strated using both these techniques, despite the employment of widely varying staining times.

DISCUSSION

No member of the *Aspergillus flavus-oryzae* group of fungi has, to the best of our knowledge, been previously isolated from the grey-headed albatross. We have recently encountered a field outbreak of major proportions of infection due to *Aspergillus flavus-oryzae* in domestic poultry. Fungal granulomata were seen in the lungs, air-sacs and eye lids. Fungal nephritis was not observed.

In view of the localisation of the fungus in the kidney of the albatross, it is tempting to postulate that the infection may have gained access via the ureters. However, no evidence of infection of the ureters could be detected.

The recent nature of the injuries observed at post-mortem were considered to be the immediate cause of the bird's moribund condition. It would appear most unlikely that the fungal infection, because of its obvious chronicity, was related in any way to the other injuries observed. Furthermore, the considerable amount of apparently normal renal tissue remaining would suggest that renal failure contributed little, if at all, to the physical condition of the bird.

Acknowledgements

We wish to acknowledge the help given in identifying the fungus by Mrs. P. Davenport of the Institute of Medical and Veterinary Science, Adelaide, and Miss G. Brown of the Adelaide Children's Hospital. We are also grateful to Mr. O'Callaghan and Mr. I. Clarke for technical assistance.

LITERATURE CITED

1. AINSWORTH, G. C. and P. K. C. AUSTWICK. 1973. *Fungal Diseases of Animals*. 2nd ed. Review Series No. 6 of the Commonwealth Bureau of Animal Health, Commonwealth Agricultural Bureaux, Farnham Royal, Slough, England. pp. 37-44.
2. AJELLO, L., L. K. GEORG, W. KAPLAN and L. KAUFMAN. *Laboratory Manual for Medical Mycology*. U.S. Department of Health, Education, and Welfare. Public Health Service, Communicable Disease Centre—Atlanta 22, Georgia, U.S.A.

3. BIESTER, H. E. and L. H. SCHWARTE (Eds.). 1965. *Diseases of Poultry*. 5th ed. Iowa State University Press, Ames, Iowa, U.S.A.
4. DRURY, R. A. D. and E. A. WALLINGTON (Eds.). 1967. *Carleton's Histological Technique*, 4th ed. Oxford University Press, New York/Toronto.
5. McDIARMID, A. 1955. Aspergillosis in free-living wild birds. *J. Comp. Path. Therap.* 65: 246-249.
6. McKENZIE, R. A. 1973. Fungi detection in hairs and skin scrapings—a modified procedure. Control and Therapy No. 164A. Post-graduate Committee in Veterinary Science, University of Sydney, Australia.

Received for publication 18 October 1973
