

## **CASE REPORTS OF OSSIFYING FIBROMATA IN THE STRIPED MULLET 1**

Author: DONALD V. LIGHTNER

Source: Journal of Wildlife Diseases, 10(4) : 317-320

Published By: Wildlife Disease Association

URL: <https://doi.org/10.7589/0090-3558-10.4.317>

---

BioOne Complete ([complete.BioOne.org](http://complete.BioOne.org)) is a full-text database of 200 subscribed and open-access titles in the biological, ecological, and environmental sciences published by nonprofit societies, associations, museums, institutions, and presses.

Your use of this PDF, the BioOne Complete website, and all posted and associated content indicates your acceptance of BioOne's Terms of Use, available at [www.bioone.org/terms-of-use](http://www.bioone.org/terms-of-use).

Usage of BioOne Complete content is strictly limited to personal, educational, and non-commercial use. Commercial inquiries or rights and permissions requests should be directed to the individual publisher as copyright holder.

---

BioOne sees sustainable scholarly publishing as an inherently collaborative enterprise connecting authors, nonprofit publishers, academic institutions, research libraries, and research funders in the common goal of maximizing access to critical research.

## CASE REPORTS OF OSSIFYING FIBROMATA IN THE STRIPED MULLET<sup>□</sup>

DONALD V. LIGHTNER, National Marine Fisheries Service, Gulf Coastal Fisheries Center  
Galveston Laboratory, Galveston, Texas 77550 U.S.A.

*Abstract:* Ossifying fibromata are described from three striped mullet (*Mugil cephalus*) from the Gulf of Mexico near Galveston, Texas. The tumors were classified as ossifying fibromata based on their predominately fibrous composition, the presence of bone spicules in the larger tumors, and the absence of mitotic figures.

### INTRODUCTION

The occurrence of tumors in teleost fishes has been thoroughly reviewed.<sup>3,4,5</sup> According to these authors, fibrous tumors are among the most common types of fish tumors, both in fresh water and marine fish species. Fibromata are fibrous tumors in which collagen-forming fibroblasts predominate, although other cellular elements are often present. These mixed tumors are described according to the type of tissue elements present. Mixed tumors with both cartilage and fibrous tissue have been described as chondromata, while tumors composed of fibrous and fatty tissues have been classified as fibrolipomata.<sup>3,5</sup> Tumors consisting both of fibrous elements and bone are classified either as osteofibromata or as ossifying fibromata depending upon whether osseous or fibrous tissue predominate (personal communication, J. C. Harshbarger, Registry of Tumors in Lower Animals, Smithsonian Institution, Washington, D.C. 20560).

Ossifying fibromata are described from three striped mullet collected live from the Gulf of Mexico near Galveston, Texas.

### CASE REPORTS

Fish 1 (310 mm TL) was collected from the Galveston beachfront on May

16, 1973, and preserved by freezing. The frozen specimen was thawed, photographed, and then fixed in 10% phosphate-buffered formalin. Present on the right parietal region of the mullet's head were two large independent pedunculated tumors (Fig. 1). The tumors were similar in appearance; the anterior tumor was 50 by 35 by 28 mm, and the posterior was 60 by 40 by 35 mm. Both were white to greyish-white and firm, although the anterior lobe of the posterior tumor had a firmer consistency than any other portion of either tumor. The tumors had a tough outer capsule that was without scales and had large hemorrhagic areas. Both tumors arose from the subcutis and neither appeared to be invasive.

Fish 2 (360 mm TL) was collected on June 24, 1973 from the same location as Fish 1. The fish was killed and the fish's head and the tumor were fixed separately in 10% phosphate-buffered formalin. The pedunculated tumor was similar to the tumors of Fish 1, was 26 by 20 by 15 mm, whitish-grey, and arose from the same location as the anterior tumor of Fish 1. The consistency of the tumor was firm, but not so firm as either tumor on Fish 1, and was not invasive.

<sup>□</sup> Contribution No. 378 from the National Marine Fisheries Service, Gulf Coastal Fisheries Center, Galveston Laboratory, Galveston, Texas 77550.

Fish 3 (337 mm TL) was collected from Galveston Bay in October of 1973, and preserved by freezing. The fish was later thawed and processed in the same manner as were Fish 1 and 2. Small pedunculated tumors were present near the posterior edge of each operculum. The left tumor was 6 by 10 by 3 mm and the right was 10 by 8 by 5 mm. Both tumors arose from the subcutis, were firm, but less firm than those of Fish 1, were white in color and were not invasive.

#### HISTOPATHOLOGY

Following fixation, histologic sections of each tumor were cut frozen and after paraffin embedding; frozen sections were stained with Sudan IV Fat stain<sup>1</sup> and paraffin sections were stained with hematoxylin and eosin, periodic acid-Schiff, and Mallory's aniline blue collagen stain.<sup>2</sup> Representative portions of each tumor from each fish were examined histologically.

The tumors from all three fish had a similar histological appearance. All of the tumors were composed primarily of fibrous tissue that was regularly arranged and dense in some areas and loose and "alveolar" in other areas (Figs. 2, 3, and 4). Fibroblasts had a normal appearance and mitotic figures were not observed. Sudan IV-stained frozen sections showed that the "alveolar" areas did not contain fat. Artifact resulting from freezing may have been partially responsible for the "alveolar" appearance of the loose con-

nective tissue, but similar areas were present in the tumor from Fish 2 that was not frozen.

The tumors were covered by a relatively thick fibrous sheath with some areas still possessing epidermal remnants. A few melanophores were present in the tumor cores, but most were present in the tumor capsules (Fig. 3). Vascularization was typically poor, but large hemorrhagic areas were present in the capsules of the tumors of Fish 1 and Fish 2. The hemorrhages resulted presumably from trauma.

The major difference among these tumors was the presence of bone spicules in the large tumors. Bone spicules were absent in the relatively small tumors on Fish 3, were small, few in number, and poorly calcified in the tumor on Fish 2, but were abundant, relatively large, and frequently calcified in the tumors on Fish 1. The bone spicules in Fish 1 and 2 were cellular with numerous osteocytes contained within regularly spaced lacunae (Figs. 2 and 4). Calcification of the bone spicules was variable; some were totally eosinophilic indicating minimal or no calcification, while other bone spicules were darkly basophilic, indicating heavier deposition of calcium (compare Figs. 2 and 3). Calcification was not so heavy, however, as to require decalcification prior to sectioning.

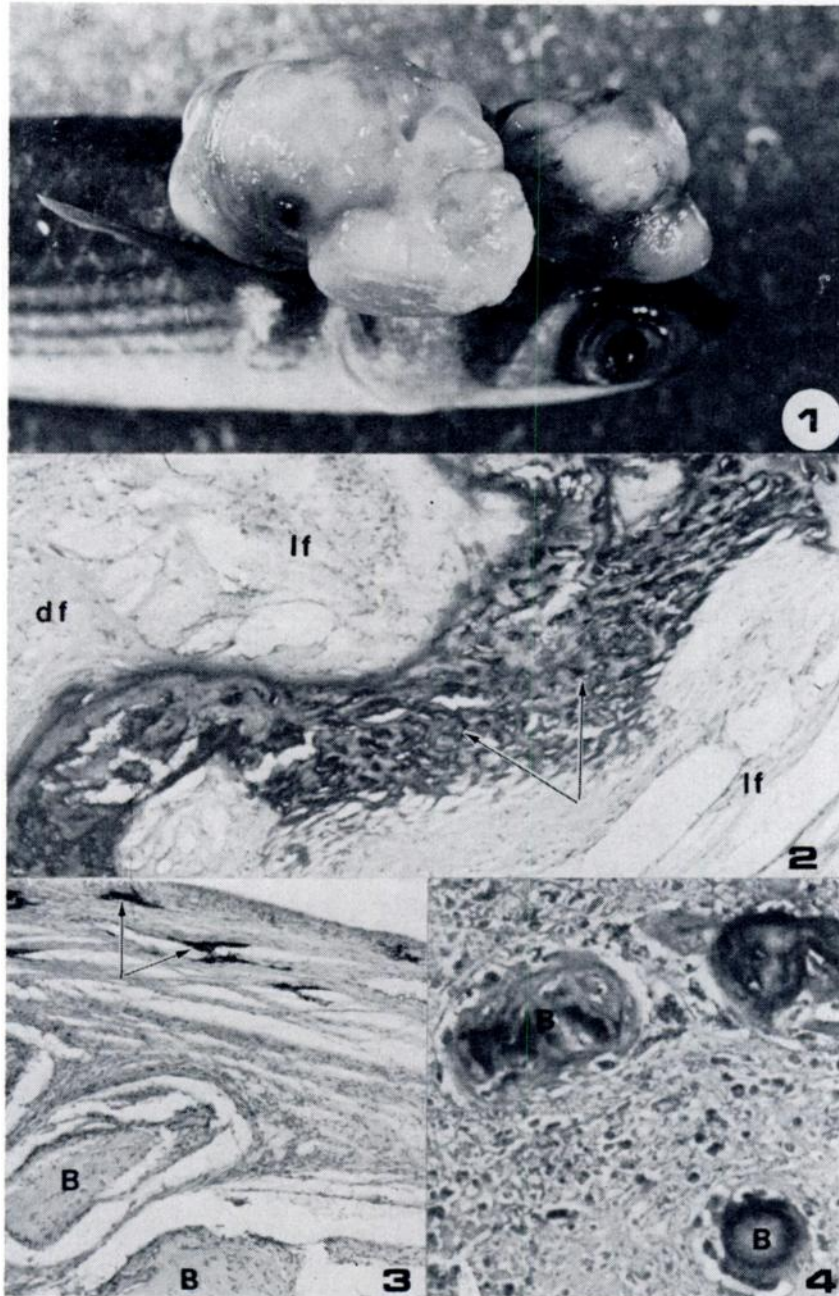
The bone spicules in Fish 2 were confined to the core of the tumor near the tumor base, while those in the tumors of Fish 1 were distributed throughout both tumors.

FIGURE 1. Striped mullet (*Mugil cephalus*) with two independent pedunculated tumors arising from the subcutis on the right parietal region of the head. The dark areas, particularly on the dorsal surfaces of the tumors, are hemorrhagic areas. The dark areas on the basal and lateral surfaces of the anterior tumor are melanophores.

FIGURE 2. Photomicrograph of a histological section from the posterior tumor of Fish 1. Dense (df) and loose (lf) fibrous tissues and a calcified, cellular bone spicule are shown. Osteocytes are present within the lacunae (arrows). Hematoxylin and eosin. X160.

FIGURE 3. Uncalcified bone spicules (B) from the anterior tumor of Fish 1. Melanophores (arrows) are present in the dense fibrous capsule of the tumor. Hematoxylin and eosin. X120.

FIGURE 4. Histological section from the tumor on Fish 2 showing small, poorly calcified, cellular bone spicules (B) that were present within portions of the base and core. Hematoxylin and eosin. X250.



#### DISCUSSION

Based on the primarily fibrous composition of these tumors and distinctly benign gross and histological characteristics, i.e., lack of invasiveness and mitotic figures, these tumors could be considered to be fibromata. Both tumors on Fish 3 are typical fibromata. However, the presence of irregular bony spicules within the tumors of Fish 1 and Fish 2 necessitates the classification of these tumors as osteofibromata or as ossifying fibromata.

The tumors of all three fish appeared to originate from the subcutis and did not appear to originate from either the bony tissues of the skull or from scale-forming tissues. The absence of bone in the small tumors of Fish 3, the presence of a few small bony spicules in Fish 2, and the comparatively large and abundant bony spicules in Fish 1 may be taken to suggest that these tumors originate as fibrous tumors of the subcutis and develop bone secondarily as the tumor grows. Therefore, these tumors are classified as ossifying fibromata.

#### Acknowledgments

The author wishes to thank Raymond H. Niblock and Donald A. Meineke of this Laboratory, and Melvin Driskill of Texas City, Texas, for submitting the mullets and Imogene Sanderson for technical assistance. J. C. Harshbarger, Registry of Tumors in Lower Animals, Washington, D.C., provided assistance in classifying these tumors.

#### LITERATURE CITED

1. LILLIE, R. D. 1965. *Histopathologic Technique and Practical Histochemistry*. McGraw-Hill Book Co. New York.
2. MALLORY, F. B. 1942. *Pathological Technique*. W. B. Saunders Co. Philadelphia. p. 153.
3. MAWDESLEY-THOMAS, L. F. 1972. Some tumors of fish. *Symp. Zool. Soc. Lond.* No. 30. 191-283.
4. REICHENBACH-KLINKE, H. and E. ELKAN. 1965. *The Principal Diseases of Lower Vertebrates*. Academic Press. New York.
5. WELLINGS, S. R. 1968. Neoplasia and primitive vertebrate phylogeny: echinoderms, prevertebrates, and fishes—a review. In *Neoplasm and Related Disorders of Invertebrate and Lower Vertebrate Animals*. National Cancer Institute Monograph 31. pp. 59-128.

Received for publication 21 November 1973