

Acholeplasma laidlawii AND Pasteurella multocida ISOLATED FROM THE PNEUMONIC LUNG OF A LYNX

Author: LANGFORD, E. V.

Source: Journal of Wildlife Diseases, 10(4) : 420-422

Published By: Wildlife Disease Association

URL: <https://doi.org/10.7589/0090-3558-10.4.420>

BioOne Complete (complete.BioOne.org) is a full-text database of 200 subscribed and open-access titles in the biological, ecological, and environmental sciences published by nonprofit societies, associations, museums, institutions, and presses.

Your use of this PDF, the BioOne Complete website, and all posted and associated content indicates your acceptance of BioOne's Terms of Use, available at www.bioone.org/terms-of-use.

Usage of BioOne Complete content is strictly limited to personal, educational, and non - commercial use. Commercial inquiries or rights and permissions requests should be directed to the individual publisher as copyright holder.

BioOne sees sustainable scholarly publishing as an inherently collaborative enterprise connecting authors, nonprofit publishers, academic institutions, research libraries, and research funders in the common goal of maximizing access to critical research.

Acholeplasma laidlawii AND *Pasteurella multocida* ISOLATED FROM THE PNEUMONIC LUNG OF A LYNX

E. V. LANGFORD*

Abstract: *Acholeplasma laidlawii* and *Pasteurella multocida* were recovered from the pneumonic lungs taken from a lynx (*Lynx canadensis*) which had been shot.

INTRODUCTION

The presence of mycoplasma in the normal or pneumonic respiratory tract of the domestic animal is well documented, but there is scant documentation of mycoplasma in the same system of captive or free-living wild animals. Reports available to the author cite the recovery of mycoplasma from the lion, lynx, tiger, cheetah, puma, and other species of the Felidae,⁵ bighorn sheep¹² and chamois⁶ of the Bovidae, various primates,^{2,4} and short-eared European hedgehog, an insectivore.⁹ All except the chamois and hedgehog were captive animals.

This report describes the isolation of *Acholeplasma laidlawii* and *Pasteurella multocida* from the pneumonic lung of a free-living lynx.

HISTORY AND PATHOLOGICAL FINDINGS

The lynx (*Lynx canadensis*) was found sitting in a ditch near Blackie, Alberta, and refused to move. Since it was suspected that the animal might be rabid, it was shot.

Tissue samples were taken from the lung and spleen for bacteriological and histopathological examination, and the brain was examined for the presence of rabies virus by the fluorescent antibody technique. Specific fluorescence was not

found. The only gross lesion was moderate red lobular consolidation of the lungs. Histopathological examination of 6 μ m sections of lung tissue stained by haematoxylin-eosin (HE) revealed a uniform degeneration of the epithelium of all bronchi and bronchioles (Fig. 1). Alveolar septal cells were very numerous in all air passages. Acute inflammatory cells were not prevalent. Mononuclear and plasma cells were freely scattered in the submucosal connective tissue. The latter is a frequent observation in animals exposed experimentally to *M. pneumoniae*.

BACTERIAL ISOLATES

Bacterial isolations from the lung were made on 5% bovine blood tryptose agar plates using standard aerobic techniques. A Gram negative organism which was identified as *P. multocida* on the basis of biochemical and fermentation reactions was isolated in pure culture.⁸ Selective media as described previously⁷ were used in a successful attempt to isolate a member of the order Mycoplasmatales. The isolate was purified by cloning. Serological, growth inhibition and growth precipitation tests, as well as incident and transmitted fluorescence microscopy, as described by other workers, were used to identify the isolate as *Acholeplasma laidlawii*.^{1,10} T strains were not recovered using Shepard's medium.⁸

* Animal Pathology Division, Health of Animals Branch, Agriculture Canada, Animal Diseases Research Institute (Western), P.O. Box 640, Lethbridge, Alberta T1J 3Z4, Canada.

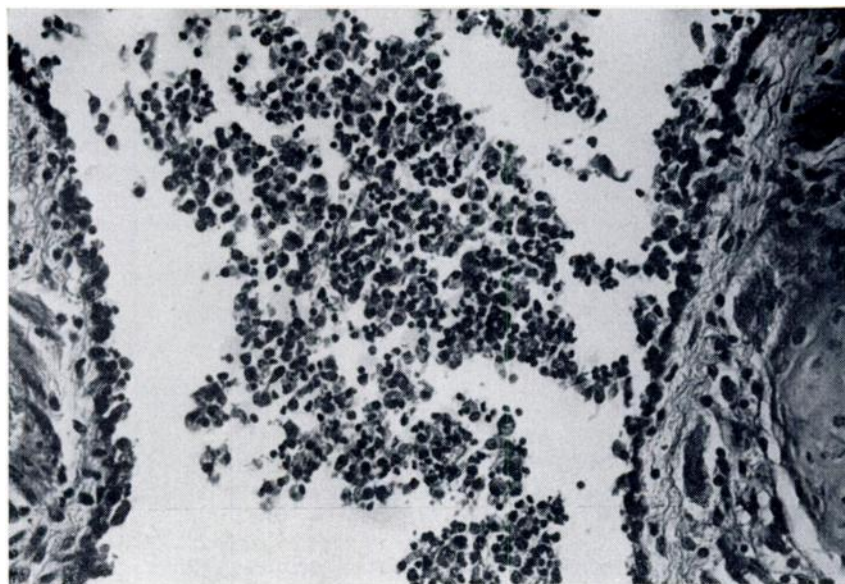


FIGURE 1. Degenerative bronchitis in a lynx. Note desquamation of epithelial cells to the basement membrane, absence of neutrophils and presence of mononuclear cells in the connective tissue. Magnification 80X.

DISCUSSION

It is difficult to assess with certainty whether or not the *A. laidlawii* isolate contributed to the lobular pneumonia observed in the lynx. However, several species of mycoplasmatales are known to cause pneumonia in other species. Although *A. laidlawii* has been recovered from pneumonic animal lungs, its pathogenicity has not been proven. Nevertheless one must consider the possible role of mycoplasmas or acholeplasmas as op-

portunists since they have been isolated from clinically normal respiratory tracts.¹¹ Virus isolations were not attempted.

The presence of *A. laidlawii* in a pneumonic lung taken from a free-living lynx which had been shot suggests that in certain cases of pneumonia, the role of mycoplasmas and acholeplasmas as possible infecting agents should be considered, in addition to the roles of other bacteria, viruses and parasites which have been recovered from the respiratory tracts of domestic and wild animals.

Acknowledgments

The author expresses appreciation to Dr. R. L. Lancaster and Dr. W. J. Dorward for making the specimen available, to Dr. K. W. F. Jericho for the histopathological examination, and to Mr. J. Burchak for efficient technical assistance.

LITERATURE CITED

1. BAAS, E. J. and D. E. JASPER. 1972. Agar block technique for identification of mycoplasmas by use of fluorescent antibody. *App. Microbiol.* 23: 1097-1100.

2. BARILE, MICHAEL F. 1973. Mycoplasmal flora of simians. J. Infect. Dis., 127 Supplement: S17-S20.
3. BREED, R. S., E. G. D. MURRAY and N. R. SMITH. 1957. *Bergey's Manual of Determinative Bacteriology*, 7th Edition p. 395. The Williams and Wilkins Co., Baltimore.
4. COLE, BARRY C., JOHN R. WARD, LAURA GILIGHTLY-ROWLAND and CHARLES E. GRAHAM. 1970. Characterization of mycoplasmas isolated from the great apes. Can. J. Microbiol. 16: 1331-1339.
5. HILL, A. 1972. The isolation of *Mycoplasma arginini* from captive wild cats. Vet. Rec. 91: 224-225.
6. KLINGER, K., 1971. Gernsblindheit. Schweizerjagen, 19: 377-383.
7. LANGFORD, E. V. and W. J. DORWARD. 1969. A mycoplasma isolated from cattle with infectious bovine kerato-conjunctivitis. Can. J. comp. Med. 33: 275-279.
8. SHEPARD, MAURICE C. and CARL D. LUNCEFORD. 1970. Urease color test medium U-9 for the detection and identification of "T" mycoplasmas in clinical material. Appl. Microbiol. 20: 539-543.
9. TAN, R. J. S., G. P. DAVEY and JOHN M. B. SMITH. 1971. A strain of mycoplasma from the short-eared European hedgehog (*Erinaceus europaeus*). Res. vet. Sci. 12: 390-391.
10. TESSLER, J. 1973. Incident light immunofluorescence of alcohol fixed colonies of ruminant mycoplasma. Can. J. comp. Med. 37: 207-209.
11. THOMAS, L. H. and G. SMITH. 1972. Distribution of mycoplasmas in the non-pneumonic bovine respiratory tract. J. comp. Path. 82: 1-4.
12. WOOLF, ALAN, DAVID C. KRADEL and GEORGE R. BUBASH. 1970. Mycoplasma isolates from pneumonia in captive Rocky Mountain bighorn sheep. J. Wildl. Dis. 6: 169-170.

Received for publication 3 April 1974