



**ADIASPIROMYCOSIS IN THE FRANKLIN'S GROUND SQUIRREL,
Spermophilus franklini, AND PIKA, Ochotona princeps, FROM ALBERTA,
CANADA 1**

Authors: JORGE L. TOBON, THOMAS M. YUILL, and WILLIAM M. SAMUEL

Source: Journal of Wildlife Diseases, 12(1) : 97-100

Published By: Wildlife Disease Association

URL: <https://doi.org/10.7589/0090-3558-12.1.97>

BioOne Complete (complete.BioOne.org) is a full-text database of 200 subscribed and open-access titles in the biological, ecological, and environmental sciences published by nonprofit societies, associations, museums, institutions, and presses.

Your use of this PDF, the BioOne Complete website, and all posted and associated content indicates your acceptance of BioOne's Terms of Use, available at www.bioone.org/terms-of-use.

Usage of BioOne Complete content is strictly limited to personal, educational, and non-commercial use. Commercial inquiries or rights and permissions requests should be directed to the individual publisher as copyright holder.

BioOne sees sustainable scholarly publishing as an inherently collaborative enterprise connecting authors, nonprofit publishers, academic institutions, research libraries, and research funders in the common goal of maximizing access to critical research.

ADIASPIROMYCOSIS IN THE FRANKLIN'S GROUND SQUIRREL, *Spermophilus franklini*, AND PIKA, *Ochotona princeps*, FROM ALBERTA, CANADA¹

JORGE L. TOBON² and THOMAS M. YUILL³ Department of Veterinary Science,
University of Wisconsin, Madison, Wisconsin 53706, USA

WILLIAM M. SAMUEL, Department of Zoology, University of Alberta,
Edmonton, Alberta, Canada

Abstract: Pulmonary adiaspiromycosis due to *Emmonsia crescens* was diagnosed in three of six Franklin's ground squirrels (*Spermophilus franklini*) captured in Rochester, central Alberta, Canada in the summer of 1971, and in one of 240 pikas (*Ochotona princeps*) collected in southwestern Alberta in 1969. Granulomas measuring 0.5 to 1 mm in diameter were found in both lungs. These granulomas contained adiaspores measuring 60 to 400 μ m in diameter. The disease was not found in six Franklin's ground squirrels collected in 1964, nor in 10 white-footed mice (*Peromyscus maniculatus*), one porcupine (*Erethizon dorsatum*), and 270 snowshoe hares (*Lepus americanus*) from the Rochester area. Lungs from an additional 17 hares from Alaska and 25 from New Brunswick and 96 pikas from Colorado were also examined but no adiaspores were found.

INTRODUCTION

Adiaspiromycosis (formerly haplomycosis) is a mycotic infection of many wild mammals and man throughout the world.^{13,14} The etiologic agent is *Emmonsia crescens*.^{8,9} This organism has a broad host range and has been reported from mammals in five orders.¹⁴ Adiaspiromycosis has been found in the Franklin's ground squirrel (*Spermophilus franklini*) in North Dakota, and the pika (*Ochotona princeps*) in Montana.¹⁴ Although *E. crescens* frequently has been reported from rodents in Alberta⁷ and other areas in Canada, adiaspiromycosis had not been reported previously from the Franklin's ground squirrel nor the pika there. This is the first report of *E. crescens* infection in these two species in Canada.

MATERIALS AND METHODS

During the study of pulmonary disease of snowshoe hares (*Lepus americanus*), lungs were examined from 270 hares from Rochester, Alberta, (54°27'N, 113°32'W) collected from 1964 through 1972 (most in 1971-72). An additional 17 lungs from hares from Alaska and 35 from New Brunswick collected in 1972 were studied. During this period, tissue from a small number of other mammals in the Rochester area were also examined, including 12 Franklin's ground squirrels, 10 white-footed mice (*Peromyscus maniculatus*), and one porcupine (*Erethizon dorsatum*).

In the summer of 1969, 240 pikas were collected on Plateau Mountain (50°

¹ This study was conducted as part of the University of Wisconsin-Universidad de Antioquia (Colombia) research and training program and was financed in part by grant CB-12631 of the National Science Foundation and by the College of Agricultural and Life Sciences, University of Wisconsin.

² Present address: Facultad de Medicina Veterinaria y Zootecnia, Universidad de Antioquia, Medellin, Colombia.

³ Send reprint requests to T. M. Yuill.

12°N, 114°30'W) and the lungs examined. An additional 96 pikas were also collected near Gunnison, Gothic Co., Colorado.

Sections of lungs from all the animals, and the liver and kidneys from several, were fixed either in formalin or Bouin's solution and processed following routine histologic techniques. Fixation precluded later isolation attempts; thus hematoxylin and eosin (H and E) and special stains were prepared (periodic acid Schiff (PAS) and Gridley's) and examined by standard and polarized light microscopy to identify the organism.

CASE HISTORIES

Adiaspores of *E. crescens* were found in three Franklin's ground squirrels captured during the summer of 1971 and in one pika collected in 1969.

Case #1. Adult female squirrel, weight 362 gm. Several white subpleural foci, 0.5 to 1 mm in diameter, were found in all pulmonary lobes. Granulomas (Fig. 1) composed of reticuloendothelial cells (Fig. 2) mononuclear cells and fibroblasts were scattered throughout the lung tissue. An adiaspore was present in the centre of many of the granulomas. These

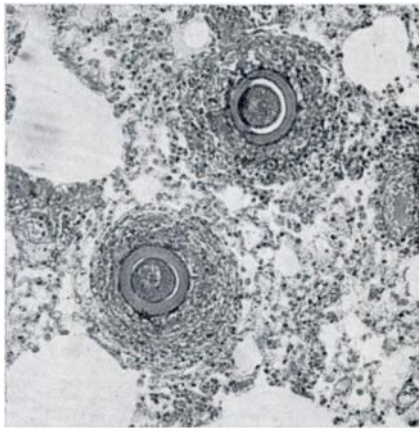


FIGURE 1. Two adiaspores of *Emmonsia crescens* in the lung of a Franklin's ground squirrel. Note nodular arrangement of the lesion. H and E stain, x 100.

adiaspores measured 60 to 250 μm (mean 120 μm) in diameter with a pinkish-blue (H and E stain), PAS-positive wall 7 to 14 μm (mean 11 μm) thick (Fig. 3). The center of the adiaspore was composed of a round blue (H and E) granular structure 28 to 70 μm (mean 45 μm) in diameter. Other granulomas contained empty adiaspores (Fig. 4) or had neutrophils in a necrotic center (Fig. 5). Neither gross nor microscopic lesions were found in liver and kidneys.

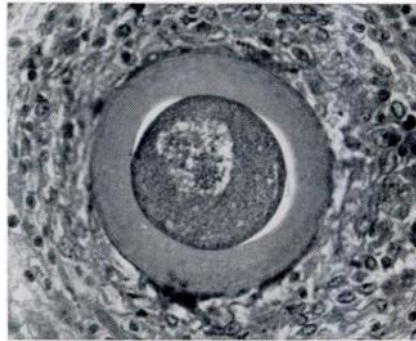


FIGURE 2. Lung granuloma containing one adiaspore of *Emmonsia crescens* surrounded by reticuloendothelial cells, mononuclear cells and fibroblasts (case 1). H and E stain, x 250.

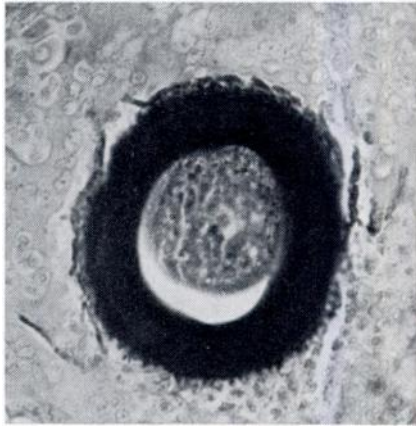


FIGURE 3. Adiaspore of *Emmonsia crescens* in the lung of a Franklin's ground squirrel. Foreign-body type giant cells, reticuloendothelial cells, and mononuclear cells are seen. Note smaller size of the adiaspore. H and E stain, x 400.

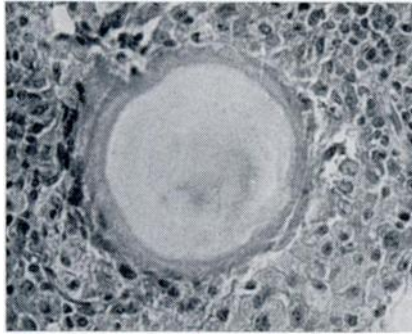


FIGURE 4. Adiaspore of *Emmonsia crescens* in the lung of a Franklin's ground squirrel. PAS positive wall, x 400.

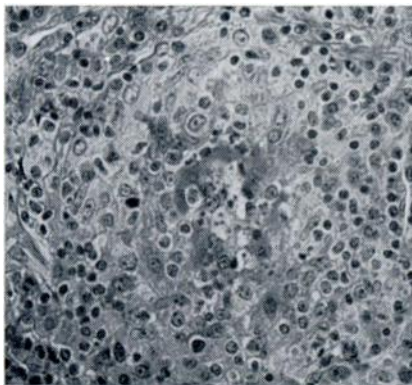


FIGURE 5. Empty adiaspore of *Emmonsia crescens* surrounded by reticuloendothelial cells and a few mononuclear cells. H and E stain, x 400.

Case #2. Adult male squirrel, weight 420 gm. Gross and microscopic lesions were essentially the same as in case 1. The diameter of the adiaspores ranged from 118 to 350 μm and the spore walls measured 10 to 15 μm in thickness. The staining characteristics were the same as in case 1. The kidneys and liver were normal by gross and microscopic examination.

Case #3. Adult male squirrel, weight 420 gm. Gross and microscopic findings were similar to the preceding cases. Adiaspores measured 200 to 400 μm in diameter and the walls 8 to 35 μm thick. The stain characteristics (H and E, and

PAS) were the same as the above. Adult pika lungs contained gross and microscopic lesions identical to those seen in the Franklin's ground squirrels. The adiaspores measured 240 μm in diameter and the 18 μm walls were PAS positive.

Adiaspores were not found in the lungs of the other species examined.

DISCUSSION

This is the second report of adiaspiromycosis in Franklin's ground squirrels. The gross lesions, the histological appearance, the size of the adiaspores, the thickness of their walls and their positive PAS reaction are compatible with a diagnosis of adiaspiromycosis caused by *E. crescens* and are similar to other reports of adiaspiromycosis in various animal species and man.^{4,15} Multiple white, subpleural, and intraparenchymal foci from 0.5 to 1 mm were found in all the pulmonary lobes of the ground squirrels. Similar "white discrete bodies" have been described in a rock rabbit,¹⁰ "pearl-like bodies" or "nodules" in a dog¹ and man.^{5,15} and "tubercles" in man.⁴

Microscopically, these foci in the ground squirrels were granulomas with a maximum diameter of 450 μm , composed of reticuloendothelial cells, foreign-body giant cells, mononuclear cells and in some instances eosinophiles. Adiaspores were found in the center of most of these granulomas. In some granulomas there were neutrophils in a necrotic center and no adiaspores (Fig. 5). Others have observed similar granulomas composed of epithelioid cells, foreign-body giant cells, mononuclear cells, scattered eosinophiles and fibroblasts with the adiaspore located in the center.^{2,6} In some granulomas no adiaspores were found and neutrophils were present in the central areas of necrosis.^{1,4}

The spherules in the lungs of the ground squirrels and pika were identical to the adiaspores of *E. crescens*,⁹ measuring 60 to 350 μ in diameter. The adiaspores had a PAS positive wall 7 to 15 μ thick. Although the reported size of the adiaspores has been highly variable, ranging from 37.5 to 700 μm ,^{9,11} it is larger than *E. parvum* (10 to 40 μm).⁹ The

wall of *E. crescens* has been described as PAS positive,¹² and containing cellulose lying in a protein matrix relatively free of phospholipids.³ This fungal body, which develops *in vivo* or *in vitro* at 37-40 C, was termed an adiaspore to indicate its remarkable growth without multiplication.⁹

Occurrence of *E. crescens* in both the Franklin's ground squirrel and the pika in Canada was not surprising. *Emmonsia* has been frequently reported in rodents from Alberta⁷ and other areas of Canada.⁹ Our observations extend the host range in Canada to include the pika and Franklin's ground squirrel.

Acknowledgements

Drs. L. B. Keith and J. S. Millar, Mrs. Dianne Mathison Fischer and R. P. Hobbs provided valuable assistance in the field. Dr. R. A. Dieterich and Mr. T. J. Wood contributed hare lung tissue from Alaska and New Brunswick. Dr. Louise Wipf, Mrs. Janice Lokken and H. Reynolds prepared tissues for histological study.

LITERATURE CITED

1. AL-DOORY, Y., T. E. VICE and M. E. MAINSTER. 1971. Adiaspiromycosis in a dog. *J. Am. vet. med. Ass.* 159: 87-90.
2. BAKERSPIGEL, A. 1965. Additional cases of adiaspiromycosis in Canadian rodents. *Sabouraudia* 4: 176-178.
3. BRESLAU, A. M. 1955. Comparative histochemical studies on *Coccidioides immitis* and *Haplosporangium parvum*. *J. Histochem. Cytochem.* 3: 141-147.
4. CUEVA, J. A. and M. D. LITTLE. 1971. *Emmonsia crescens* infection (adiaspiromycosis) in man in Honduras. *Am. J. Trop. Med. Hyg.* 20: 282-287.
5. DOBY-DUBOIS, M., M. L. CHEVREL, J. M. DOBY and J. LOUVET. 1964. Premier cas humain d'adiaspiromycose, par *Emmonsia crescens* Emmons et Jellison 1960. *Bull. Soc. Pathol. Exot.* 57: 240-244.
6. DOWDING, E. S. 1947. The pulmonary fungus *Haplosporangium parvum* and its relationship with some human pathogens. *Can. J. Res.* 25: 195-206.
7. ————. 1947. *Haplosporangium* in Canadian rodents. *Mycologia* 29: 372-373.
8. EMMONS, C. W. and L. L. ASHBURN. 1942. The isolation of *Haplosporangium parvum* n. sp. and *Coccidioides immitis* from wild rodents. Their relationship to coccidiomycosis. *Publ. Hlth. Rpts.* 57: 1715-1727.
9. ———— and W. L. JELLISON. 1960. *Emmonsia crescens* sp. n. and adiaspiromycosis (haplomycosis) in mammals. *Ann. NY Acad. Sci.* 89: 91-101.
10. JELLISON, W. L. 1947. An undetermined parasite in the lungs of a rock rabbit, *Ochotona princeps* Richardson (Lagomorpha: Ochotonidae). *Proc. Helm. Soc. Wash.* 14: 75-77.
11. ————. 1956. Haplomycosis in Sweden. *Nord. Vet. Med.* 8: 504-506.
12. ————, J. W. VINSON and K. BORG. 1961. Adiaspiromycosis (haplomycosis) in Sweden. *Acta. Vet. Scand.* 2: 178-184.
13. ———— and R. D. LORD. 1964. Adiaspiromycosis in Argentine mammals. *Mycologia* 56: 374-383.
14. ————. 1969. *Adiaspiromycosis* (= *Haplomycosis*). Mountain Press, Missoula, Montana, 99 pp.
15. KODOUSEK, R., V. VORTEL, A. FINGERLAND, V. VOJTEK, Z. SERY, V. HAJEK and K. KUCERA. 1971. Pulmonary adiaspiromycosis in man caused by *Emmonsia crescens*: Report of a unique case. *Am. J. Clin. Path.* 56: 394-399.

Received for publication 5 May 1975