



SYSTEMIC PHYCOMYCOSIS AND MULTIPLE FIBROMAS IN A GRAY SQUIRREL (*Sciurus carolinensis*)

Authors: NOVILLA, MELITON N., FLYGER, VAGN, JACOBSON,
ELLIOTT R., DUTTA, SUKANTA K., and SACCHI, EDOARDO M.

Source: Journal of Wildlife Diseases, 17(1) : 89-95

Published By: Wildlife Disease Association

URL: <https://doi.org/10.7589/0090-3558-17.1.89>

BioOne Complete (complete.BioOne.org) is a full-text database of 200 subscribed and open-access titles in the biological, ecological, and environmental sciences published by nonprofit societies, associations, museums, institutions, and presses.

Your use of this PDF, the BioOne Complete website, and all posted and associated content indicates your acceptance of BioOne's Terms of Use, available at www.bioone.org/terms-of-use.

Usage of BioOne Complete content is strictly limited to personal, educational, and non - commercial use. Commercial inquiries or rights and permissions requests should be directed to the individual publisher as copyright holder.

BioOne sees sustainable scholarly publishing as an inherently collaborative enterprise connecting authors, nonprofit publishers, academic institutions, research libraries, and research funders in the common goal of maximizing access to critical research.

SYSTEMIC PHYCOMYCOSIS AND MULTIPLE FIBROMAS IN A GRAY SQUIRREL (*Sciurus carolinensis*)

MELITON N. NOVILLA,¹ VAGN FLYGER,² ELLIOTT R. JACOBSON,³ SUKANTA K. DUTTA⁴ AND EDOARDO M. SACCHI⁵

Abstract: Phycomycosis (mucormycosis) was diagnosed in a 17-month old female gray squirrel. Characteristic fungal organisms were demonstrated in abscesses in the skin and lungs. The squirrel also had multiple fibromas in the skin from which a poxvirus was isolated.

INTRODUCTION

Phycomycosis (mucormycosis) refers to infection with fungi of the genera *Mucor*, *Rhizopus*, and *Absidia* of the family Mucoraceae. These fungal species are ubiquitous in nature and considered secondary invaders rather than primary disease agents.^{3,7} They rarely produce disease; and, lesions are frequently incidental findings at necropsy, unrelated to the cause of death.^{7,16,17} In man, infection sometimes follows antibiotic therapy.^{1,6} Mucormycosis has been reported in food-producing animals,¹ companion and laboratory animals^{5,17} as well as marine mammals.¹⁹

As far as can be determined, there is only one record of mucormycosis which contributed to the demise of a gray squirrel.¹⁶ The purpose of this paper is to report the occurrence of mucormycosis superimposed on multiple fibromas in a gray squirrel.

CASE HISTORY

A female gray squirrel acquired locally as a nestling in August, 1974 was raised

as an indoor pet and released into the owner's yard in the fall of 1975. Shortly after its reappearance a "wart-like" growth was noticed on the squirrel. Additional growths developed soon thereafter.

The moribund animal was seen by two of us (VF and ERJ) and clinical inspection revealed multiple nodules, scratches and pustules on the skin. A diagnosis of squirrel fibroma and pustular dermatitis was made. The animal died the following day (11 January). The only treatment given was bathing with a povidone-iodine⁵ shampoo.

PATHOLOGY

At necropsy, many grayish-white, firm nodules ranging in size from 0.5-2.5 cm in diameter were on the skin (Figure 1). Some of the masses on the feet were superficially ulcerated, and a few nodules on the neck (notably on the left prescapular area) had cheesy exudate. Internally, the liver was dark and turgid; two nodules about 2 cm in diameter were found in the lungs.

¹ Department of Pathology, Lilly Research Laboratories, P.O. Box 708, Greenfield, Indiana 46140, USA.

² Department of Animal Sciences, University of Maryland, College Park, Maryland 20742, USA.

³ Department of Veterinary Science, University of Maryland, College Park, Maryland 20742, USA.

⁴ Central Animal Health Laboratory, Maryland Department of Agriculture, College Park, Maryland 20740, USA.

⁵ BETADINE® Purdue Frederick Company, Norwalk, Connecticut 06856, USA.

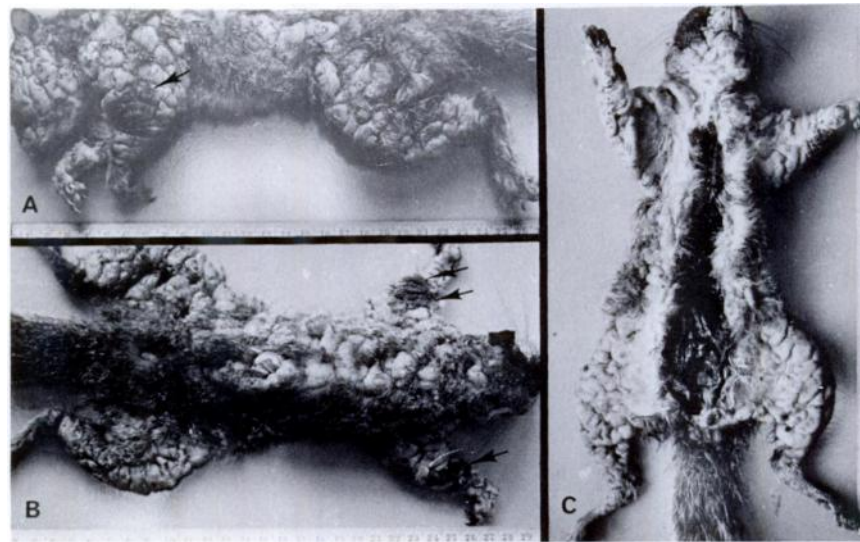


FIGURE 1. Naturally occurring fibromas in a gray squirrel. Left lateral (A), dorsal (B), and ventral views (C). Arrows point to scabs.

Tissues, including brain, liver, lungs, spleen, heart, skeletal muscle, adrenal, pancreas, and gastro-intestinal tract were collected in 10% buffered neutral formalin solution. Tissues were processed, sectioned at 6 μ m, and stained routinely with hematoxylin and eosin (HE). Selected tissues were stained with Gomori methenemine silver (GMS), toluidine blue, and Verhoeff-Van Gieson stains. Histologically, skin sections stained with HE had acanthosis and hyperkeratinization, especially over the cutaneous growths (Figure 2). The epidermal lesions generally were associated with whorls and bundles of proliferating fibroblasts in the dermis and subcutis. Occasionally, denudation of the epidermis was noted. Edema and ballooning degeneration of epidermal cells occurred in the stratum spinosum as well as in hair follicles and rete pegs deep in the dermis. Round to oval eosinophilic inclusion bodies were seen within the cytoplasm of many epidermal cells (Figure 3). In some cases the affected

epidermis covered abscesses associated with marked cellulitis and fungal organisms (Figure 4). The fungi were characterized by coarse, wide, non-septate branching hyphae and were most prominent in necrotic areas and in the walls and lumina of blood vessels. Similar organisms were found in the lungs and were easily demonstrated by the GMS stain. Focal areas of necrotizing pneumonia were associated with fungal hyphae (Figure 5). No substantive tissue alterations were present in the brain, liver, spleen, kidneys, heart, pancreas and gastro-intestinal tract.

MICROBIOLOGY

Bacteriologic cultures of the skin tumor yielded alpha streptococci. *Pseudomonas maltophilia*, *Escherichia coli*, and *Klebsiella pneumonia* were isolated from swabs of caseated masses. Fungi also grew in culture media but were discarded.

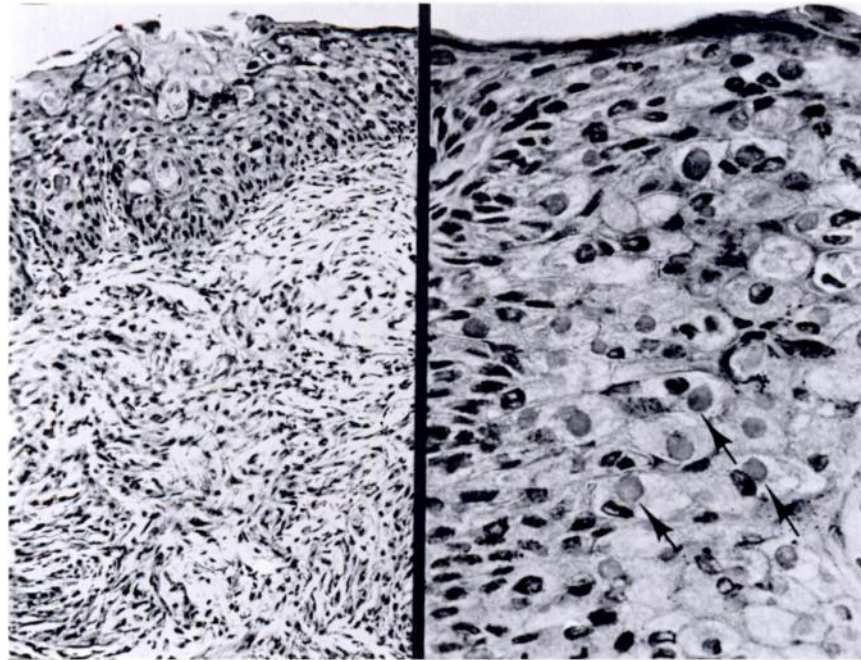


FIGURE 2, 3. Photomicrographs of a cutaneous nodule. Fig. 2 (left). Acanthosis of covering epidermis and proliferation of spindle-shaped fibroblastic cells in the dermis. HE $\times 100$. Fig. 3 (right). Higher magnification of epidermal lesion. Many large eosinophilic inclusion bodies (arrows) can be seen in the cytoplasm of epidermal cells. HE $\times 305$.

A 10% suspension of ground cutaneous nodules containing antibiotics (penicillin, streptomycin, gentamycin, and fungizone) was inoculated into primary squirrel kidney cell cultures. In the first passage there was a certain amount of CPE in the culture which increased considerably on second passage. On negative staining electron microscopy of lysed infected cells, particles resembling pox virus of approximately 340×270 nm size were identified (Figure 6).

DISCUSSION

The gross and microscopic features of the cutaneous nodules are similar to those described in reports of squirrel

fibroma.^{9,10,11,12} The only contact this squirrel had with other squirrels would have been during the month in the wild. The area where it had been released is a suburban community (Beltsville, Maryland) with many mature hardwood trees and an abundance of gray squirrels. Subsequently (4 February 1975) a wild squirrel with multiple fibromas was found within a quarter mile of the home of the squirrel in question. Although a variety of epithelial changes have been described for squirrel fibroma,⁹ only well-defined tumors with characteristic fibromatous changes were observed in the present case. The findings of intracytoplasmic inclusions and the isolation of a pox-like virus confirm the poxvirus origin of the fibromas.

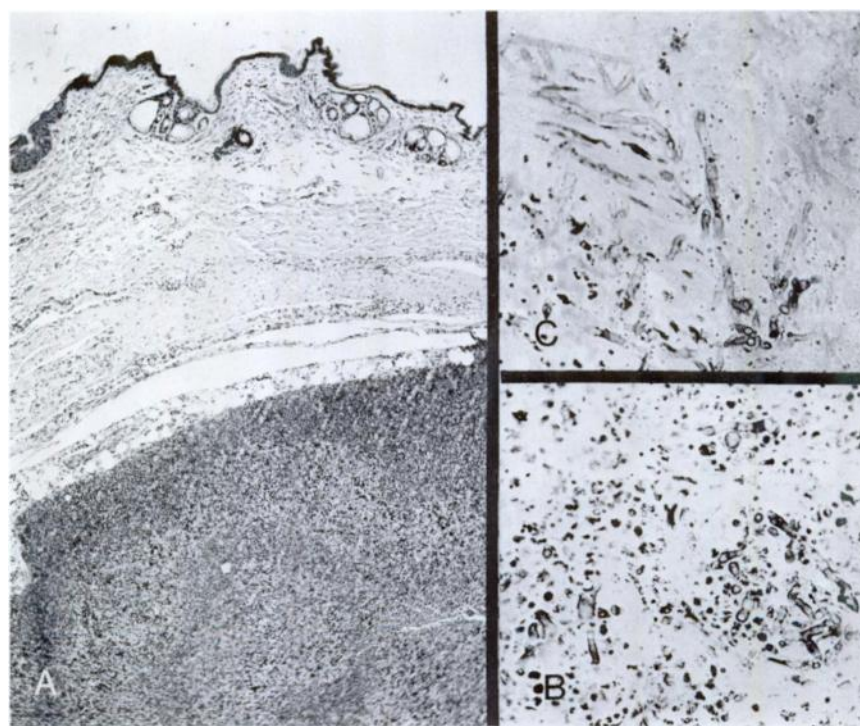


FIGURE 4. Section thru subcutaneous abscess (A). Note coarse branching hyphae in necrotic area (B) and in the wall of an arteriole (C). A = HE $\times 100$. B and C = toluidine blue stain $\times 305$.

Ulcerated squirrel fibromas can become infected with pathogenic bacteria or fungi.⁹ Cutaneous mucormycosis has been reported in the gray squirrel; and, the suggestion has been made that the fungal infection may have been superimposed upon some preexisting skin lesion such as squirrel fibroma.¹⁶ Our case confirms this possibility. The systemic dissemination of the fungal infection resulting in necrotizing pneumonia is very likely the major cause of death of the squirrel. Reports on predisposing factors for phycomycosis in animals are infrequent^{2,8,17} while malignant disease, uncontrolled diabetes mellitus, prolonged administration of corticosteroids or antibiotics, and leukopenia have been

documented as predisposing factors in man.^{2,4,15}

The Mucoraceae are ubiquitous fungi of low virulence. In a 1974 survey of fungal infections of 180 gray squirrels in Florida, *Mucor* sp. was cultured from 50 (9%) of 544 skin scrapings and 53 (13%) of 398 toenails.¹³ Only nine (5%) of the animals tested had skin lesions and *Mucor* sp. was isolated from one animal. Because of the omnipresent nature of these organisms, fungal cultures were initially considered contaminants and were subsequently discarded. The diagnosis of systemic mucormycosis was based on the characteristic morphology of the fungal organisms and the host tissue reaction in the skin and lungs.¹⁶

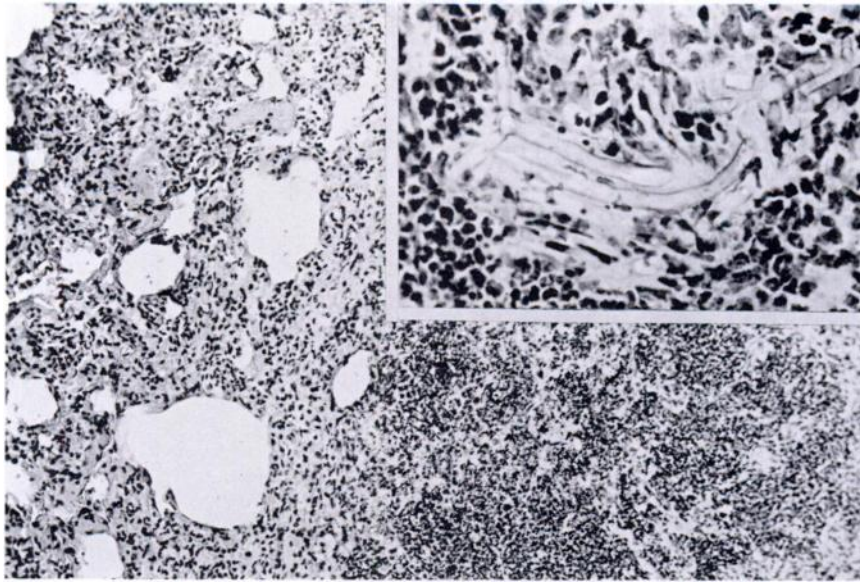


FIGURE 5. Section thru lung with severe focal necrotizing pneumonia. HE $\times 100$. Inset are fungal hyphae. HE $\times 395$.

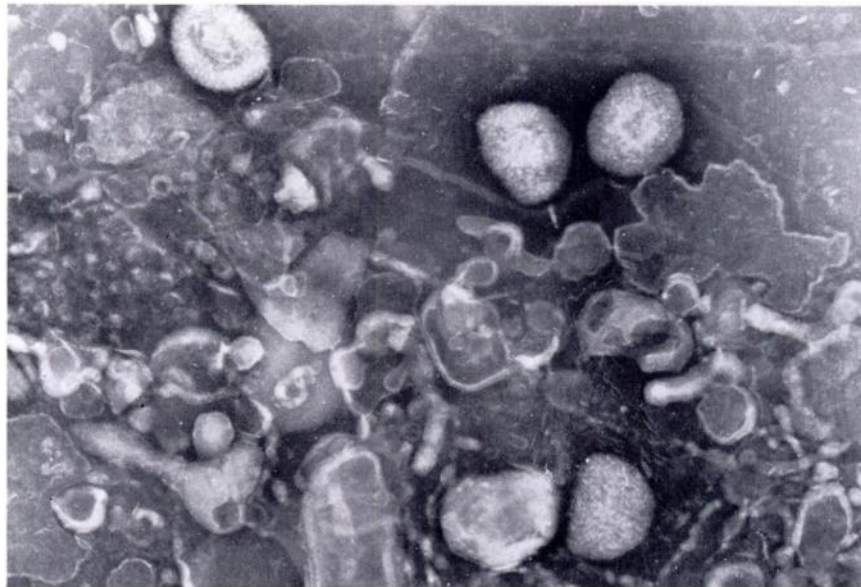


FIGURE 6. Electron micrograph of lysed infected cell culture with poxvirus particles. Negatively stained with PTA. $\times 35,000$.

Phycomycoses are usually diagnosed only on histopathologic examination.^{16,17}

Systemic fungal infections are difficult to treat. By the time the disease is recognized, lesions often are too widespread for effective treatment. Chemotherapy with potassium iodide, penicillin, streptomycin, and griseo-

fulvin were not effective in four dogs affected with phycomycosis.^{7,14} Amphotericin B, the most frequently used drug for the treatment of mycotic infections in small animals has not been tried in phycomycosis. Early diagnosis may enhance the success of treatment but extremely debilitated animals must be given a poor prognosis.¹⁸

Acknowledgements

The authors thank Dr. Peter Golway, private practitioner, for bringing this case to their attention, Dr. Robert P. Kwapien, formerly of the Department of Veterinary Pathology, Armed Forces Institute of Pathology, Washington, D.C. for the photomicrographs, and Dr. Glen C. Todd and Ms. Sharon Schortinghuis for the review and preparation of the manuscript.

LITERATURE CITED

1. BAKER, R.D. and A.O. SEVERANCE. 1948. Mucormycosis with report of acute mycotic pneumonia. *Am. J. Path.* 24: 716-717.
2. BAUER, H. and W.H. SHELDON. 1957. Leukopenia and experimental mucormycosis. *Am. J. Path.* 33: 617-618.
3. DAVIS, C.L., W.A. ANDERSON and B.R. MCCRORY. 1955. Mucormycosis in food producing animals. *J. Am. vet. med. Ass.* 126: 261-267.
4. EMMONS, C.W., C.H. BINFORD, J. P. UTZ and K.J. KWONG-CHUNG. 1977. *Medical Mycology*. 3rd ed. Lea and Febiger, Philadelphia. 592 pp.
5. FOX, J.G., J.C. MURPHY and M. SHALEV. 1978. Systemic fungal infections in cats. *J. Am. vet. med. Ass.* 173: 1191-1195.
6. GREGORY, J.E., A. GOLDEN and W. HAYMAKER. 1943. Mucormycosis of the central nervous system: a report of 3 cases. *Bull. Johns Hopkins Hosp.* 73: 405-419.
7. HELLER, R.A., H.P. HOBSON, C.M. GOWING, R.W. STORTS, W.K. READ and C.H. BRIDGES. 1971. Three cases of phycomycosis in dogs. *Vet. Med./Small Anim. Clin.* 66: 472-476.
8. HESSLER, J.R., J.C. WOODARD, R.J. BEATTIE and A.F. MOORELAND. 1967. Mucormycosis in a rhesus monkey. *J. Am. vet. med. Ass.* 151: 909-913.
9. HIRTH, R.S., D.S. WYAND, A.D. OSBORNE and C.N. BURKE. 1969. Epidermal changes caused by squirrel poxviruses. *J. Am. vet. med. Ass.* 155: 1120-1125.
10. KILHAM, L. 1955. Metastasizing viral fibromas of gray squirrels: pathogenesis and mosquito transmission. *Am. J. Hyg.* 61: 55-63.
11. ———, C.M. HERMAN and E.R. FISHER. 1953. Naturally occurring fibromas of gray squirrels related to Shope's rabbit fibroma. *Proc. Soc. Exptl. Biol. Med.* 82: 298-301.
12. KING, J.M., A. WOOLF and J.N. SHIVELY. 1972. Naturally occurring squirrel fibroma with involvement of internal organs. *J. Wildl. Dis.* 8: 321-324.
13. LEWIS, E., G.L. HOFF, W.J. BIGLER and M.B. JEFFRIES. 1975. Public health and the urban gray squirrel: mycology. *J. Wildl. Dis.* 11: 502-504.

14. LUCKE, V.M., D.G. MORGAN, M.P. ENGLISH and G.M. Endacott. 1969. Phycomycosis in a dog. *Vet. Rec.* 84: 645-646.
15. PARKHURST, G.F. and G.D. VLAHIDES. 1967. Fatal opportunistic fungus disease. *J. Am. med. Ass.* 202: 131-133.
16. SAUER, R.M. 1966. Cutaneous mucormycosis (phycomycosis) in a squirrel (*Sciurus carolinensis*). *Am. J. Vet. Res.* 27: 380-383.
17. SHALEV, M., J.C. MURPHY and J.G. FOX. 1977. Mycotic enteritis in a chameleon and a brief review of phycomycosis of animals. *J. Am. vet. med. Ass.* 171: 872-875.
18. SMALL, E. 1975. The Mycoses Pp. 181-202. In: *Textbook of Veterinary Internal Medicine*. Vol 1. S.J. Ettinger, Ed. W.B. Saunders Company, Philadelphia. 822 pp.
19. SWEENEY, J.C., G. MIGAKI, P.M. VAINIK and R.H. CONKLIN. 1976. Systemic mycoses in marine mammals. *J. Am. vet. med. Ass.* 169: 946-948.

Received for publication 1 August 1979
