

## **AN ANALYSIS OF BONY CHANGES FOLLOWING TRAUMA TO A BLACK BEAR MANDIBLE**

Author: D.L. DYER

Source: Journal of Wildlife Diseases, 17(1) : 97-100

Published By: Wildlife Disease Association

URL: <https://doi.org/10.7589/0090-3558-17.1.97>

---

BioOne Complete ([complete.BioOne.org](http://complete.BioOne.org)) is a full-text database of 200 subscribed and open-access titles in the biological, ecological, and environmental sciences published by nonprofit societies, associations, museums, institutions, and presses.

Your use of this PDF, the BioOne Complete website, and all posted and associated content indicates your acceptance of BioOne's Terms of Use, available at [www.bioone.org/terms-of-use](http://www.bioone.org/terms-of-use).

Usage of BioOne Complete content is strictly limited to personal, educational, and non-commercial use. Commercial inquiries or rights and permissions requests should be directed to the individual publisher as copyright holder.

---

BioOne sees sustainable scholarly publishing as an inherently collaborative enterprise connecting authors, nonprofit publishers, academic institutions, research libraries, and research funders in the common goal of maximizing access to critical research.

## AN ANALYSIS OF BONY CHANGES FOLLOWING TRAUMA TO A BLACK BEAR MANDIBLE

D.L. DYER, Natural History Department, Ohio Historical Center, Interstate 71 and 17th Avenue, Columbus, Ohio 43211, USA.

**Abstract:** Gross bony changes following a bullet wound to the mandible of an Alaskan black bear (*Ursus americanus* Pallas) are described. Analysis of the mandible indicates that the bear lived 1-6 months following the injury and that it did not develop any major bacterial infection, unusual for such an injury.

### CASE REPORT

The carcass of a black bear (*Ursus americanus* Pallas) was found on 27 July 1978 by the author and J.R. Massey on a gravelly beach on the west shore of the Yukon River, Alaska, 4 m from the water's edge, near the mouth of Bear Creek, between Eagle Island and Bullfrog Island. The carcass was badly decomposed but the skull, mandibles, ribs and vertebrae were examined in an attempt to determine the cause of death.

All of the bones appeared normal, however examination of the left mandible revealed a considerable amount of the posterior portion of the body and ascending ramus missing (Fig. 1). The posterior portion of the mandible was probably shattered by a bullet because radiographs reveal many minute (1 mm or less) fragments of lead in the jaw (Fig 2), and two fragments of lead were recovered.

The bear, however, did not immediately die from this gunshot wound as evidenced by the proliferation of new bone, up to 3 mm thick, bordering the fracture margin in the body of the mandible (Fig. 1). The ascending ramus shows very little proliferation. It is estimated that the bear lived 1-6 months following the injury based upon the amount of bony, woven callus formed and by the small amount of callus replaced by lamellar bone. It is unknown what other wounds, if any, were received at the time of the mandibular injury or whether

associated wounds were the actual cause of death.

The bullet appears to have struck the posterior portion of the body of the mandible, extensively shattering this region, and the impact produced a complete fracture of the ascending ramus. Due to the mobility of the jaw in chewing, the fragments of the body of the mandible did not heal completely, resulting in the callous formation present. It also appears that the masseter muscle reestablished its point of attachment on what remained of its fossa on the ascending ramus.

At death, the bear was 5.5 years old, using the technique of counting the dentin layers of an upper incisor<sup>5</sup> and was a male.<sup>3</sup>

### DISCUSSION

This particular example of trauma to the mandible is of interest to those who have occasion to examine dried bone specimens, especially when attempting to determine if disease was present. Such an injury is very conducive to an exogenous bacterial bone infection,<sup>2</sup> especially in gunshot wounds, which can cause infection in the shortest possible time.<sup>1</sup> Fractures of the body of the mandible are usually associated with a tear in the oral mucous membrane, which allows a channel for the influx of microorganisms always present in the mouth.<sup>4</sup> Although the proliferation of

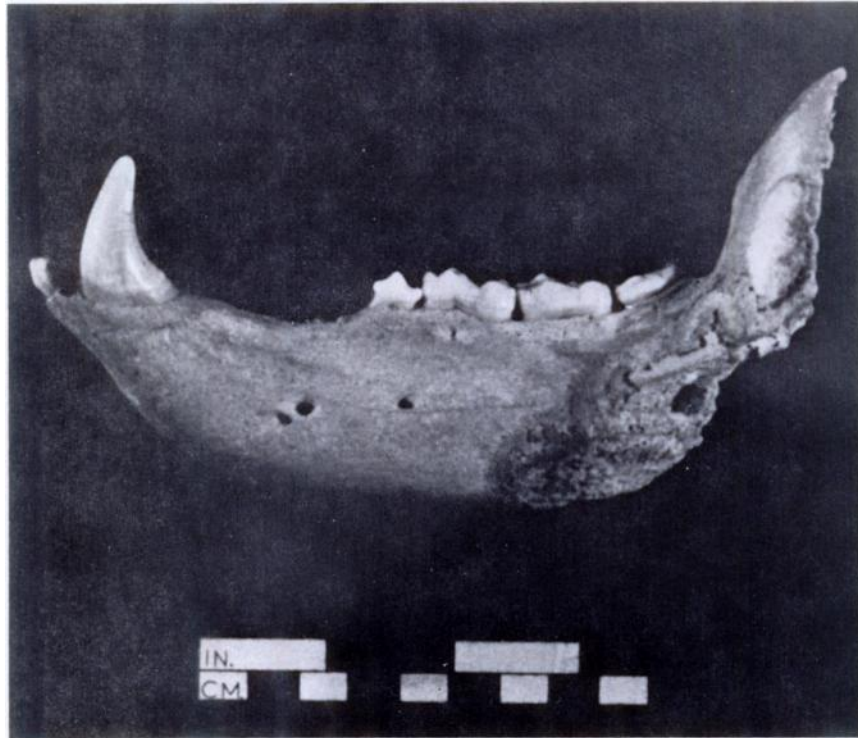


FIGURE 1. Lateral view of injured left mandible of *Ursus americanus* showing proliferation characteristic of healing bordering the missing area.

new woven bone is a characteristic response to osteomyelitis, and can be similar to proliferation during healing, the bony buildup in this specimen was determined to be normal callous formation associated with healing. The following characteristics indicate that no major bacterial bone infection was present: the localized foci of proliferation, no change in the temporomandibular joint, thus no spread of infection; no loosening of previously healthy teeth, a sign of spreading osteomyelitis;<sup>1</sup> the mental foramina are not enlarged, which would indicate hypervascularity to an infected site; no lytic bone is present; and no sequestra had formed (Dr. Owen Lovejoy, Biological Anthropologist, Kent State University, pers. commun.).

The partial obstruction of the respiratory passages due to the loss of support of the tongue at its anterior attachments can be a complication of mandibular injuries,<sup>2,1</sup> "especially those due to gunshot wounds."<sup>1</sup> However, bleeding is an unusual complication of most mandibular fractures. Severed vessels usually retract quickly into the bone and bleeding ceases.<sup>1</sup> Since the bear lived 1-6 months following the injury, it can be assumed that neither complication produced any major difficulties.

Lensink<sup>3</sup> described an Alaskan brown bear (*Ursus arctos*) in which the anterior portions of both mandibles (presumably including the mandibular symphysis) were shattered by a bullet. The bear survived for a year or more and was

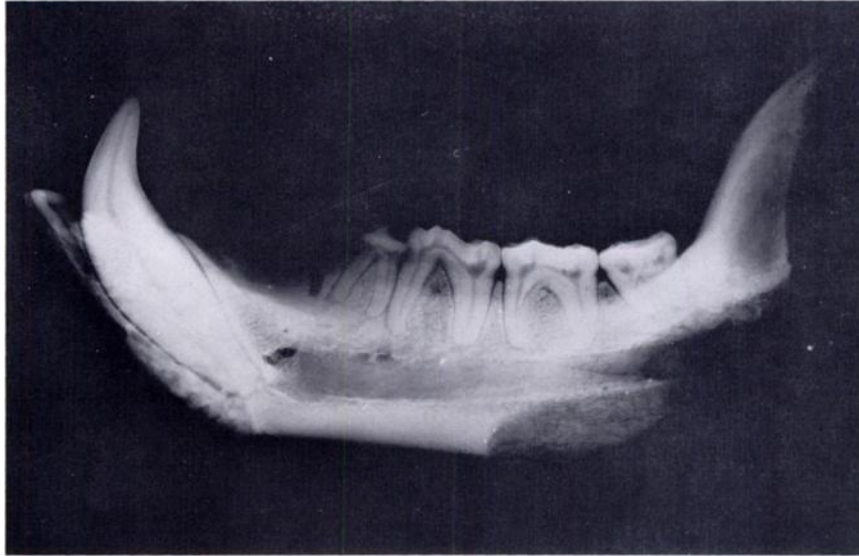


FIGURE 2. Radiograph (lateral view) of injured left mandible of *Ursus americanus*. Remains of the bullet show up as white flecks.

subsequently shot and killed. In the healing of this injury, the free ends of the mandibles "anastomosed and resulted in a jaw shortened by approximately one inch," with severe malocclusion. No differential wear was observed in the dentition of the black bear in this report, indicating that either no occlusal

anomalies resulted from the injury or the bear did not survive long enough to produce observable wear. Lensink's case, even with severe malocclusion, was "in good condition and had a 2-inch layer of fat covering most of its body." Thus the bear had no major problems in obtaining or consuming food.

#### Acknowledgements

I would like to thank: G.H. Dalrymple who edited the earlier versions of this manuscript, C.O. Lovejoy for his information on the specimen, the Ohio State University Veterinary Hospital who supplied the radiographs, J.M. Harold and D.L. Davids for their help and advice, and L.L. Bryant for her typing skills.

#### LITERATURE CITED

1. BURRI, C. 1975. *Post-traumatic Osteomyelitis*. Hans Huber Publishers, Bern, 304 pp.
2. ERICH, J.B. and L.T. AUSTIN. 1944. *Traumatic Injuries of Facial Bones*. W.B. Saunders Company, Philadelphia, 600 pp.
3. GORDON, K.R. and G.V. MOREJOHN. 1975. Sexing black bear skulls using lower canine and lower molar measurements. *J. Wildl. Manage.* 39: 40-44.
4. IVY, R.H. and L. CURTIS. 1931. *Fractures of the Jaws*. Lea and Febiger, Philadelphia, 180 pp.

5. LENSINK, C.J. 1954. Deformed jaw in an Alaskan brown bear (*Ursus*). *J. Mammal.* 35: 438-439.
6. RAUSCH, R.L. 1961. Notes on the black bear, *Ursus americanus* Pallas, in Alaska, with particular reference to dentition and growth. *Z. Säugetierkunde*, 26: 77-107.
7. STEINBOCK, R.T. 1976. *Paleopathological Diagnosis and Interpretation*. Charles C. Thomas Publisher, Springfield, Illinois, 423 pp.

*Received for publication 3 June 1980*

---