

THE OCCURRENCE OF A SPOROZOAN IN THE MYOCARDIUM OF SHORT-TAILED SHREW (*Blarina brevicauda*)

Author: J.E. HUFFMAN

Source: Journal of Wildlife Diseases, 17(2) : 209-211

Published By: Wildlife Disease Association

URL: <https://doi.org/10.7589/0090-3558-17.2.209>

BioOne Complete (complete.BioOne.org) is a full-text database of 200 subscribed and open-access titles in the biological, ecological, and environmental sciences published by nonprofit societies, associations, museums, institutions, and presses.

Your use of this PDF, the BioOne Complete website, and all posted and associated content indicates your acceptance of BioOne's Terms of Use, available at www.bioone.org/terms-o-use.

Usage of BioOne Complete content is strictly limited to personal, educational, and non - commercial use. Commercial inquiries or rights and permissions requests should be directed to the individual publisher as copyright holder.

BioOne sees sustainable scholarly publishing as an inherently collaborative enterprise connecting authors, nonprofit publishers, academic institutions, research libraries, and research funders in the common goal of maximizing access to critical research.

THE OCCURRENCE OF A SPOROZOAN IN THE MYOCARDIUM OF SHORT-TAILED SHREW (*Blarina brevicauda*)

J.E. HUFFMAN, [□] Biological Sciences, University of Connecticut, Storrs, Connecticut 06268, USA.

D.E. ROSCOE, [□] Northeast Research Center for Wildlife Diseases, University of Connecticut, Storrs, Connecticut 06268, USA.

Abstract: A cyst was observed in the cardiac musculature of a short-tailed shrew (*Blarina brevicauda*) during a survey on the helminth fauna of the species in Connecticut. Histologically this organism resembled a species of *Sarcocystis*.

INTRODUCTION

Blarina brevicauda, the short-tailed shrew, is an abundant insectivore in Connecticut. Literature on the parasites of the shrew in the continental United States has dealt primarily with descriptions of new helminth species. Surveys on the helminths of the short-tail shrew have been reported from central Ohio by Oswald,⁷ by Miller *et al.*⁶ in North Carolina, and by Wittrock and Hendrickson¹¹ in Iowa. In the course of a survey to document the helminth fauna of *B. brevicauda* in Connecticut a cyst typical of *Sarcocystis* was observed in the muscular tissue.

MATERIALS AND METHODS

Shrews were trapped using a small animal live trap,[□] in a forest habitat. Selected tissues (heart, liver, spleen, pancreas, lung and gonads) were fixed in 10% buffered formalin, routinely processed, embedded in paraffin, sectioned at 6 μ m and stained with hematoxylin and eosin. Myocardium containing cysts was stained by the periodic acid Schiff (PAS) technique.

RESULTS

Intramuscular cysts were observed in the cardiac muscle of a male shrew (Figure 1). The cysts contained well-developed bradyzoites in the central portion and merozoites were located at the periphery. The cysts were surrounded by a distinct wall which was PAS negative and smooth. This wall in turn was surrounded by muscle fiber. Organisms within the cysts were basophilic and the surrounding wall eosinophilic. Cysts varied in shape from round to slender and elongate. The size range of the cysts observed were 10 by 20 μ m to 50 by 75 μ m, the average size was 21.33 by 46.33 μ m. Fifteen cysts were observed in the heart muscle of the shrew. No inflammatory reaction to the cyst was evident, although infected muscle cells were distended and they impinged on neighboring cells in the bundle.

DISCUSSION

Tissue cyst-forming coccidia have similar characteristics and have been confused occasionally. The morphological characteristics of *Besnoitia*,

[□] Present address: Department of Zoology and Physiology, Rutgers University, Newark, New Jersey 07102, USA.

[□] Present address: New Jersey Division of Fish, Game and Shellfisheries, Clinton, W.M.A. Pathology Laboratory, Box 409, R.D., Hampton, New Jersey 08827, USA.

[□] Woodstream Corp., Box 3016 Lancaster, Pennsylvania 17604, USA.

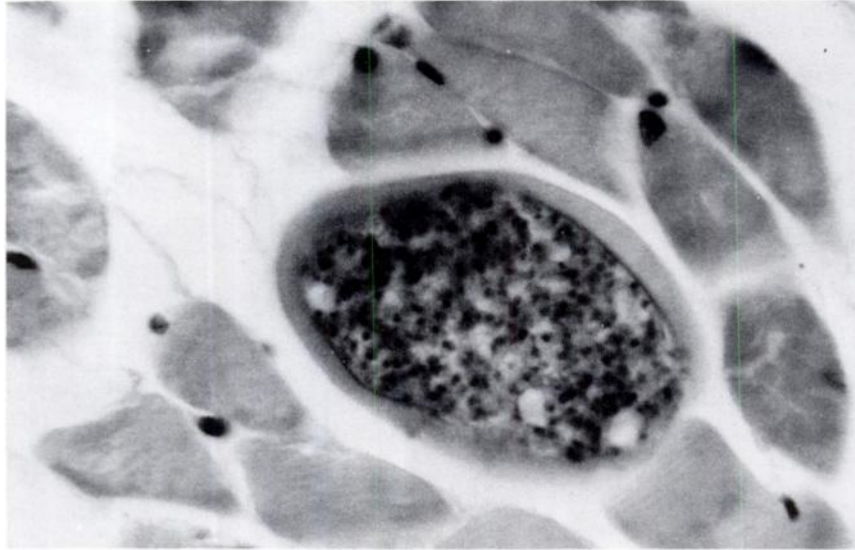


FIGURE 1. Sporozoan in the myocardium, 410 \times .

Hammondia, *Frenkelia*, and *Toxoplasma* do not conform to the characteristics observed in the cysts found in the shrew.

Cysts of *Sarcocystis* occur in striated and cardiac muscles of most cattle, sheep, swine, and many species of wildlife.² The cysts of *Sarcocystis* from cardiac and skeletal muscle are well known.² They vary in length from a few micrometers to several centimeters, depending on the host and parasite species. They are usually elongated and divided into compartments. The thickness and structure of the cyst walls may vary with each *Sarcocystis* species and within each species as the cyst matures. Two distinct regions can be recognized within the cyst proper. The peripheral region contains globular parasites, metrocytes, which give rise to banana-shaped bradyzoites. The metrocytes are surrounded by septa.¹

Besnoitia cyst walls are PAS negative, the cyst walls of *Sarcocystis* are argyrophilic, but PAS negative.³ The

cysts of *Hammondia hammondi*, found in skeletal muscle, do not form metrocytes and the cysts are aseptate.^{1,4} In *Sarcocystis*, metrocytes are formed and the cysts do have septa.

Structurally, *Frenkelia* is related to *Sarcocystis*. The cysts of *Frenkelia microti* are lobulated and thin walled and occur primarily in the brains of field voles, meadow mice and muskrats.¹ The metrocytes and bradyzoites resemble structurally those of *Sarcocystis*.^{8,9} The cysts recovered from the shrew were from the heart and not lobulated.

Frenkel³ stated that *Sarcocystis* has been confused with *Toxoplasma*. However, in *Toxoplasma* the cysts are aseptate whereas those of *Sarcocystis* are septate.¹

A comparison of the characteristics of the sporozoan observed in the cardiac muscle of the shrew, with that of similar coccidia, showed that it was typical of *Sarcocystis*. This organism has not been reported previously from the short-tailed shrew.

Acknowledgement

We wish to thank Dr. R. Fayer, Animal Parasitology Institute, USDEA-SEA, Beltsville, Maryland for assistance in the review of the case material.

LITERATURE CITED

1. DUBEY, J.P. 1977. *Toxoplasma, Hammondia, Besnoitia, Sarcocystis*, and other tissue cyst-forming coccidia of man and animals. In: *Parasitic Protozoa*, J.P. Kreizer, Ed., Vol. III, Academic Press, New York, pp. 101-237.
2. FAYER, R. and A.J. JOHNSON. 1974. *Sarcocystis fusiformis*: Development of cysts in calves infected with sporocysts from dogs. *Proc. Helm. Soc. Wash.* 41: 105-108.
3. FRENKEL, J.K. 1956. Pathogenesis of toxoplasmosis and of infections with organisms resembling *Toxoplasma*. *Ann. N.Y. Acad. Sci.* 64: 215-251.
4. ——— and J.P. DUBEY. 1975. *Hammondia hammondi*: A new coccidium of cats producing cysts in muscle of other mammals. *Science* 189: 222-224.
5. LEVINE, N.D. 1973. *Protozoan Parasites of Domestic Animals and of Man*. Burgess, Minneapolis. 406 pp.
6. MILLER, G.C., R.L. PRICE and D.A. WILSON. 1974. Helminths of the short-tailed shrew, *Blarina brevicauda*, in North Carolina. *J. Parasit.* 60: 523-524.
7. OSWALD, V.H. 1958. Helminth parasites of the short-tailed shrew in Central Ohio. *Ohio J. Sci.* 58: 323-334.
8. SCHOLTYSECK, E. 1973. Ultrastructure. In: *The Coccidia*. D.M. Hammond and P.L. Long, Eds., University Park Press, Baltimore, Maryland, pp. 101-237.
9. TADROS, W.A., R.G. BIRD and D.S. ELLIS. 1972. The fine structure of cysts of *Frenkelia* (the M-organism). *Fol. Parasitol.* 19: 203-209.
10. WALLACE, S.D. and J.K. FRENKEL. 1975. *Besnoitia* species (Protozoa, Sporozoa, Toxoplasmatidae): Recognition of cyclic transmission of cats. *Science* 188: 369-371.
11. WITROCK, D.D. and G.L. HENDRICKSON. 1979. Helminths of shrews, *Blarina brevicauda* and *Sorex cinereus*, in Iowa. *J. Parasit.* 65: 985-986.

Received for publication 5 May 1980