



MORTALITY IN ROBINS (*Turdus migratorius*) DUE TO AVIAN MALARIA 1

Author: BEIER, JOHN C.

Source: Journal of Wildlife Diseases, 17(2) : 247-250

Published By: Wildlife Disease Association

URL: <https://doi.org/10.7589/0090-3558-17.2.247>

BioOne Complete (complete.BioOne.org) is a full-text database of 200 subscribed and open-access titles in the biological, ecological, and environmental sciences published by nonprofit societies, associations, museums, institutions, and presses.

Your use of this PDF, the BioOne Complete website, and all posted and associated content indicates your acceptance of BioOne's Terms of Use, available at www.bioone.org/terms-of-use.

Usage of BioOne Complete content is strictly limited to personal, educational, and non - commercial use. Commercial inquiries or rights and permissions requests should be directed to the individual publisher as copyright holder.

BioOne sees sustainable scholarly publishing as an inherently collaborative enterprise connecting authors, nonprofit publishers, academic institutions, research libraries, and research funders in the common goal of maximizing access to critical research.

MORTALITY IN ROBINS (*Turdus migratorius*) DUE TO AVIAN MALARIA[□]

JOHN C. BEIER,[□] Department of Pathobiology, The Johns Hopkins University, School of Hygiene and Public Health, 615 N. Wolfe St., Baltimore, Maryland 21205, USA.

JOHN STRANDBERG, MICHAEL K. STOSKOPF and CAROLYN CRAFT, Division of Comparative Medicine and Department of Pathology, The Johns Hopkins Medical Institutions, Baltimore, Maryland 21205, USA.

Abstract: Two juvenile robins (*Turdus migratorius*) died shortly after being captured in Baltimore, Maryland. Both had high erythrocytic parasitemias of mixed *Plasmodium* infections. Postmortem examination revealed large numbers of exoerythrocytic malarial schizonts in the liver, spleen, lungs and brain of both cases. Avian malaria was considered the primary cause of death.

INTRODUCTION

Though avian malaria is common in North American wild birds,⁶ the potential of this disease as a cause of death in avian populations is not well documented.⁷ Few reports attribute mortality in wild birds to avian malaria.^{1,3} This report documents avian malaria as the cause of death in two wild robins (*Turdus migratorius*).

CASE HISTORIES

Case 1. A juvenile robin which appeared to be weak and gasping for breath was captured by hand on the grounds of the Baltimore Zoo on 29 August 1979. Blood obtained immediately from the tarsal vein was thin and had a milky appearance. This bird died approximately 10 min later.

Necropsy examination revealed emaciation, with a generalized pallor of the musculoskeletal system. The lungs were dark pink-red with interstitial pneumonia. The liver was dark brown, enlarged, and had rounded edges. The

spleen was dark brown, and enlarged approximately 10 times normal size.

Antemortem blood smears contained a 39% parasitemia with characteristic stages of *Plasmodium relictum*, another *Plasmodium* sp. with elongate gametocytes and *Haemoproteus fallisi*. Asexual stages of *P. relictum* were by far the most frequent forms encountered. The identity of the second *Plasmodium* sp. remains in question due to the absence of clear-cut schizont stages. Relatively few gametocytes of *H. fallisi* were found. Parasites were identified by Dr. G.F. Bennett (International Reference Centre for Avian Haematozoa, Memorial University of Newfoundland, St. John's, Nfld.) and slides were deposited in the reference collection (Accession #76766).

Tissue smears and sections revealed exoerythrocytic stages of *Plasmodium* sp. in the brain, lungs, spleen, liver and bone marrow. The brain was heavily parasitized and contained from 1 to 6 exoerythrocytic schizonts per oil immersion field (Fig. 1). Parasites in brain

[□] This research was supported by the Baltimore Zoological Society, the Frank M. Chapman Fund of the American Museum of Natural History, and by Training Grant Number 1T32AI07168 from the National Institute of Allergy and Infectious Diseases.

[□] Present address: Vector Biology Laboratory, Department of Biology, University of Notre Dame, Notre Dame, Indiana 46556, USA.

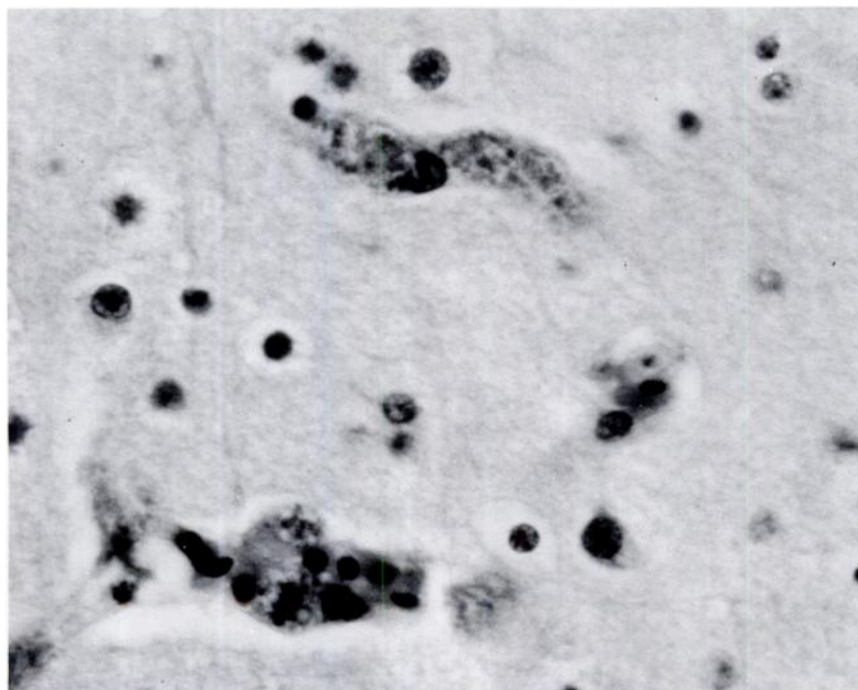


FIGURE 1. Exoerythrocytic malarial schizonts in capillary endothelial cells of the brain. 1000 \times .

tissue were located in the capillary endothelial cells. Reticuloendothelial hyperplasia was observed in both the liver and spleen. Both of these organs also contained abundant malarial pigment.

Case 2. A juvenile robin was captured in a mist net at the Baltimore Zoo on 4 September 1979. The bird was weak and died shortly after blood was obtained from the tarsal vein. The blood was thin and had a milky appearance on gross examination. This bird appeared emaciated and had a marked pallor of the pectoral muscles. There was marked hepatomegaly and splenomegaly.

Antemortem blood smears revealed a 35% parasitemia with characteristic stages of both *P. relictum* and *Plasmodium circumflexum* (Dr. G.F.

Bennett, Pers. Commun.). Schizonts and gametocytes of *P. relictum* were more numerous than those of *P. circumflexum*. Blood smears were deposited with the International Reference Centre for Avian Haematozoa (Accession #76767). Exoerythrocytic stages of *Plasmodium* sp. were numerous in the liver and spleen, but less common in the brain, lungs and heart.

DISCUSSION

Plasmodium infections have been reported infrequently as the cause of death in robins and other passeriformes.^{1,3} Even though malaria is a common avian disease, no reports document epizootic losses from this disease in natural wild bird populations.⁷ A poten-

tial for mortality is suggested by laboratory studies⁵ and by the effects of naturally transmitted malaria in non-indigenous or domestic hosts.^{4,5,10,11,12} It is important to determine the extent of mortality from this disease since it is generally felt that indigenous species are protected from fatal infection by immunity.⁷

The high parasitemias, abundant exoerythrocytic parasites and associated pathology identified in the two wild robins indicated that malaria was the primary cause of death. The light infection of *Haemoproteus fallisi* in one robin probably did not contribute to the death of the host since *Haemoproteus* infections are rarely pathogenic.⁸ The examination of histologic sections did not reveal any evidence of other pathogens or a toxin. Because the changes directly associated with the malarial infections were so severe and routine screening of sections did not suggest other pathogens, we did not attempt to isolate pathogens such as viruses, bacteria, fungi, other parasites or toxins. The lesions in these two birds were similar to the malarial lesions reported in other birds infected with the same *Plasmodium* spp.³ The circumstances in which these robins died suggest that both were fatally compromised prior to capture.

The mixed infections in juvenile robins most likely represent primary infections.

Since the birds were captured late in the summer they could have been either migrants or local residents which fledged on or near zoo grounds. Studies of avian malaria transmission to penguins at the Baltimore Zoo have shown that several species of *Plasmodium* are transmitted locally and there is a high prevalence of malaria in captive penguins as well as in the native birds.^{1,2,3} Wild birds nesting on the zoo grounds may be subjected to abnormally high transmission rates. If the two robins originated from the zoo area, then these cases may exemplify a situation infrequently encountered by native birds.

A high prevalence of malaria is found in robins and they frequently are infected with more than one species of *Plasmodium*.⁹ The intensity of parasitemia at the time of sampling indicates that both robins were experiencing peak levels of patency. Little is known about the pathogenesis of mixed malarial infections in wild juvenile birds. Probably, mixed *Plasmodium* infections act synergistically to potentiate the severity of disease.

This report substantiates that *Plasmodium* infections cause mortality in indigenous avian species. The potential of this disease as a mortality factor in free-ranging avian populations needs to be further explored to determine its extent.

Acknowledgements

We thank Dr. G.F. Bennett, Memorial University of Newfoundland, St. John's, Newfoundland, for reviewing the manuscript, for examining blood smears and for depositing slides in the International Reference Centre for Avian Haematozoa.

LITERATURE CITED

1. BEIER, J.C. 1980. The epidemiology of avian malaria in captive African penguins (*Spheniscus demersus*) at the Baltimore Zoo. Sc.D. Thesis. The Johns Hopkins University, Baltimore, Maryland. 220 pp.
2. ——— and M.K. STOSKOPF. 1981. The epidemiology of avian malaria in penguins. *J. Zoo Anim. Med.* (In Press).

3. ——— and M. TRPIS. 1981. Incrimination of natural culicine vectors which transmit *Plasmodium elongatum* to penguins at the Baltimore Zoo. *Can. J. Zool.* (In Press).
4. FLEISCHMAN, R.W., R.A. SQUIRE, W.J.L. SLADEN and E.C. MELBY. 1968. Malaria (*Plasmodium elongatum*) in captive African penguins (*Spheniscus demersus*). *J. Am. vet. med. Ass.* 153: 928-935.
5. GARNHAM, P.C.C. 1966. *Malaria Parasites and Other Haemosporidia*. Blackwell Scientific Publications, Oxford.
6. GREINER, E.C., G.F. BENNETT, E.M. WHITE and R.F. COOMBS. 1975. Distribution of the avian hematozoa of North America. *Can. J. Zool.* 53: 1762-1787.
7. HERMAN, C.M. 1968. Blood protozoa of free-living birds. *Symp. Zoo. Soc. London* 24: 177-195.
8. JULIAN, R.J. and D.E. GALT. 1980. Mortality in muscovy ducks (*Cairina moschata*) caused by *Haemoproteus* infection. *J. Wildl. Dis.* 16: 39-44.
9. MANWELL, R.D. and C.M. HERMAN. 1935. The occurrence of the avian malaras in nature. *Am. J. Trop. Med.* 15: 661-673.
10. MATHEY, W.J. 1955. Malaria in canaries. *Vet. Med.* 50: 369-370.
11. PURCHASE, H.S. 1942. Turkey malaria. *Parasitology* 34: 278-283.
12. RODHAIN, J. 1953. Les infections a *Plasmodium* chez des pingouins. *Bull. Soc. R. Zool. (Anvers)* 1: 1-24.
13. STONE, W.B., B.L. WEBER and F.J. PARKS. 1971. Morbidity and mortality of birds due to avian malaria. *N.Y. Fish and Game J.* 18: 62-63.

Received for Publication 26 August 1980
