



## **CONGENITAL BILATERAL METACARPAL DEVIATION AND MEDIAL PATELLAR LUXATION IN A YOUNG WHITE-TAILED DEER (*Odocoileus virginianus*) 1**

Authors: JOHN P. SUNDBERG, and SVEND W. NIELSEN

Source: Journal of Wildlife Diseases, 17(2) : 251-258

Published By: Wildlife Disease Association

URL: <https://doi.org/10.7589/0090-3558-17.2.251>

---

BioOne Complete ([complete.BioOne.org](http://complete.BioOne.org)) is a full-text database of 200 subscribed and open-access titles in the biological, ecological, and environmental sciences published by nonprofit societies, associations, museums, institutions, and presses.

Your use of this PDF, the BioOne Complete website, and all posted and associated content indicates your acceptance of BioOne's Terms of Use, available at [www.bioone.org/terms-o-use](http://www.bioone.org/terms-o-use).

Usage of BioOne Complete content is strictly limited to personal, educational, and non - commercial use. Commercial inquiries or rights and permissions requests should be directed to the individual publisher as copyright holder.

---

BioOne sees sustainable scholarly publishing as an inherently collaborative enterprise connecting authors, nonprofit publishers, academic institutions, research libraries, and research funders in the common goal of maximizing access to critical research.

## CONGENITAL BILATERAL METACARPAL DEVIATION AND MEDIAL PATELLAR LUXATION IN A YOUNG WHITE-TAILED DEER (*Odocoileus virginianus*)<sup>□</sup>

JOHN P. SUNDBERG<sup>□</sup> and SVEND W. NIELSEN, Northeastern Research Center for Wildlife Diseases, University of Connecticut, Storrs, Connecticut 06268, USA.

**Abstract:** A 6-week-old white-tailed deer fawn (*Odocoileus virginianus*), found in Vermont, was presented with carpal contraction, 90° medial deviation of the rear legs from the hock distally, and an abnormal coat color. Radiographically there was lateral deviation of both medial metacarpal bones and a Grade IV medial patellar luxation.

### INTRODUCTION

Congenital anomalies of all types are rarely reported in wildlife, probably reflecting the rapid disappearance of such animals from wild populations due to starvation and predation. Skeletal anomalies in white-tailed deer which are of minor consequence to the individual and are often seen at hunter check stations include brachygnathia<sup>1,5,7,10</sup> and polydactyly;<sup>6,8</sup> however, debilitating anomalies of the limbs rarely have been reported. These include, arthrogryposis,<sup>1</sup> bowing of the radius and ulna,<sup>1</sup> medial rotation of the distal part of both hind legs and left foreleg,<sup>10</sup> and coxofemoral luxation due to an enlarged femoral head.<sup>9</sup>

This report describes bilateral metacarpal deviation, medial patellar luxation, and abnormal hair coat colorations in a white-tailed deer fawn.

### CASE REPORT

On 6 July 1979, a live, male white-tailed deer fawn was found in Rutland County, Vermont. A doe was observed regularly in this area for 3 weeks after the

fawn had been removed. The doe's hair coat had an irregular white area that started on the anterior dorsal thorax and extended to the tail head and down both legs.

The fawn, estimated to be 6 weeks of age, was in good condition, alert, active, and would resist restraint. The carpal joints could not be fully extended. The rear legs were deviated 90° medially from the hock distally and could not be reduced to normal conformation. The hair coat had an abnormal coloration pattern, with a broad, irregular dorsal white area surrounded laterally by tan and spotted hair coat. The head and limbs had more white than normal (Fig. 1).

### GROSS PATHOLOGIC FINDINGS

Carpal joints were slightly swollen and covered by an ulcerated epidermis. The right carpus had a granulating circular ulcer, 7 mm in diameter. Lateral deviation of both medial metacarpal bones was evident radiographically (Fig. 2). Articular cartilages were unaffected. Gross examination of the bones revealed

<sup>□</sup> Scientific Contribution No. 824, Storrs Agricultural Experiment Station, University of Connecticut, Storrs, Connecticut 06268, USA.

<sup>□</sup> Supported by an E.I. Dupont-Haskell Laboratory Fellowship in Veterinary Pathology.

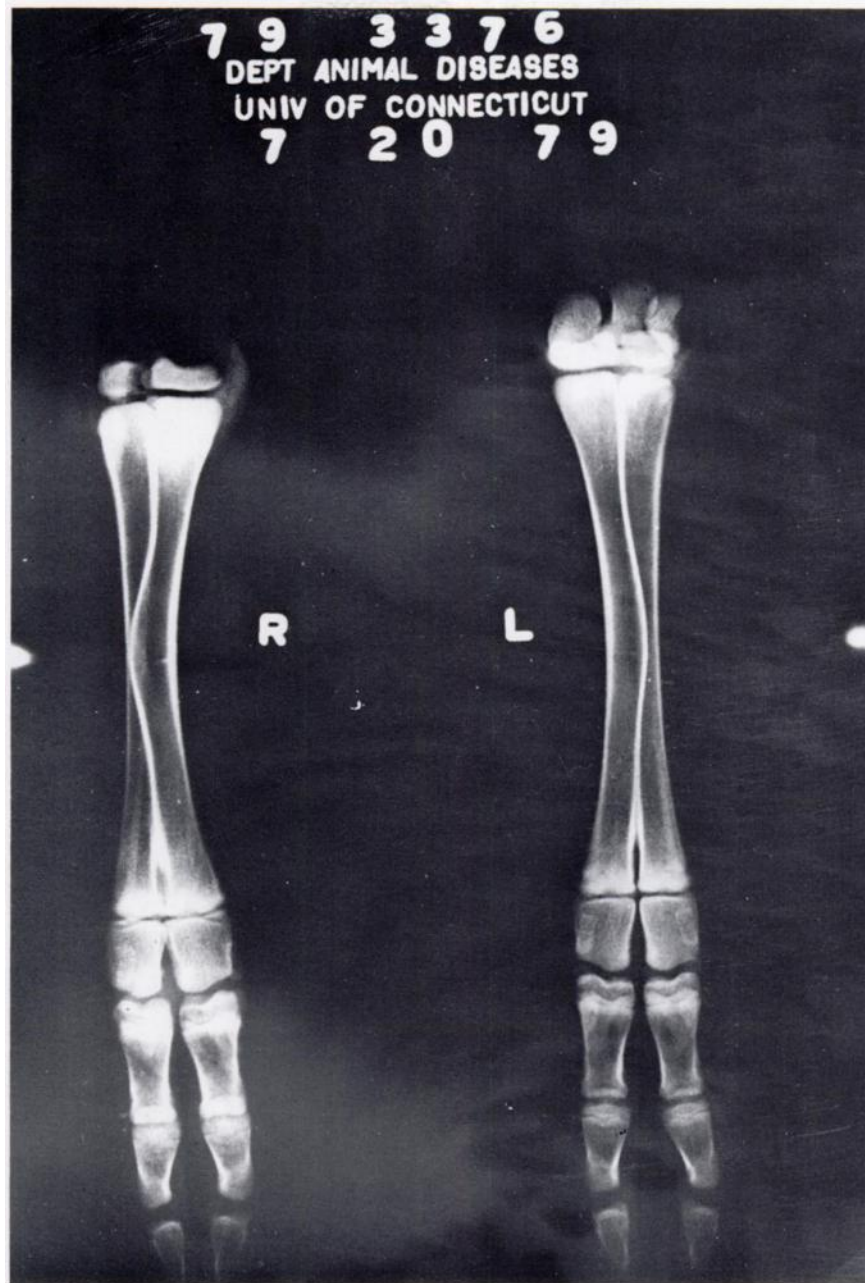


**FIGURE 1.** A 6-week-old male fawn with an excessive white hair coloration, partial contracture of the carpal joints, and medial crossing of the rear legs.

slight bowing laterally, but without deviation of the vascular grooves on either the dorsal or palmar surfaces (Fig. 3).

Palpation of the stifle joints revealed bilateral medial patellar luxation with a 90° internal rotation of the tibia. The trochlear grooves of both femurs were shallow and the patella could not be reduced manually to its normal anatomical location. The patella was

located within the tendon of insertion of the quadriceps which crossed the medial side of the stifle (Fig. 4). The patellar ligament inserted normally on the tibial tuberosity. Malalignment resulted in extensive remodeling of the articular surfaces and of the epiphysis of both femur and tibia (Figs. 5 and 6). Joints distal to the tibia were unaffected. The metatarsal bones were rotated slightly medially and the tibial rotation resulted in the medial



**FIGURE 2.** The anterior-posterior radiograph of the distal forelimb demonstrated lateral deviation of the midshaft of the medial metacarpal bones.

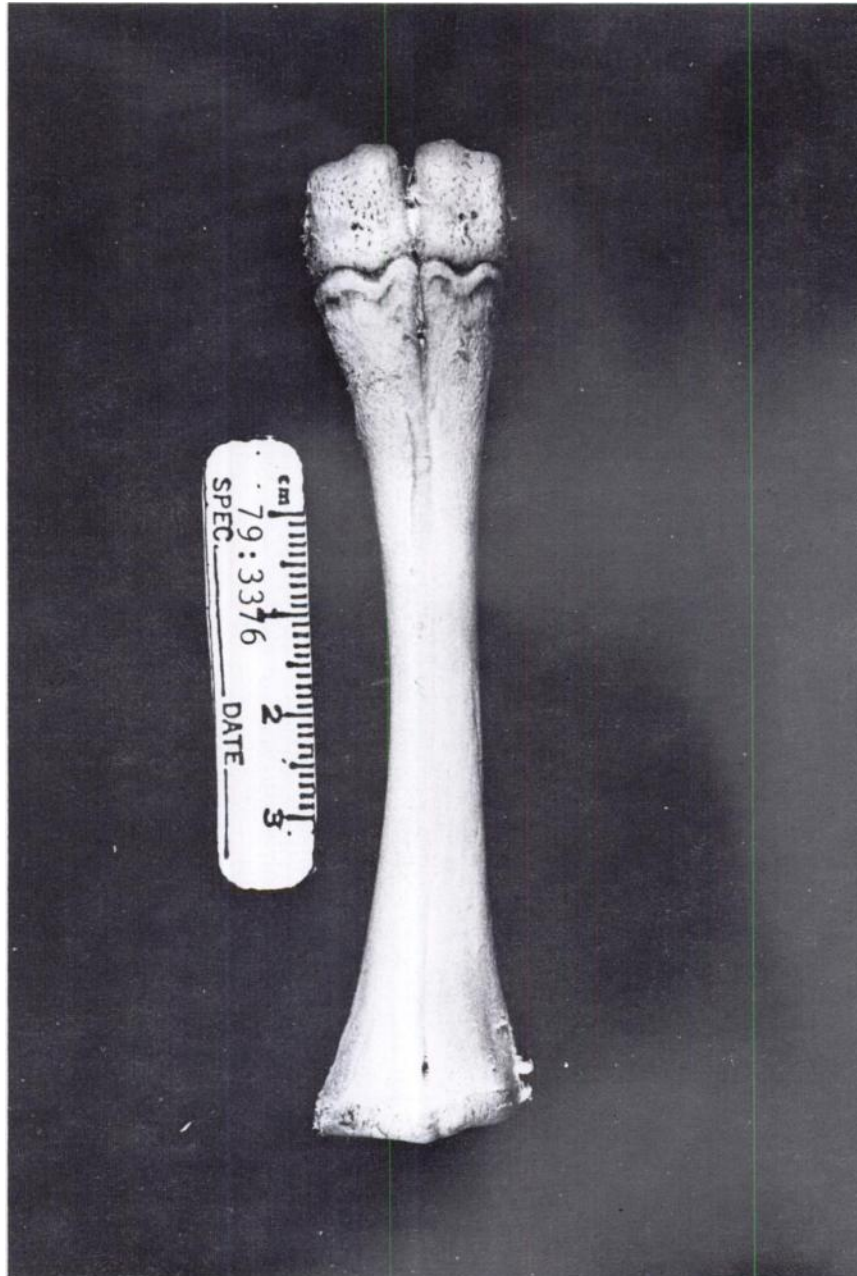
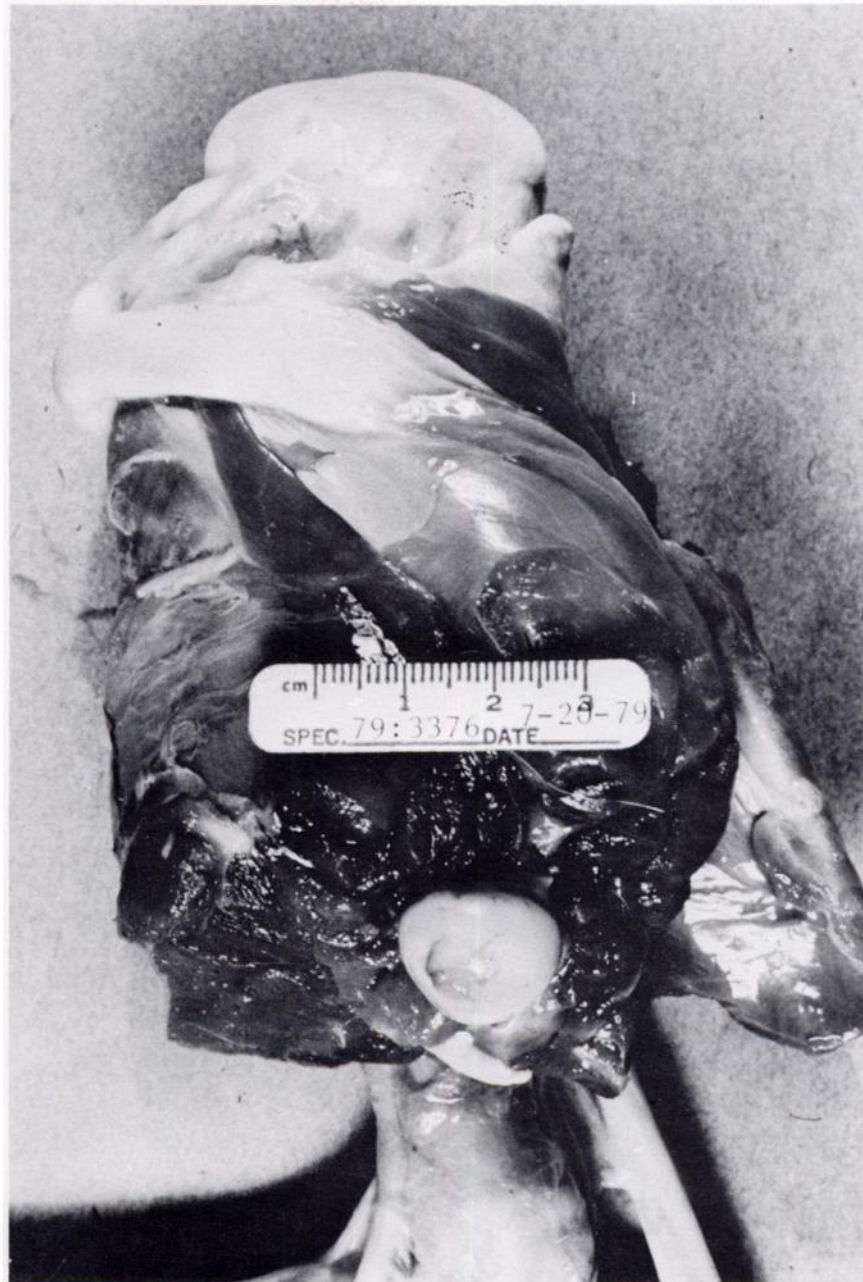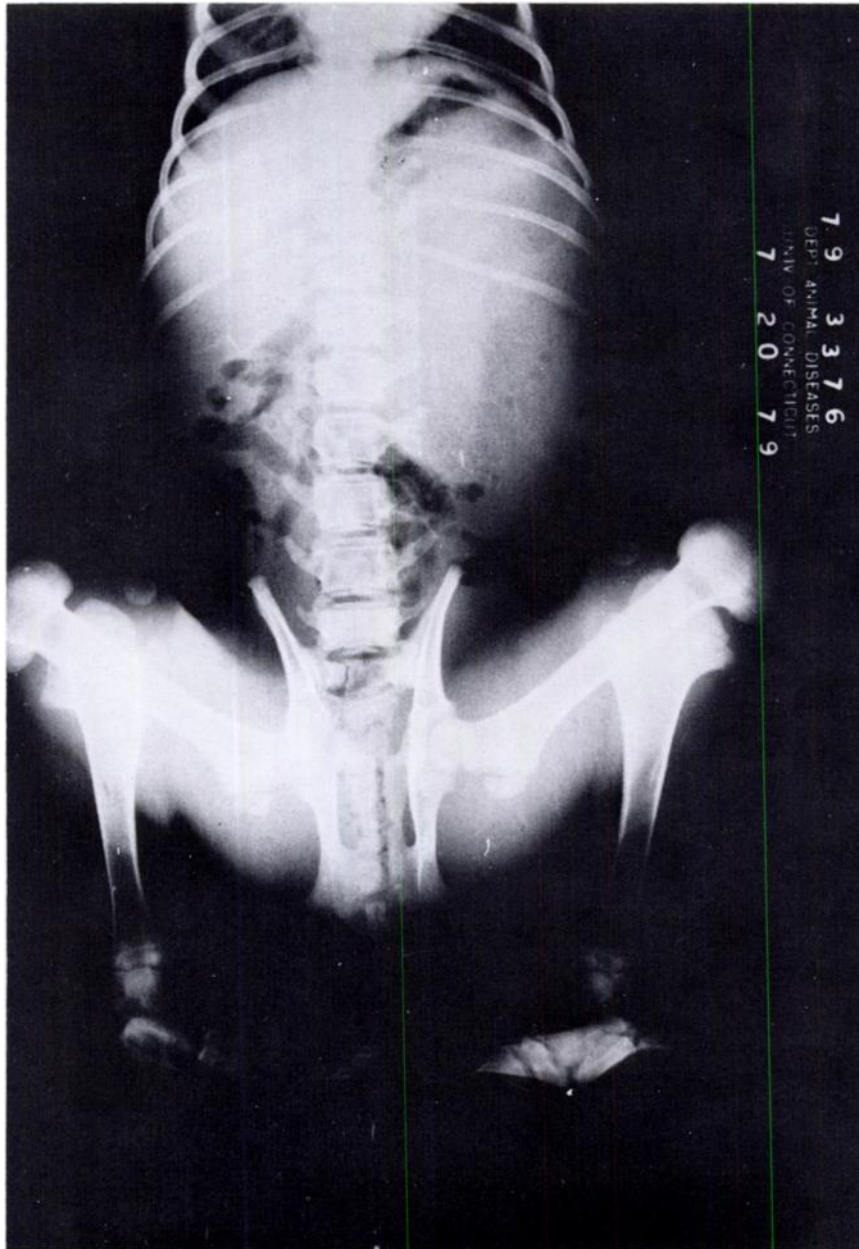


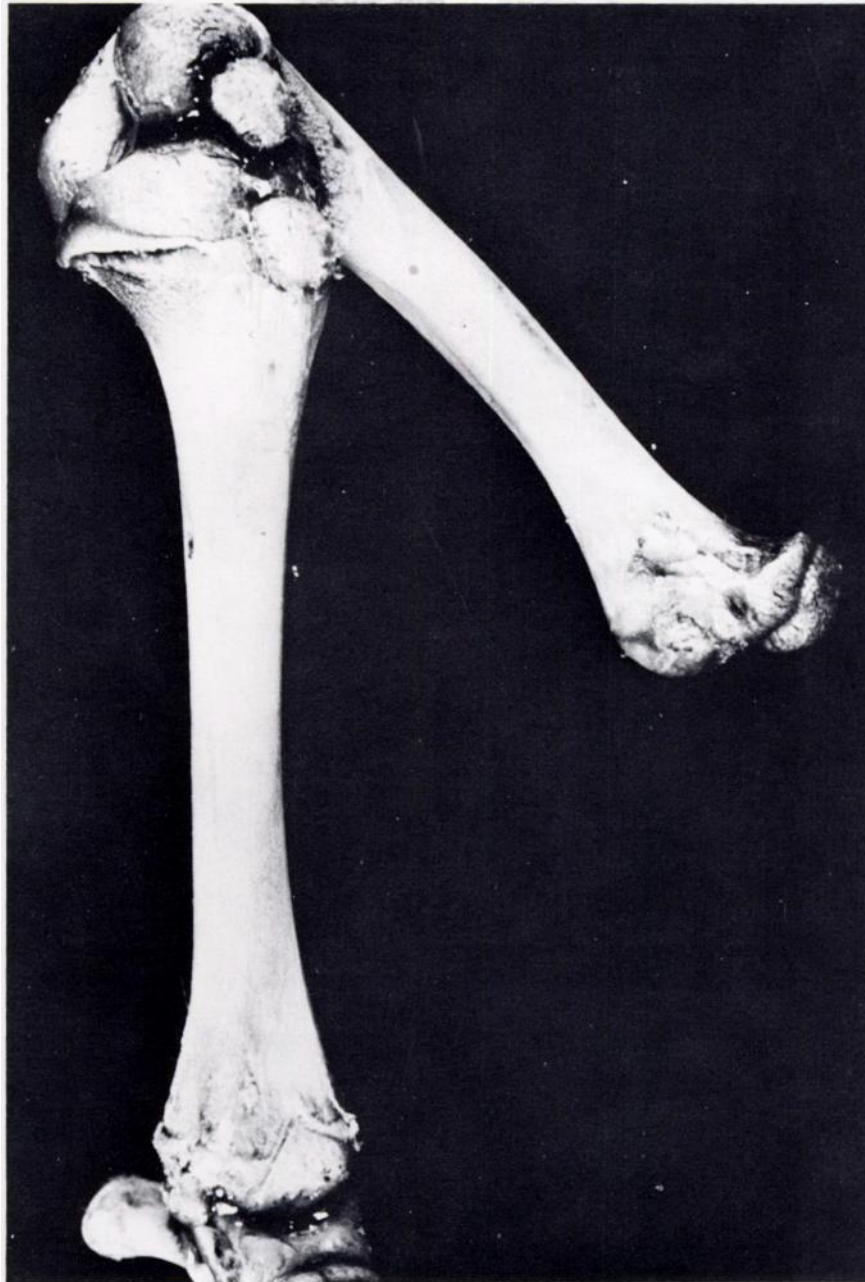
FIGURE 3. The palmar view of the right metacarpal bone failed to demonstrate the marked deviation of the medial metacarpal bone which was evident radiographically.



**FIGURE 4.** Dissection of the right stifle demonstrated the medial position of the patellar ligament.



**FIGURE 5.** The ventrodorsal radiograph of the unreduced rear legs demonstrated bilateral medial patellar luxation, remodeling of the stifle, medial rotation of the tibiae, and a normal pelvis.



**FIGURE 6.** The bones of the right rear limb were reconstructed for comparison to the radiograph.



rotation of the hocks which was evident in the living animal. There were no anomalies in the pelvis.

### DISCUSSION

Congenital bilateral medial patellar luxation or metacarpal deviation has not been reported in deer. The patellar luxation is common in pedigreed miniature dogs, such as the poodle, Pekingese, Chihuahua, and pug, but its cause and clinical sequence have not been defined. The condition in dogs has been classified into four grades.<sup>2</sup> Based on this system, this fawn had a grade IV/IV patellar luxation. Bilateral medial rotation of the distal portion of the hind limbs and left forelimb has been reported in a white-

tailed fetus, with shortening of long bones and mild lumbar lordosis.<sup>10</sup>

Medial metacarpal deviation associated with contracture of the carpus may have been congenital in origin or due to secondary remodeling. The metatarsal rotation was probably remodeling associated with the stresses of the proximal malalignments.

Several cases of partial or complete albinism have been reported in deer.<sup>3,4,7</sup> Some half white or spotted deer have been known to revert to normal body color with age, suggesting that this coloration may not be a permanent anomaly.<sup>7</sup> A similar color variation in the doe suggests color pattern might have been inherited but is not evidence that the bone lesions were inherited.

### Acknowledgements

The authors thank R.E. Horton of the Vermont Fish and Game Department for submitting this animal and Ms. Joyce Czikowsky for photography.

### LITERATURE CITED

1. BARRETT, M.W. and G.A. CHALMERS. 1975. Congenital anomalies in a neonatal white-tailed deer in Alberta. *J. Wildl. Dis.* 11: 497-501.
2. HARRISON, J.W. 1975. Patellar dislocation. In: *Current Techniques for Small Animal Surgery*. M.J. Bojrab, ed., Lea and Febiger, Philadelphia, Pennsylvania.
3. HEWSTON, J. 1962. Albino animals in North Dakota. *J. Mammal.* 43: 269-270.
4. HUGHES, D.D. 1869. Albino deer and chipmunks. *Am. Nat.* 2: 664-665.
5. JOHNSON, C.E. 1935. Abnormal mandible in white-tailed deer. *J. Mammal.* 16: 69-70.
6. MILLER, F.L. and A.J. CAWLEY. 1970. Polydactylism in white-tailed deer from eastern Ontario. *J. Wildl. Dis.* 6: 101-103.
7. RYEL, L.A. 1963. The occurrence of certain anomalies in Michigan white-tailed deer. *J. Mammal.* 44: 79-98.
8. STONE, W.B., S.L. FREE, W.T. HESSELTON and L.W. JACKSON. 1970. Polydactylism in a white-tailed deer from New York. *N.Y. Fish and Game J.* 17: 131-132.
9. VERME, L.J. 1968. Possible hereditary defects in Michigan white-tailed deer. *J. Mammal.* 49: 148.
10. WOBESER, G. and W. RUNGE. 1973. Multiple anomalies in a white-tailed deer fetus. *J. Wildl. Dis.* 9: 356-358.

*Received for publication 30 June 1980*