

## **Dental Abnormalities in Free-Ranging Cape Mountain Zebras (*Equus zebra zebra*)**

Author: Penzhorn, B. L.

Source: Journal of Wildlife Diseases, 20(2) : 161-166

Published By: Wildlife Disease Association

URL: <https://doi.org/10.7589/0090-3558-20.2.161>

---

BioOne Complete ([complete.BioOne.org](https://complete.BioOne.org)) is a full-text database of 200 subscribed and open-access titles in the biological, ecological, and environmental sciences published by nonprofit societies, associations, museums, institutions, and presses.

Your use of this PDF, the BioOne Complete website, and all posted and associated content indicates your acceptance of BioOne's Terms of Use, available at [www.bioone.org/terms-of-use](https://www.bioone.org/terms-of-use).

Usage of BioOne Complete content is strictly limited to personal, educational, and non - commercial use. Commercial inquiries or rights and permissions requests should be directed to the individual publisher as copyright holder.

---

BioOne sees sustainable scholarly publishing as an inherently collaborative enterprise connecting authors, nonprofit publishers, academic institutions, research libraries, and research funders in the common goal of maximizing access to critical research.

Chicago, Illinois 60600, USA; the National Museum of Natural History, Washington, D.C. 20560, USA, and the Museum of Natural History, University of Alaska, Fairbanks 99701, USA. Of these, two rams that died at the Brookfield Zoo, Chicago, Illinois 60600, USA and whose skeletons were placed in the Field Museum of Natural History were observed to have prominent and well developed upper canines (Figs. 1 and 2). The protruding canines had disrupted the alignment of the upper premolars. This malalignment appeared to be associated with displaced and missing teeth of the maxillary and mandible (Figs. 3 and 4).

The canines were rounded instead of laterally compressed as is characteristic of the premolars and molars in *Ovis*. The ends of the canines were worn evenly with the premolars, a situation that appeared to have resulted from abrasion at the point of occlusion with the lower premolars.

Glaze et al. (1982, J. Wildl. Dis. 18: 305–309) postulated that “lumpy jaw” in Dall’s sheep is commonly associated with abnormal wearing of teeth and a disrupted alignment of the tooth arcade. Both rams in the present case report had well developed “lumpy jaw,” missing and displaced

teeth, osteolysis with loss of trabecular and cortical bone, and fistulation of the mandible (Fig. 5). The persistence of upper canines, as observed in these skulls, would likely lead to “lumpy jaw” in wild populations of Dall’s sheep. The prevalence of such occurrences, however, appears to be very low based on our review of museum specimens. This conclusion is further supported by Hoef’s (1974, Can. Field Nat. 88: 227–229) report that only one of 400 Dall’s sheep skulls examined from populations of sheep from Yukon Territory, Canada had supernumerary molari-form teeth. The higher occurrence (2 of 6 skulls) in specimens from the Brookfield Zoo sheep was most likely a factor of inbreeding. Twenty-four of the 211 skulls (11%) examined in this survey had “lumpy jaw,” however only two of the affected specimens had supernumerary teeth. “Lumpy jaw,” therefore, would not usually be associated with upper canines.

Supported by the Foundation for North American Wild Sheep and published as a Utah State University Agricultural Experiment Station Journal Paper No. 2887. We gratefully appreciated the assistance of the staff members at the museums cited.

*Journal of Wildlife Diseases*, 20(2), 1984, pp. 161–166  
© Wildlife Disease Association 1984

## Dental Abnormalities in Free-Ranging Cape Mountain Zebras (*Equus zebra zebra*)

**B. L. Penzhorn**, Department of Genesiology, Faculty of Veterinary Science, University of Pretoria, P.O. Box 12580, Onderstepoort 0110, Republic of South Africa

Dental abnormalities in animals are often artifacts of their domestication or captivity, e.g., crib biting in horses resulting in uneven wearing of the incisors (Jubb

and Kennedy, 1970, Pathology of Domestic Animals, Vol. 2, Academic Press, New York, 697 pp.). Little has been documented on dental abnormalities in free-ranging wild animals, especially of the African species, although some descriptions were included in a general survey based on mu-

---

Received for publication 26 August 1983.

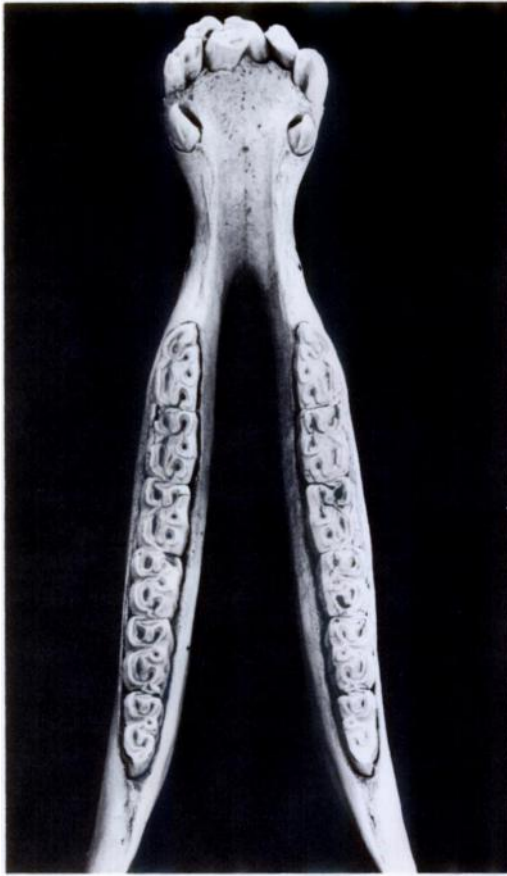


FIGURE 1. Mandible of an adult Cape mountain zebra stallion with malpositioning of I1 and I2 in the left ramus, resulting in medial angling of the right I1 and I2.

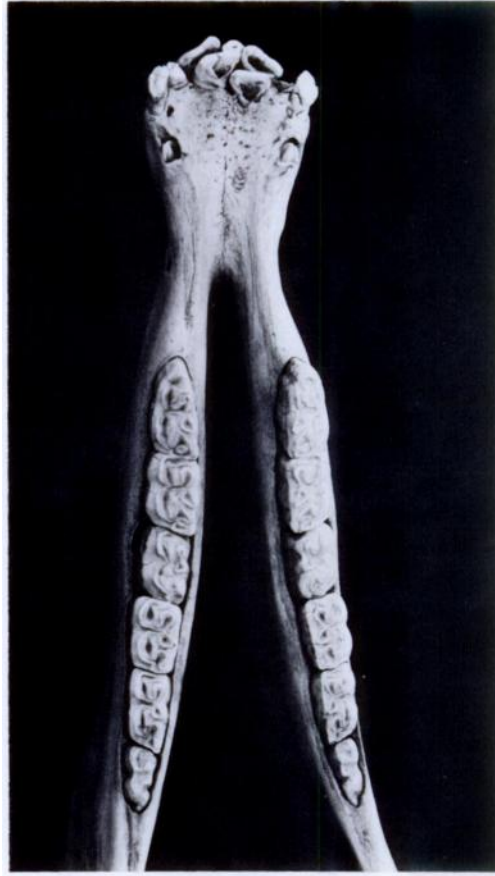


FIGURE 3. Mandible of a 2½-yr-old Cape mountain zebra stallion with malpositioning of the permanent incisors and retention of deciduous incisors resulting in apparent supernumerary teeth.

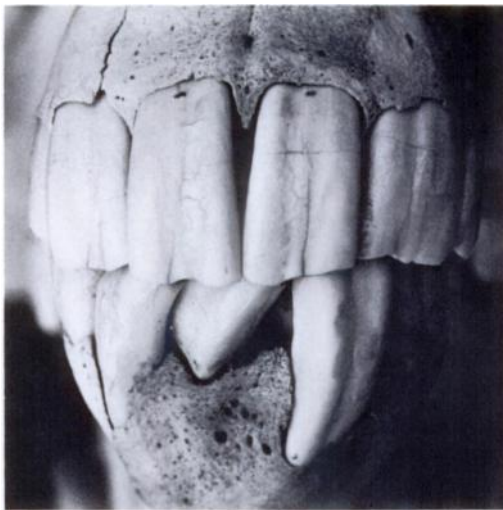

FIGURE 2. A rostral view of the skull and mandible of the stallion described in Figure 1.

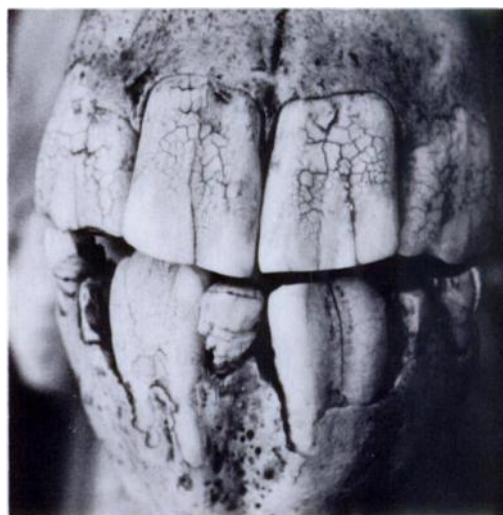


FIGURE 4. A rostral view of the skull and mandible of the stallion described in Figure 3.

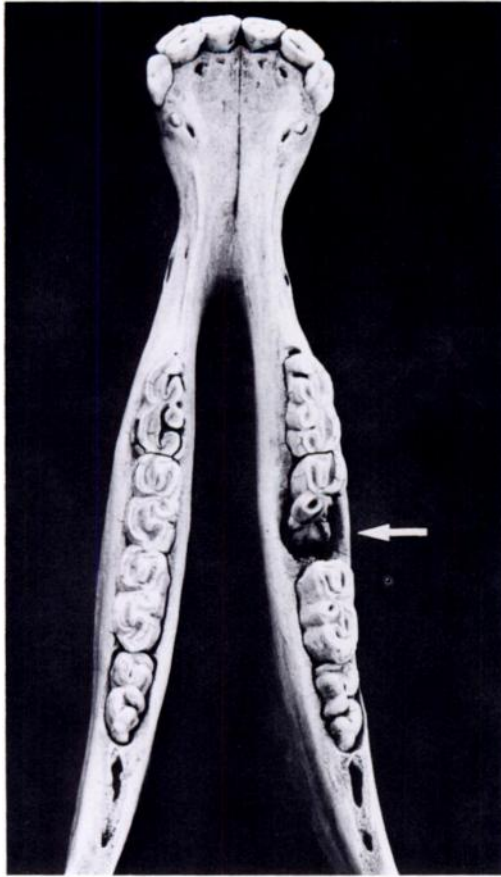


FIGURE 5. Mandible of a 1-yr-old Cape mountain zebra colt. A longitudinal fracture of right p3 has resulted in loss of the caudo-labial portion of this tooth (arrow) and probably led to periodontitis in this area.

seum specimens (Colyer, 1936, *Variations and Diseases of the Teeth of Animals*, John Bale, Sons and Danielsson, London, 750 pp.). Abnormal tooth formulae have been reported in impala (*Aepyceros melampus*), grey duiker (*Sylvicapra grimmia*), Sharpe's grysbok (*Raphicerus sharpei*) and warthog (*Phacochoerus aethiopicus*) (Child, 1965, *Mammalia* 29: 622–623; Child, 1969, *Mammalia* 33: 541–542; Child and Riney, 1964, *Occas. Pap. Mus. S. Rhod.* 27B: 1–4; Child et al., 1965, *Arnoldia (Rhod.)* 1(38): 1–23). Dental abnormalities resulting from mandibular fractures have been described in a leopard

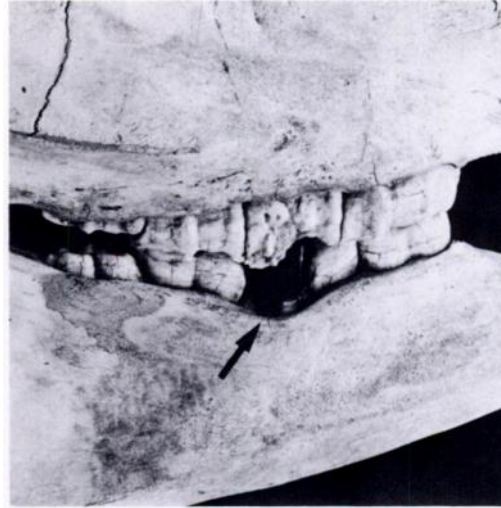


FIGURE 6. A right lateral view of the skull and mandible of the colt described in Figure 5. Note the vertical alveolar bone resorption at the level of mandibular p3 (arrow) and maxillary p3 projecting beyond the level of the other teeth in the molar arcade.

(*Panthera pardus*) (Hemmer, 1964, *Säugetierk. Mitt.* 12: 52–55) and in a white rhinoceros (*Ceratotherium simum*) (Hickman, 1979, *Lammergeyer* 29: 46–47).

During a 4½-yr study (1971–1976) of the ecology and behavior of Cape mountain zebras in the Mountain Zebra National Park (MZNP), Republic of South Africa, all skulls found in the veld were collected for age determination (Penzhorn, 1982, *Koedoe* 25: 89–102). A few of the skulls exhibited dental abnormalities and these are described here. The zebra population of the MZNP is about 200.

The dental formulae of Cape mountain zebras are identical to those of the other recent equids (Simpson, 1951, *Horses*, Oxford University Press, New York, 247 pp.; Volf, 1972, *In Grzimeks Tierleben*, Grzimek (ed.), Kindler Verlag, Zürich, Switzerland 12: 541–582):

Deciduous dentition:

$$2\left(\frac{3}{1} \frac{1}{3} \frac{4}{1} \frac{4}{4}\right) = 32$$



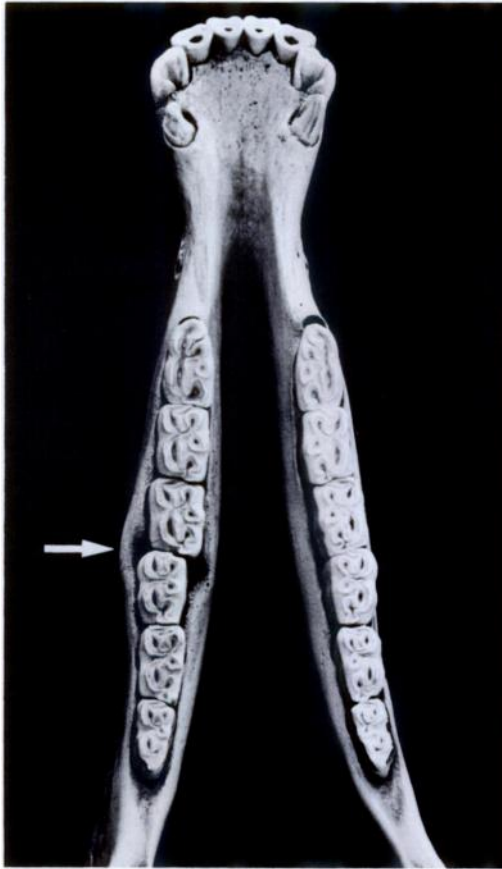

FIGURE 7. Mandible of an adult Cape mountain zebra stallion. When found, there was fibrous vegetable matter wedged between P4 and M1 in the left ramus of the mandible. Note the malalignment of the left molar arcade, as well as the diastema between P4 and M1 and evidence of periodontitis in this area (arrow).

Permanent dentition:

$$2\left(I\frac{3}{3}C\frac{1}{1}P\frac{3}{3}M\frac{3}{3}\right) = 40$$

Well-developed canines are present in stallions only and can be used to determine the sex of skulls. Canines in mares are small or absent. Deciduous canines are present in both colts and fillies. The deciduous incisors have a definite neck and can readily be distinguished from the permanent incisors, which have straight sides.

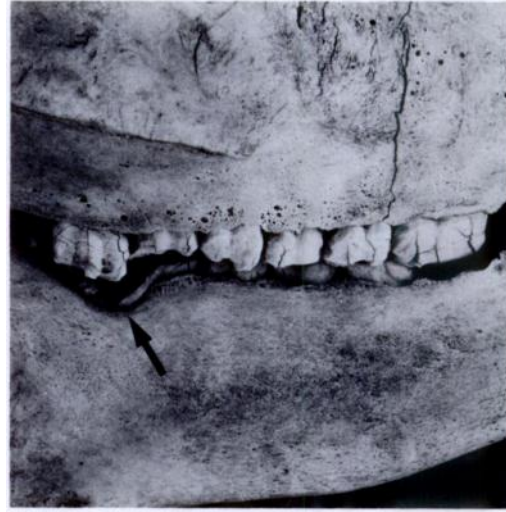

FIGURE 8. Lateral view of the skull and mandible of an old Cape mountain zebra stallion. Note the uneven wearing of the premolars and molars and vertical bone resorption in the area of M2 (arrow).

The deciduous upper first premolars or 'wolf teeth' are rudimentary and are not replaced.

Seven of the 37 skulls found during the study showed dental abnormalities. Two

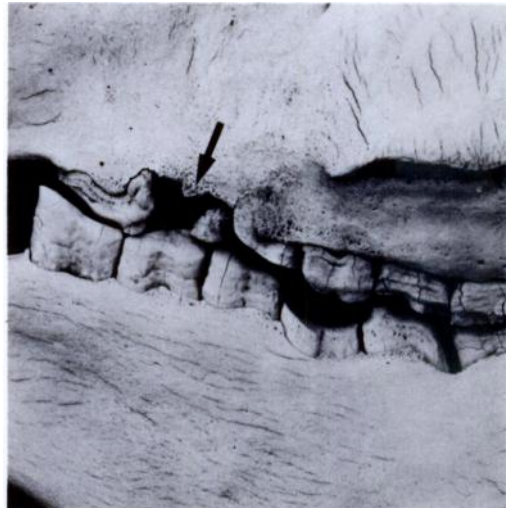


FIGURE 9. Lateral view of the skull and mandible of an old Cape mountain zebra mare. Note the uneven wearing of the premolars and molars and the absence of maxillary P3 (arrow).

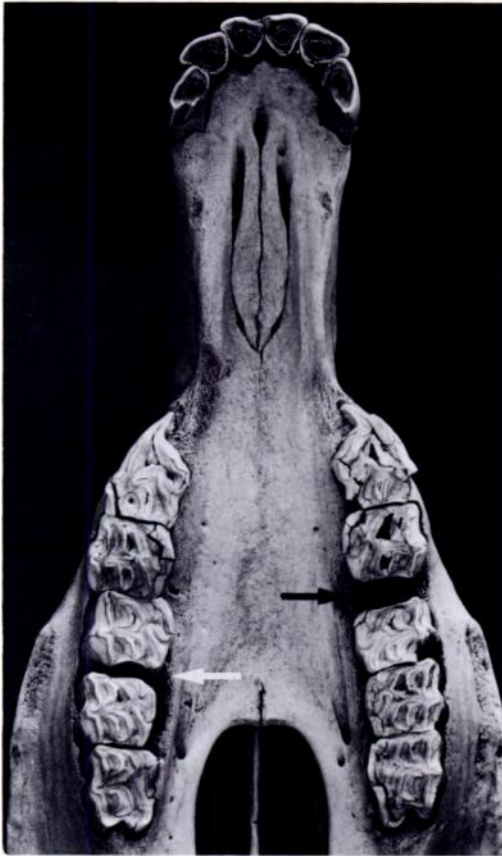


FIGURE 10. The palate and maxilla of an adult Cape mountain zebra mare, with loss of right M1 (white arrow) and left P4 (black arrow). In the right molar arcade there is a diastema of 3–4 mm between P4 and M2.

of these, both from stallions, exhibited malpositioning of the permanent incisors (Figs. 1, 2, 3 and 4). Equids depend on strong, opposing incisors for normal gathering of forage into the mouth. Malpositioning of the incisors may be detrimental to the individual by reducing its grazing efficiency. One of the skulls (Figs. 1 and 2) came from a stallion which had survived well into adulthood, implying that the condition was of minor importance in this case. In the other case (Figs. 3 and 4), some deciduous incisors persisted resulting in apparent supernumerary teeth (pseudopolyodontia).

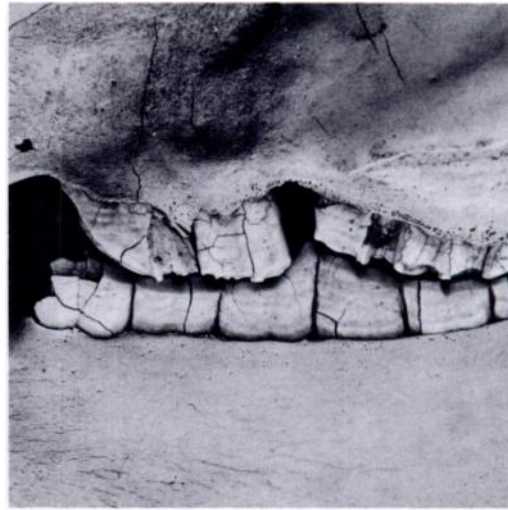


FIGURE 11. A left lateral view of the skull and mandible of the mare described in Figure 10. Note the hook formation of mandibular P2 and mandibular P4 and M1 projecting beyond the level of the other teeth in the molar arcade.

Lesions of bone and teeth consistent with periodontitis were evident in two skulls. A longitudinal fracture of right mandibular p3 probably instigated the inflammatory process in a 1-yr-old colt (Figs. 5 and 6). In the antagonistic molar arcade, p3 and p4 project beyond the level of the other premolars (*exsuperantia dentium*). In the other case, an adult stallion, fibrous vegetable matter was found wedged between two of the cheek teeth in the mandible. This evidently caused the periodontitis in this area (Fig. 7). Periodontitis tends to be chronic and the alveolar bone usually does not undergo necrosis, but a rarefying osteitis with osteoclastic bone resorption develops so that the bony alveolus is increased in size (Jubb and Kennedy, 1970, *op. cit.*). This is demonstrated clearly in Figure 7.

Uneven wearing of the cheek teeth (weavemouth) was seen in the skulls of an old stallion (Fig. 8) and an old mare (Fig. 9). The stallion's skull also showed vertical bone resorption in the right ramus of the mandible at the level of M2 and M3. In

the case of the mare, the left maxillar P3 is lacking, but may have been lost post mortem. Weavemouth is a common condition in older domestic animals (Jubb and Kennedy, 1970, op. cit.) in which successive teeth in the molar arcade wear at different rates. In the antagonistic arcade the weave is reversed so that opposite occlusive surfaces remain appositive and occlusion can still be complete. The effect on mastication is therefore probably minimal and weavemouth may be considered of minor importance. The skull of an old mare (Fig. 9) also showed hook formation of the left mandibular P2. This condition results from incomplete longitudinal coincidence of the molar arcades which allows irregular wear.

In the skull of an adult mare which had lost two of her maxillar cheek teeth (left P4 and right M1), P4 and M1 of the left

mandibular molar arcade project beyond the level of the other teeth, while both mandibular P2's show hook formation (Figs. 10 and 11).

In most of these skulls the dental abnormalities were probably merely incidental post mortem findings. Even in the cases showing lesions consistent with periodontitis the inflammation was chronic rather than acute. The influence which the dental abnormalities described here may have had on the mortality of Cape mountain zebras in the MZNP remains speculative, but would seem to be unimportant.

The study was undertaken while the author was employed by the National Parks Board of Trustees. I thank Drs. R. M. McCully, F. J. M. Verstraete and J. B. Walker for commenting on the manuscript. Mr. D. A. Wolhuter kindly supplied one of the references.

*Journal of Wildlife Diseases*, 20(2), 1984, pp. 166-168  
© Wildlife Disease Association 1984

## Recuperation of a Severely Debilitated Wolf

**L. D. Mech**,<sup>1</sup> U.S. Fish and Wildlife Service, Patuxent Wildlife Research Center, Laurel, Maryland 20708, USA; **U. S. Seal**, V.A. Medical Center, Research Service, 54th St. & 48th Ave. So., Minneapolis, Minnesota 55417, USA and Departments of Biochemistry and Entomology, Fisheries and Wildlife, Univ. of Minnesota, St. Paul, Minnesota 55108, USA; and **S. M. Arthur**,<sup>2</sup> U.S. Fish and Wildlife Service, Patuxent Wildlife Research Center, Laurel, Maryland 20708, USA

Opportunities are rare for determining the degree to which an animal can starve and still survive. Therefore we describe here an incident in which a wild wolf (*Canis lupus*) starved almost to death and was then restored to her former free-ranging state. The incident took place in northern Lake County, Minnesota.

Female wolf 6301 was captured, radio-

collared, and blood sampled as a pup on 3 September 1981; she weighed 13.5 kg. Between 28 and 30 December 1982, this wolf got caught in a steel foot trap set by fur trappers who failed to check their traps every 36 hr as required. We found her in the trap on 4 January, after a minimum of 5 days there. The wolf was lying on her side, with her head up. She then dropped her head, offered no resistance, and failed to respond while the trap was removed. She was emaciated and weighed 18.6 kg which is the lightest of 77 wild yearling or adult females from Minnesota for which we have records. The lightest of 22 well-fed, captive yearling and adult female

Received for publication 1 July 1983.

<sup>1</sup> Mailing address: U.S. Fish and Wildlife Service, North Central Forest Experiment Station, 1992 Folwell Ave., St. Paul, Minnesota 55108, USA.

<sup>2</sup> Present address: Maine Cooperative Wildlife Research Unit, University of Maine, Orono, Maine 04469, USA.