



## **MUELLERIUS CAPILLARIS (MUELLER, 1889) (NEMATODA: PROTOSTRONGYLIDAE): AN UNUSUAL FINDING IN ROCKY MOUNTAIN BIGHORN SHEEP (OVIS CANADENSIS CANADENSIS SHAW) IN SOUTH DAKOTA**

Authors: Pybus, M. J., and Shave, H.

Source: Journal of Wildlife Diseases, 20(4) : 284-288

Published By: Wildlife Disease Association

URL: <https://doi.org/10.7589/0090-3558-20.4.284>

---

BioOne Complete ([complete.BioOne.org](http://complete.BioOne.org)) is a full-text database of 200 subscribed and open-access titles in the biological, ecological, and environmental sciences published by nonprofit societies, associations, museums, institutions, and presses.

Your use of this PDF, the BioOne Complete website, and all posted and associated content indicates your acceptance of BioOne's Terms of Use, available at [www.bioone.org/terms-of-use](http://www.bioone.org/terms-of-use).

Usage of BioOne Complete content is strictly limited to personal, educational, and non - commercial use. Commercial inquiries or rights and permissions requests should be directed to the individual publisher as copyright holder.

---

BioOne sees sustainable scholarly publishing as an inherently collaborative enterprise connecting authors, nonprofit publishers, academic institutions, research libraries, and research funders in the common goal of maximizing access to critical research.

## **MUELLERIUS CAPILLARIS (MUELLER, 1889) (NEMATODA: PROTOSTRONGYLIDAE): AN UNUSUAL FINDING IN ROCKY MOUNTAIN BIGHORN SHEEP (*OVIS CANADENSIS CANADENSIS* SHAW) IN SOUTH DAKOTA**

M. J. Pybus<sup>1</sup> and H. Shave<sup>2</sup>

**ABSTRACT:** Lungs and fecal samples from nine hunter-killed Rocky Mountain bighorn sheep were examined for lungworms. All samples contained adults and/or larvae of *Muellerius capillaris* (Mueller, 1889). *Protostrongylus* spp., the lungworms commonly reported from bighorn sheep, were not present in any samples. Larvae of *M. capillaris* bear a spine on the dorsal side of the posterior end and are shorter than dorsal-spined larvae of other lungworms recorded from North American ungulates. Larvae similar in shape but longer than those of *Muellerius* were found in free-ranging bighorn sheep in Alberta and British Columbia. In addition, dorsal-spined larvae have been found in bighorn sheep in Montana, North Dakota, and Washington. The identity of the dorsal-spined larvae is known only from sheep in South Dakota. Thus, caution must be taken when diagnosing lungworm infections in Rocky Mountain bighorn sheep.

### **INTRODUCTION**

Three species of metastrongyloid lungworms (Nematoda: Protostrongylidae) have been reported from Rocky Mountain bighorn sheep. All are members of the genus *Protostrongylus*: *Protostrongylus frosti* Honess, 1942, *Protostrongylus rushi* Dikmans, 1937, and *Protostrongylus stilesi* Dikmans, 1931. *Protostrongylus frosti* was described from bighorn sheep in Wyoming (Honess, 1942) but additional specimens have not been collected and its taxonomic position is uncertain (see Dougherty and Goble, 1946; Dikmans, 1957). *Protostrongylus rushi* and *P. stilesi* have been reported frequently and are distributed widely throughout populations of Rocky Mountain bighorn sheep at prevalences ranging from 90 to 100%.

An evaluation of lungworm infections in Rocky Mountain bighorn sheep in Custer State Park, southwestern South Dakota was undertaken. The lungs of all sheep

examined contained *Muellerius capillaris* (Mueller, 1889) in the parenchyma; none was infected with *Protostrongylus* spp.

### **MATERIALS AND METHODS**

During December 1980 and 1981, lungs and fecal samples were collected from nine hunter-killed bighorn sheep from Custer State Park, South Dakota (lat. 44°N, long. 103°W). The sheep were 5½ to 9 yr old. In 1981, the ventral edge of the left diaphragmatic lobe was removed and fixed in formalin for histologic study. In 1981, samples taken from lesions in each of six lungs were incubated on sterile agar with 5% bovine serum in an atmosphere of 10% carbon dioxide at 37 C for 48 hr and then scanned for identification of bacterial colonies. The remaining material was frozen and sent to the University of Alberta where it was thawed and the gross lesions examined and removed. Some lesions were teased apart and adult worms removed. The remaining areas of tissue damage were placed overnight in a pepsin/HCl digest at 37 C. All bronchi and bronchioles in the rest of the lung were opened and examined for helminths. Fecal samples were weighed and placed in a Baermann apparatus overnight. One hundred ml from each funnel were centrifuged for 10 min. The supernatant was removed and the remaining 10 ml were examined at 25× magnification. Results were expressed as the number of larvae per gram of feces. Approximately 10 larvae collected from each sample were heat-killed in water and then measured at 200× magnification. Larvae collected from the feces of free-ranging Rocky Mountain bighorn sheep in Banff, Alberta (lat. 51°N, long. 116°W)

---

Received for publication 5 March 1984.

<sup>1</sup> Department of Zoology, University of Alberta, Edmonton, Alberta T6G 2E9, Canada. Present address: Alberta Fish and Wildlife Division, O. S. Longman Building, 6909-116 St., Edmonton, Alberta T6H 4P2, Canada.

<sup>2</sup> South Dakota State University, Box 2175, Brookings, South Dakota 57007, USA.

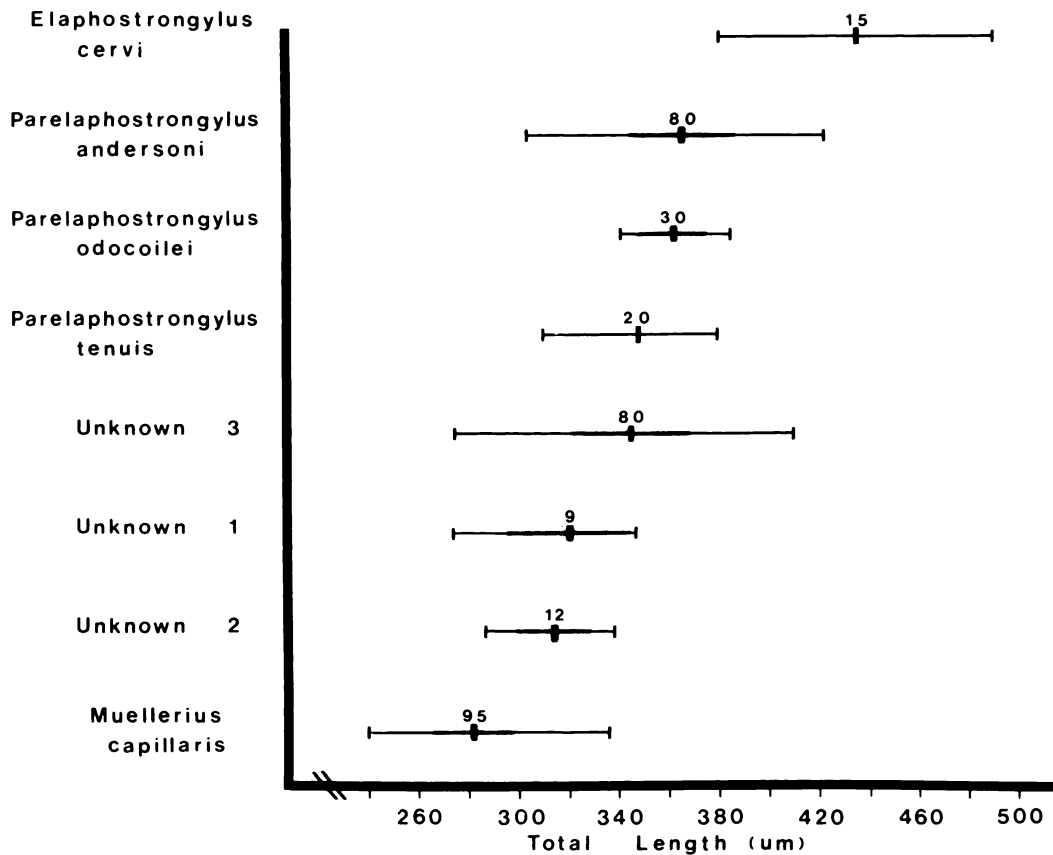


FIGURE 1. Total length of first-stage larvae (=dorsal-spined larvae) of various metastrongyloid nematodes. (Horizontal bar = range; shaded area = 1 SD; thick vertical bar = mean; number above mean = no. larvae measured.) [Data for *Elaphostrongylus cervi* from Lankester and Northcott (1979); *Parelaphostrongylus andersoni* and *P. odocoilei* from Pybus (unpubl. data); *P. tenuis* from Anderson (1963); Unknowns 1-3 are samples from bighorn sheep in Alberta (#1) and British Columbia (#2 and 3) (see text); *Muellerius capillaris* (this paper).]

and Premier Ridge, British Columbia (lat. 49°N, long. 115°W) were also heat-killed and measured.

**RESULTS**

All fecal samples from sheep in South Dakota contained nematode larvae bearing a small spine on the dorsal side of the posterior end. Intensities ranged from 1.4 to 2,604 larvae/gram (mean 507 ± 857). The total length of these larvae was significantly less than the dorsal-spined larvae in the samples from sheep in Alberta and British Columbia ( $F = 156, df = 3,196,$

$P < 0.001$ ) (Fig. 1). No other nematode larvae were found.

Gross examination of the lung samples revealed firm, raised, pale yellow to translucent grey circumscribed or elongate nodules in the parenchyma of all samples examined. Lesions were restricted largely to the subpleural surfaces of the dorsal and dorso-lateral aspects of the diaphragmatic lobes. One sample contained nodules along the ventral edge of the cardiac lobe and another had extensive diffuse pale areas throughout the distal diaphragmatic lobes.

Adult nematodes were collected from

each set of lungs examined. Based on descriptions by Cameron (1927) and Gerichter (1951), the specimens were identified as *Muellerius capillaris*. Specimens were deposited in the National Museum of Canada Invertebrate Collection (NMCICP1984-0323) and the United States National Parasite Collection (78054). Males and females were usually present in each nodule and individual nodules often contained 10 to 20 adults. Eggs and larvae were also present in most nodules. All larvae seen in the lungs had a dorsal spine on the posterior end.

Lesions in histologic sections were indicative of a granulomatous pneumonia associated with adult worms, larvae, and eggs. The major lesions were chronic bronchitis, bronchiolitis, bronchiectasis, smooth muscle hyperplasia, and a marked perivascular and peribronchiolar lymphoid cell accumulation. No pathogenic bacteria were isolated from the lungs of the six animals examined.

#### DISCUSSION

*Muellerius capillaris* is a common and ubiquitous lungworm in domestic animals, particularly sheep and goats (Soulsby, 1968; Jubb and Kennedy, 1970). It has not been identified previously in wild animals in North America. The size of adult *Muellerius capillaris* and *Protostrongylus stilesi* is similar but the tightly-coiled tail of the adult male distinguishes *M. capillaris* from all other lungworms.

Demartini and Davies (1977) reported adult *Muellerius* sp. in Rocky Mountain bighorn sheep collected in Custer State Park but did not mention the tail of the adult male nematodes. Other reports of *Muellerius* sp. in bighorn sheep (see Hudson et al., 1971, 1972; Bandy, 1972; Foreyt and Johnson, 1980), Dall's sheep (*Ovis dalli* Nelson) (Goble and Murie, 1942; Neiland, 1972; Dau, 1981), reindeer (*Rangifer tarandus* (Linnaeus)) and muskox (*Ovibos moschatus* (Zimmermann)) (Dau, 1981) were based on the

presence of dorsal-spined larvae in fecal samples. Although a dorsal spine in the first-stage larva readily distinguishes *Muellerius* from *Protostrongylus*, the feature is not unique to the genus.

There are a variety of protostrongylid nematodes known to have first-stage larvae bearing a dorsal spine. The species present in free-ranging ungulates in North America include *Parelaphostrongylus andersoni* Prestwood, 1972, *Parelaphostrongylus tenuis* (Dougherty, 1945), and *Varestrongylus* (= *Leptostrongylus*) *alpenae* (Dikmans, 1935) in white-tailed deer (*Odocoileus virginianus* (Zimmermann)) (see Prestwood, 1972; Anderson, 1963; Prestwood and Pursglove, 1974; respectively); *Parelaphostrongylus odocoilei* (Hobmaier and Hobmaier, 1934) in black-tailed deer (*O. hemionus columbianus* (Richardson)), mule deer (*O. hemionus hemionus* (Rafinesque)) (see Brunetti, 1969), and mountain goat (*Oreamnos americana* (de Blainville)) (see Pybus et al., 1984); and *Elaphostrongylus cervi* Cameron, 1931 in caribou (*Rangifer tarandus* (Linnaeus)) (see Lankester and Northcott, 1979). Larvae of *Muellerius capillaris* were shorter than those of the other species ( $F = 180$ ,  $df = 5,300$ ,  $P < 0.001$ ) (Fig. 1). However, larval measurements provide only a clue to the identity of the infection; specific diagnosis must be based on the examination of adult nematodes.

Demartini and Davies (1977) suggested that larvae of *Muellerius* sp. could be differentiated from those of *Parelaphostrongylus* sp. by width, shape of the tail, and length of the dorsal spine. In our experience, the shape of the tail and the spine are variable in *Parelaphostrongylus andersoni* and *P. odocoilei* and should not be used as a distinguishing feature. Lankester et al. (1976) suggested similar variation may occur in larvae of a worm later identified as *Elaphostrongylus cervi* (see Lankester and Northcott, 1979).

*Muellerius* infection is relatively non-

pathogenic and rarely causes clinical disease in domestic sheep and goats, although it has been implicated in a few cases as a factor predisposing the lungs to secondary bacterial and viral agents (Jubb and Kennedy, 1970). The gross features of the lesions seen in bighorn sheep were similar to those described from domestic sheep (Beresford-Jones, 1971). However, nodules in the lungs of domestic sheep reportedly contain only one, or perhaps two, adult worms while those seen in the bighorn sheep contained numerous worms. Thus, there is a potential for more extensive granulomas and associated tissue damage in bighorn sheep than in domestic sheep. In addition, Demartini and Davies (1977) reported *Muellerius* sp. as the major pathologic agent present during a die-off of captive bighorn sheep moved from Custer State Park to Colorado.

It is significant that no larvae or adult specimens of *Protostrongylus* spp. were seen in any of the current samples. These worms apparently were not present in the sheep examined by Demartini and Davies (1977) and a review of the literature indicated that there is no report of *P. stilesi* in bighorn sheep from South Dakota. This finding is contrary to the general belief that *Protostrongylus* spp. are present in most populations and, indeed, most individual Rocky Mountain bighorn sheep. The reasons for their absence in South Dakota are unknown.

In addition to the reports mentioned previously, dorsal-spined larvae have been found in fecal samples from Rocky Mountain bighorn sheep from Alberta and British Columbia (Pybus and Samuel, unpubl. data), Montana (Forrester, pers. comm.), and North Dakota (Alstad, pers. comm.). The larvae from some populations in Alberta and British Columbia do not appear to be those of *Muellerius capillaris* (see Fig. 1). Further investigation is encouraged to determine what parasite or parasites are present in these bighorn sheep populations.

The results in this study have three important implications for researchers and managers of bighorn sheep. Firstly, infection with *Muellerius capillaris* was verified and the potential damage to the lungs described. The possibility of cross transmission of *M. capillaris* between wild and domestic sheep should be investigated. Secondly, the population of Rocky Mountain bighorn sheep in Custer State Park appears to be free of infection with *Protostrongylus* spp. Lastly, unidentified nematode(s) which produce dorsal-spined larvae are present in some sheep populations and should be considered during any investigations of the lungworm parasites of bighorn sheep.

#### ACKNOWLEDGMENTS

Personnel of Custer State Park and the South Dakota Fish and Game Department assisted in collection of the samples. The parasitology group at the University of Alberta gave critical and helpful reviews of the manuscript. Financial support was provided by Pittman-Robertson (Project W-95-R) and the Canadian National Sportsmen's Fund.

#### LITERATURE CITED

- ANDERSON, R. C. 1963. The incidence, development, and experimental transmission of *Pneumoststrongylus tenuis* Dougherty (Metastrongyloidea: Protostrongylidae) of the meninges of the white-tailed deer (*Odocoileus virginianus borealis*) in Ontario. *Can. J. Zool.* 41: 775-792.
- BANDY, P. J. Personal communication cited in Neiland (1972).
- BERESFORD-JONES, W. P. 1971. Pathology and parasitology of sheep lungworm infections in lungs and mediastinal lymph nodes. In *Pathology of Parasitic Diseases*, S. M. Gaafar (ed.). Purdue Univ. Studies, Lafayette, Indiana, pp. 287-294.
- BRUNETTI, O. A. 1969. Redescription of *Parelaphostrongylus* (Boev and Schuls, 1950) in California deer, with studies on its life history and pathology. *Calif. Fish Game* 55: 307-316.
- CAMERON, T. W. M. 1927. Studies on three new genera and some little-known species of the nematode family Protostrongylidae Leiper, 1926. *J. Helminthol.* 5: 1-24.
- DAU, J. 1981. *Protostrongylus*, *Muellerius* and *Dictyocaulus*. In *Alaskan Wildlife Diseases*, R. A. Dieterich (ed.). Univ. Alaska, Fairbanks, Alaska, pp. 141-146.
- DEMARTINI, J. C., AND R. B. DAVIES. 1977. An

- epizootic of pneumonia in captive bighorn sheep infected with *Muellerius* sp. J. Wildl. Dis. 13: 117-124.
- DIKMANS, G. 1957. A note on the specific identity of *Protostrongylus frosti* Honess, 1942. Proc. Helminthol. Soc. Wash. 24: 116-120.
- DOUGHERTY, E. C., AND F. C. GOBLE. 1946. The genus *Protostrongylus* Kamenskii, 1905 (Nematoda: Metastrongylidae), and its relatives: Preliminary note. J. Parasitol. 32: 7-16.
- FOREYT, W., AND R. JOHNSON. 1980. Treatment for lungworms (*Protostrongylus* spp.) in Rocky Mountain bighorn sheep (*Ovis c. canadensis*) with albendazole. Proc. Biennial Symp. Northern Wild Sheep and Goat Council. Salmon, Idaho, pp. 248-259.
- GERICHTER, C. B. 1951. Studies on the lung nematodes of sheep and goats in the Levant. Parasitology 41: 166-183.
- GOBLE, F. C., AND A. MURIE. 1942. A record of lungworms in *Ovis dalli* (Nelson). J. Mammal. 23: 220-221.
- HONESS, R. F. 1942. Lungworms of domestic sheep and bighorn sheep in Wyoming. Univ. Wyoming Agric. Exper. Sta. Bull. 255: 1-24.
- HUDSON, R. J., P. J. BANDY, AND W. D. KITTS. 1972. Cell adherence reactions in lungworm (*Protostrongylus*) infections of the Rocky Mountain bighorn sheep. Can. J. Comp. Med. 36: 69-73.
- , W. D. KITTS, AND P. J. BANDY. 1971. Immunoglobulin response of the Rocky Mountain bighorn sheep. J. Wildl. Dis. 7: 171-174.
- JUBB, K. V., AND P. C. KENNEDY. 1970. Pathology of Domestic Animals, 2nd Ed. Academic Press, New York, pp. 260-262.
- LANKESTER, M. W., V. J. CRICHTON, AND H. R. TIMMERMANN. 1976. A protostrongylid nematode (Strongylida: Protostrongylidae) in woodland caribou (*Rangifer tarandus caribou*). Can. J. Zool. 54: 680-684.
- , AND T. H. NORTHCOTT. 1979. *Elaphostrongylus cervi* Cameron 1931 (Nematoda: Metastrongyloidea) in caribou (*Rangifer tarandus caribou*) of Newfoundland. Can. J. Zool. 57: 1384-1392.
- NEILAND, K. A. 1972. Sheep disease studies. Alaska Dept. Fish and Game, Juneau. Project Progress Report, Project W-17-3 and W-17-4, 32 pp.
- PRESTWOOD, A. K. 1972. *Parelaphostrongylus andersoni* sp. n. (Metastrongyloidea: Protostrongylidae) from the musculature of white-tailed deer (*Odocoileus virginianus*). J. Parasitol. 58: 897-902.
- , AND S. R. PURSGLOVE. 1974. *Leptostrogylus alpenae* in white-tailed deer (*Odocoileus virginianus*) of Georgia and Louisiana. J. Parasitol. 60: 573.
- PYBUS, M. J., W. J. FOREYT, AND W. M. SAMUEL. 1984. Natural infections of *Parelaphostrongylus odocoilei* (Nematoda: Protostrongylidae) in several hosts and locations. Proc. Helminthol. Soc. Wash. In press.
- SOULSBY, E. J. 1968. Helminths, Arthropods and Protozoa of Domesticated Animals, 7th Ed. Bailliere Tindall, London, England, 809 pp.