

## **BABESIA ODOCOILEI EMERSON AND WRIGHT, 1970 IN WHITE-TAILED DEER, ODOCOILEUS VIRGINIANUS (ZIMMERMANN), IN VIRGINIA**

Authors: Perry, B. D., Nichols, D. K., and Cullom, E. S.

Source: Journal of Wildlife Diseases, 21(2) : 149-152

Published By: Wildlife Disease Association

URL: <https://doi.org/10.7589/0090-3558-21.2.149>

---

BioOne Complete ([complete.BioOne.org](https://complete.BioOne.org)) is a full-text database of 200 subscribed and open-access titles in the biological, ecological, and environmental sciences published by nonprofit societies, associations, museums, institutions, and presses.

Your use of this PDF, the BioOne Complete website, and all posted and associated content indicates your acceptance of BioOne's Terms of Use, available at [www.bioone.org/terms-of-use](https://www.bioone.org/terms-of-use).

Usage of BioOne Complete content is strictly limited to personal, educational, and non - commercial use. Commercial inquiries or rights and permissions requests should be directed to the individual publisher as copyright holder.

---

BioOne sees sustainable scholarly publishing as an inherently collaborative enterprise connecting authors, nonprofit publishers, academic institutions, research libraries, and research funders in the common goal of maximizing access to critical research.

## **BABESIA ODOCOILEI EMERSON AND WRIGHT, 1970 IN WHITE-TAILED DEER, ODOCOILEUS VIRGINIANUS (ZIMMERMANN), IN VIRGINIA**

**B. D. Perry, D. K. Nichols, and E. S. Cullom**

Virginia-Maryland Regional College of Veterinary Medicine,  
Virginia Polytechnic Institute and State University,  
Blacksburg, Virginia 24061, USA

**ABSTRACT:** Pooled blood samples from six white-tailed deer from the Great Dismal Swamp in Virginia were inoculated into two splenectomized deer. A moderately severe clinical reaction ensued, characterized by a hemolytic anemia, and a *Babesia* found in both recipient animals was presumptively identified as *B. odocoilei*. This is the first reported identification of this parasite in white-tailed deer in Virginia.

### **INTRODUCTION**

Bovine babesiosis is widespread in many parts of the world where its tick vectors thrive. The eradication of the vector (*Boophilus annulatus* Say, 1821) in the United States eliminated the disease at the same time (Soulsby, 1982). However, *Babesia* spp. have been subsequently identified in wild animal species in the U.S. including the white-tailed deer (Spindler et al., 1958; Emerson and Wright, 1968; Emerson, 1969; Kingston, 1981), although studies with these isolates have suggested that they are specific to the species of wild animal in which they are found. The species identified in white-tailed deer has been designated *B. odocoilei* (Emerson and Wright, 1970). *Babesia* spp. have not been recorded from deer in Virginia, and this paper is a report of an isolation of a *Babesia* from white-tailed deer inhabiting the Great Dismal Swamp of eastern Virginia.

### **MATERIALS AND METHODS**

Six white-tailed deer were shot and sampled in June 1983 in the Great Dismal Swamp of eastern Virginia, close to the border with North Carolina (Fig. 1). The sex and age of each deer were determined (Severinghaus, 1949).

A post mortem examination was performed, and from each deer, 40 ml of blood were taken, 20 ml into EDTA and 20 ml into oxalate va-

cutainer tubes. Total numbers of ticks were determined for each deer.

Whole blood in anticoagulant was transported at 4 C to Blacksburg, where it was pooled and inoculated into two splenectomized deer 18 hr after collection. Blood samples collected in EDTA were pooled, and 40 ml were inoculated into one deer (20 ml intravenous, 20 ml subcutaneous). Forty ml of the pooled oxalated blood were inoculated in the same manner into the second splenectomized deer. Thin blood smears were prepared from each sample and stained by Giemsa prior to pooling.

Blood samples were taken from the splenectomized deer at weekly intervals for three weeks prior to inoculation, and at three times weekly intervals following inoculation. The deer were observed daily for signs of clinical illness. Packed cell volume (PCV) determinations were made, and Giemsa-stained thin blood smears were examined for the presence of hemoparasites.

### **RESULTS**

The results of the deer sampling are shown in Table 1. Piroplasms were observed only in the two immature deer shot and sampled (Nos. 1 and 2 of Table 1). The highest numbers of ticks were also found infesting these young deer, and the infestations were exclusively *Amblyomma americanum* Linnaeus, 1758; approximately 80% of these were attached to ear pinnae. The remaining 20% were found on the body and limbs.

Piroplasms were first observed in the splenectomized deer 6 days after blood inoculation. Both inoculated deer became

---

Received for publication 28 February 1984.

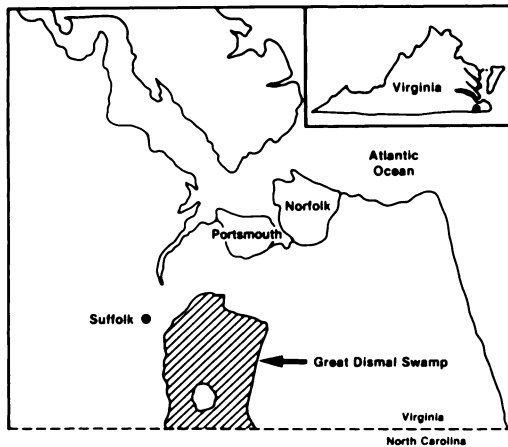


FIGURE 1. Location of the Great Dismal Swamp, Virginia.

anorectic, depressed and anemic. The PCV declined rapidly, falling to 9% in the male deer and 13% in the female deer on day 11 post inoculation (Fig. 2). Both deer recovered.

The piroplasms observed in Giemsa stained thin blood smears of the recipient splenectomized deer were characteristic of a *Babesia* sp., and exhibited single and paired intraerythrocytic bodies which were often located peripherally within parasitized erythrocytes. Piroplasms were pear-shaped, with a prominent nucleus at the wider extremity. They were presumptively identified as *B. odocoilei*. Other blood parasites were not seen.

Representative specimens of the ticks and blood films of *Babesia odocoilei* have been deposited in the Smithsonian Institution (Washington, D.C.) and in the U.S. National Parasite Collection (Beltsville, Maryland) (Accession Nos. RML117480 and 78176 respectively).

#### DISCUSSION

*Babesia* spp. have been described in white-tailed deer in New Mexico (Spindler et al., 1958) and Texas (Emerson and Wright, 1968; Emerson, 1969) while studies in Massachusetts failed to reveal any

TABLE 1. White-tailed deer shot and sampled in the Great Dismal Swamp, Virginia in 1983.

Deer no.	Sex	Weight (kg)	Age (yr)	Total no. <i>Amblyomma americanum</i>	Presence of <i>Babesia odocoilei</i>
1	M	31	1	135	+
2	M	30	1	280	+
3	F	39	4	20	-
4	M	39	2	60	-
5	M	45	2	45	-
6	F	43	5	20	-

*Babesia* spp. in blood films from this species (Piesman et al., 1979). There is no published record of previous identification of this parasite in deer in Virginia (Kingston, 1981).

*Amblyomma americanum*, the tick species abundant on the deer at the time of collection, was considered by Emerson (1969) as a possible vector of *Babesia* spp. *Ixodes scapularis* Say, 1821, another potential vector not found in this case, has been identified previously on white-tailed deer in the Dismal Swamps (Sonenshine, 1979). The closely related species, *Ixodes dammini*, while not recorded in the Dismal Swamps, has been described as the vector of human babesiosis in southern New England (Spielman et al., 1979). The two previous records of *Babesia* spp. in white-tailed deer have differed in the morphological description with that of Spindler et al. (1958) who reported a similarity to *B. bigemina*, and Emerson and Wright (1968) who reported a similarity to *B. divergens*. This parasite deserves further characterization.

Emerson (1969) suggested that *B. odocoilei* may be responsible for clinical manifestations in deer, such as poor physical condition and impaired reproductive performance. The finding of parasitemias only in healthy immature deer in the present study suggests that a situation of enzootic stability (Callow, 1977; Perry et al., in press) may exist. Such a situation is

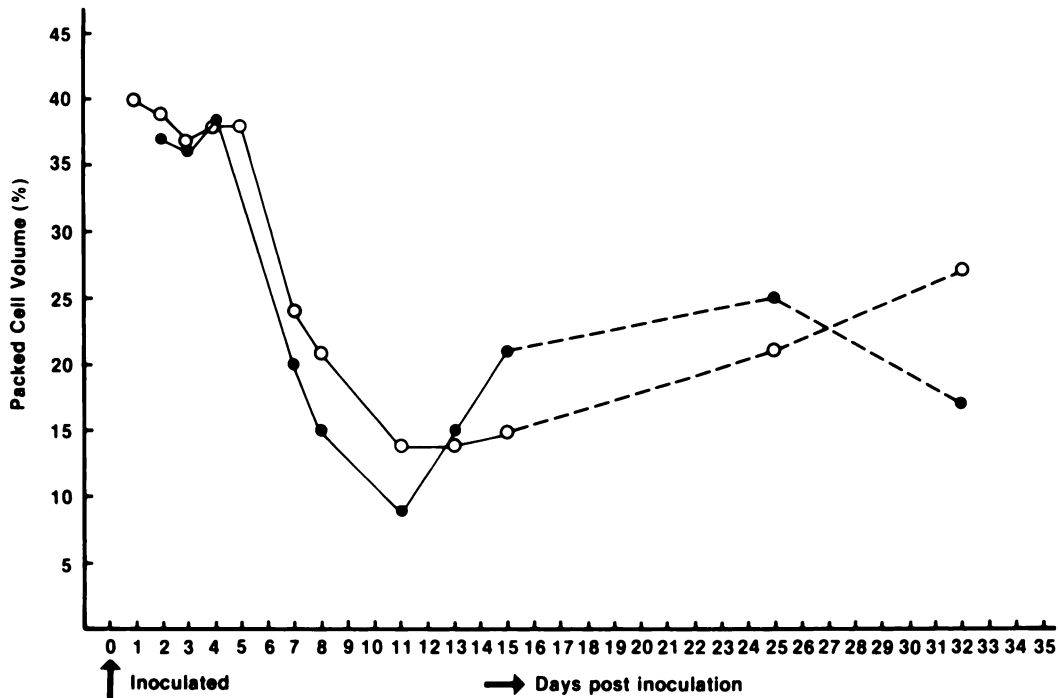


FIGURE 2. Pack cell volume of two splenectomized white-tailed deer following inoculation of pooled *Babesia*-infected blood.

found where the tick challenge is sufficient to infect a significant proportion of the juvenile population while still protected by maternal antibody, resulting in a predominantly immune adult population.

#### ACKNOWLEDGMENTS

This study was carried out under the auspices of the Virginia-Maryland Regional College of Veterinary Medicine Student Chapter of the American Association of Zoo Veterinarians, and the authors wish to acknowledge the assistance and support of members of this organization. The authors also wish to thank the Virginia State Commission for Game and Inland Fisheries, and the United States Fish and Wildlife Service for permission to carry out this study in the Great Dismal Swamp Wildlife Refuge, and for their assistance in doing so. In addition, we would like to acknowledge Professor David Brocklesby and Mr. Duncan Brown, CTVM, University of Edinburgh for their comments on the identity of this parasite, and our record of their observations.

#### LITERATURE CITED

- CALLOW, L. L. 1977. Vaccination against bovine babesiosis. In *Immunity to Blood Parasites of Man and Animals*, L. H. Miller et al. (eds.). Plenum Press, New York, pp. 121-149.
- EMERSON, H. R. 1969. A comparison of parasitic infestations of white-tailed deer (*Odocoileus virginianus*) from central and east Texas. *Bull. Wildl. Dis. Assoc.* 5: 137-139.
- , AND W. T. WRIGHT. 1968. The isolation of a *Babesia* in white-tailed deer. *Bull. Wildl. Dis. Assoc.* 4: 142-143.
- , AND ———. 1970. Correction. *J. Wildl. Dis.* 6: 519.
- KINGSTON, N. 1981. Protozoan parasites. In *Diseases and Parasites of White-tailed Deer*, W. R. Davidson et al. (eds.). Tall Timbers Research Station Misc. Pub. No. 7, pp. 193-236.
- PERRY, B. D., F. L. MUSISI, R. G. PEGRAM, AND H. F. SCHELS. In press. Assessment of enzootic stability to tick-borne diseases. *World Anim. Rev.*
- PIESMAN, J., A. SPIELMAN, P. ETKIND, T. K. RUEBUSH, AND D. D. JURANEK. 1979. Role of deer in the epizootiology of *Babesia microti* in Massachusetts, USA. *J. Med. Entomol.* 15: 537-540.

- SEVERINGHAUS, C. W. 1949. Tooth development and wear as criteria of age in white-tailed deer. *J. Wildl. Manage.* 13: 195-216.
- SONENSHINE, D. E. 1979. Ticks of Virginia (Acari: Metastigmata). Research Division Bulletin 139, Virginia Polytechnic Institute and State University, Blacksburg, Virginia. 44 pp.
- SOULSBY, E. J. L. 1982. Helminths, Arthropods and Protozoa of Domestic Animals, 7th Ed. Balliere Tindall, London, England. 809 pp.
- SPIELMAN, A., C. M. CLIFFORD, J. PIESMAN, AND M. D. CORWIN. 1979. Human babesiosis on Nantucket Island, USA: Description of the vector, *Ixodes (Ixodes) dammini*, n. sp. (Acarina: Ixodidae). *J. Med. Entomol.* 15: 218-234.
- SPINDLER, L. A., R. ALLEN, L. S. DIAMOND, AND J. C. LOTZE. 1958. *Babesia* in a white-tailed deer. *J. Protozool.* 5: 8.