

American Trypanosomiasis (Chagas' Disease) in a Striped Skunk

Authors: Ryan, C. Patrick, Hughes, P. Eric, and Howard, Edwin B.

Source: Journal of Wildlife Diseases, 21(2) : 175-176

Published By: Wildlife Disease Association

URL: <https://doi.org/10.7589/0090-3558-21.2.175>

BioOne Complete (complete.BioOne.org) is a full-text database of 200 subscribed and open-access titles in the biological, ecological, and environmental sciences published by nonprofit societies, associations, museums, institutions, and presses.

Your use of this PDF, the BioOne Complete website, and all posted and associated content indicates your acceptance of BioOne's Terms of Use, available at www.bioone.org/terms-of-use.

Usage of BioOne Complete content is strictly limited to personal, educational, and non - commercial use. Commercial inquiries or rights and permissions requests should be directed to the individual publisher as copyright holder.

BioOne sees sustainable scholarly publishing as an inherently collaborative enterprise connecting authors, nonprofit publishers, academic institutions, research libraries, and research funders in the common goal of maximizing access to critical research.

American Trypanosomiasis (Chagas' Disease) in a Striped Skunk

C. Patrick Ryan, P. Eric Hughes, and Edwin B. Howard, Comparative Medical/Veterinary Services, 12824 Erickson Avenue, Downey, California 90242, USA

Infection with *Trypanosoma cruzi* is called American trypanosomiasis and the clinical or pathological manifestation of the infection is called Chagas' disease (Neva, 1975, *In Diseases Transmitted From Animals To Man*, Hubbert et al. (eds.), Charles Thomas Publishers, Springfield, Illinois, pp. 765-772). Animal and triatomid bug infections with *T. cruzi* are widespread in the southern United States, from California to Florida and Maryland (Ciba Foundation Symposium, 1974, *Excerpta Med.* 20: 51). Approximately 100 species of triatomid insects have been identified and about half have been found to be naturally infected with *T. cruzi* or *T. cruzi*-like organisms. Sylvatic reservoirs of *T. cruzi*-like organisms include about 150 species or subspecies of Marsupialia, Carnivora, Chiroptera, Rodentia, Edentata, Lagomorpha and Primates. Norman (1959, *J. Parasitol.* 45: 457-463) reported a prevalence of 1% for *T. cruzi*-like organisms in 306 striped skunks caught in southern Georgia and northern Florida.

A surveillance program in Los Angeles County resulted in the detection of a case of Chagas' disease in a young adult male, native, free-living, striped skunk. The skunk was collected from Griffith Park in Los Angeles, California. At necropsy, gross lesions were not evident. Microscopically, there was marked subacute to chronic multifocal myocarditis with clusters of plasma cells, lymphocytes and macrophages in the wall of the right atrium (Fig. 1). Thin, patchy moderate areas of fibrosis were often associated with the inflammation. In some sections of atrial wall, pseu-

docysts containing amastigotes which were indistinguishable from those of *T. cruzi* were seen within myofibers (Fig. 2). The pseudocysts contained spherical organisms, some of which had a nucleus and kinetoplast.

There was a moderate multifocal non-suppurative meningitis which had a tendency towards perivascular orientation. The brain stem and cerebellar white matter contained moderate multi-focal encephalitis, characterized by lymphocytic perivascular infiltrates often associated with gliosis. Brain smears examined by the direct fluorescent antibody technique for rabies were negative. Sections of liver, kidney, lung, mesenteric lymph node and intestine were unremarkable.

The lesions observed were consistent with those reported in dogs with natural and experimental infection with *T. cruzi* (Andrade et al., 1981, *Arch. Pathol. Lab. Med.* 106: 460-464; Snider et al., 1980, *J. Am. Vet. Med. Assoc.* 177: 247-249; Wil-

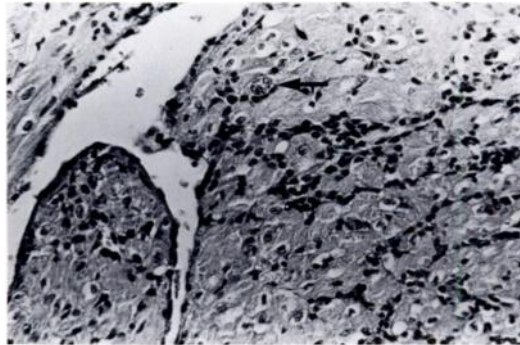


FIGURE 1. Subacute myocarditis of the right atrium of the heart of a striped skunk. The atrial endocardium is shown. One *T. cruzi* pseudocyst (arrow) is seen associated with the inflammation. H&E, $\times 250$.

Received for publication 31 July 1984.

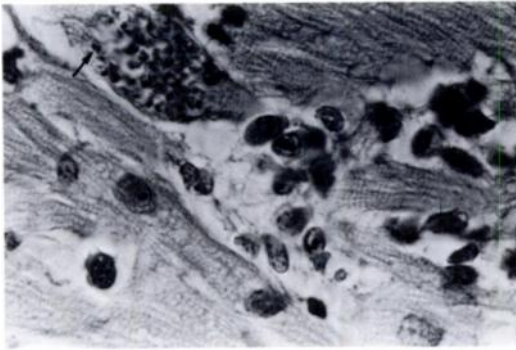


FIGURE 2. Pseudocyst of *T. cruzi* associated with mononuclear cell inflammation in a striped skunk. Amastigotes contain a nucleus and a kinetoplast (arrow) H&E, $\times 1,000$.

liams et al., 1977, J. Am. Vet. Med. Assoc. 171: 171-178). The amastigotes of *Leishmania* spp. and *T. cruzi* can be differentiated by their tissue tropism, but not by light microscopic morphology. *Leishmania* spp. are generally contained in macrophages and *T. cruzi* generally parasitize cardiac myofibers and, to a lesser extent, brain (Edgecomb and Johnson, 1976, *In Pathology of Tropical and Extraordinary Diseases*, Vol. 1, Binford and Connor (eds.), Armed Forces Institute of Pathology, Washington, D.C., pp. 244-251). *Toxoplasma gondii* does not contain a kinetoplast. Other coccidial bradyzoite cysts such as *Sarcocystis*, *Hammondia*, *Frankelia*, and *Besnoitia* were ruled out on morphologic appearance. *Encephalitozoon* can cause a similar encephalitis and occasionally meningitis. Vasculitis is the primary lesion, but that organism stains poorly with H&E and special stains were negative for *Encephalitozoon*.

Serum from the skunk was tested using indirect hemagglutination and was negative for antibodies to *T. gondii*. Serum from the skunk was tested by the Centers for Disease Control, Atlanta using complement fixation and direct agglutination and was positive for antibodies to *T. cruzi* (U.S. Public Health Service, 1962, *In Laboratory Branch Training Manual*, Communicable Disease Center, Atlanta, Georgia, pp. 1-34). The titer for complement fixation was 1:32 and for direct agglutination 1:64.

American trypanosomiasis in the United States is seldom considered in the differential diagnosis of cardiac disease in humans or other mammals. Three human autochthonous cases of Chagas' disease have been reported in the United States (Calif. Morbidity, 1982, No. 40; Greer, 1955, Texas Public Health Bull. 9: 11-13; Woody and Woody, 1955, J. Am. Med. Assoc. 159: 676-677). Fatal cases of trypanosomiasis have been reported in dogs in the United States with histological lesions most pronounced in the heart (Snider et al., 1980, op. cit.; Williams et al., 1977, op. cit.). Histological findings of meningoencephalitis and multifocal myocarditis with amastigote pseudocysts in the cardiac tissue of this skunk are consistent with what has been seen in human, canine and murine cases of Chagas' disease.

The skunk was obtained from a locality in California which is known to be endemic to *T. cruzi*. In 1967 33% of *Triatoma protracta* in this area were positive for *T. cruzi* (Wood and Wood, 1967, Pac. Insects 9: 537-550).