



## **Starvation Secondary to an Oral Fibroma in a Wild Mountain Goat (*Oreamnos americanus*)**

Authors: Foreyt, W. J., and Leathers, C. W.

Source: Journal of Wildlife Diseases, 21(2) : 184-185

Published By: Wildlife Disease Association

URL: <https://doi.org/10.7589/0090-3558-21.2.184>

---

BioOne Complete ([complete.BioOne.org](https://complete.BioOne.org)) is a full-text database of 200 subscribed and open-access titles in the biological, ecological, and environmental sciences published by nonprofit societies, associations, museums, institutions, and presses.

Your use of this PDF, the BioOne Complete website, and all posted and associated content indicates your acceptance of BioOne's Terms of Use, available at [www.bioone.org/terms-of-use](https://www.bioone.org/terms-of-use).

Usage of BioOne Complete content is strictly limited to personal, educational, and non - commercial use. Commercial inquiries or rights and permissions requests should be directed to the individual publisher as copyright holder.

---

BioOne sees sustainable scholarly publishing as an inherently collaborative enterprise connecting authors, nonprofit publishers, academic institutions, research libraries, and research funders in the common goal of maximizing access to critical research.

## Starvation Secondary to an Oral Fibroma in a Wild Mountain Goat (*Oreamnos americanus*)

W. J. Foreyt and C. W. Leathers, Department of Veterinary Microbiology and Pathology, Washington State University, Pullman, Washington 99164, USA

In February 1982 a wild mountain goat (*Oreamnos americanus*) near Newhalen, Washington, was observed to be weak and disoriented. Two days later it died and was submitted frozen to the Washington Animal Disease Diagnostic Laboratory.

At necropsy, the 6-yr-old male goat weighed approximately 35 kg and was extremely emaciated. A fleshy mass, approximately 4 × 18 × 4 cm was attached to the broad base of the palate, slightly more on the left side than the right (Fig. 1). The mass was covered by intact epithelium and the cut surface glistened and oozed pale yellow fluid. Samples of the mass sank in 10% buffered formalin. Some distortion of cheek teeth, especially the lower arcades (Fig. 2) was associated with the mass.

Histologically, sections of the mass were edged by intact, partially keratinized squamous epithelium. The majority of each sectional area was composed of loosely arranged sheets of small spindle-shaped cells with abundant, eosinophilic fibrillar cytoplasm (Fig. 3). The stromal component was also fibrillar, and eosinophilic. Vessels within the stroma were sparse, and varied from muscular arteries to capillaries. Inflammatory cells were conspicuously absent. The tissue changes were consistent with a well-differentiated fibroma. A representative paraffin-embedded block of the fibroma was deposited in the Registry of Comparative Pathology, Armed Forces Institute of

Pathology, Washington, D.C. 20306, USA (Accession No. 1955866).

Other gross pathologic findings included 65 specimens of *Parelaphostrongylus odocoilei* in the musculature, more than 20 specimens of *Protostrongylus rushi* in the lungs, 650 specimens of *Nematodirus helvetianus* in the small intestine, 3,510

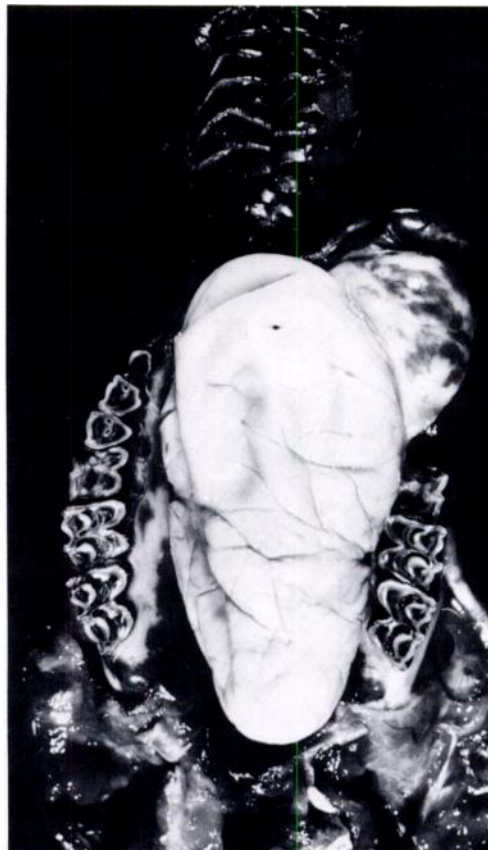


FIGURE 1. Oral fibroma attached to the palate of a 6-yr-old mountain goat.

Received for publication 23 July 1984.

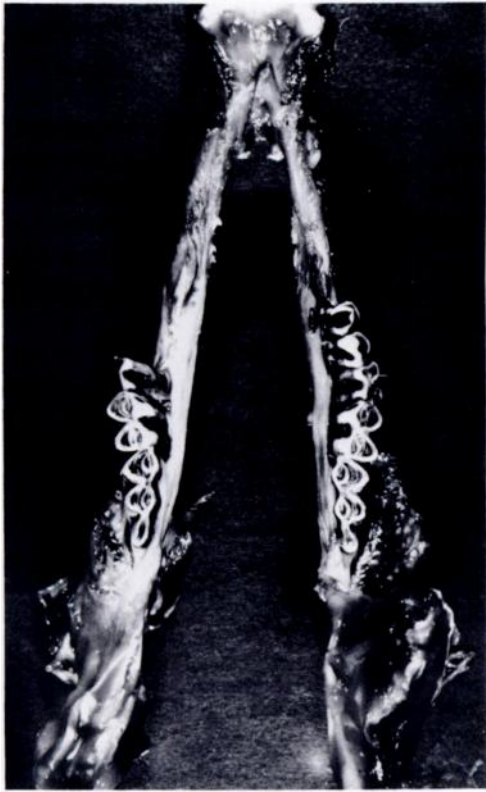


FIGURE 2. Mandibles of a 6-yr-old mountain goat with displacement of teeth by an oral fibroma.

specimens of *Ostertagia* spp. in the abomasum and 20 specimens of *Trichuris schumakovitschi* in the large intestine.

Representative nematodes were deposited as follows: *Parelaphostrongylus odocoilei* in the National Museum of Canada Invertebrate Collection, Ottawa, Ontario (No. NMCIC(P) 0028), and *Protostrongylus rushi* (No. 78423), *Nematodirus helvetianus* (No. 78420), *Ostertagia* spp. (No. 78422), *Trichuris schumakovitschi* (No. 78421) in the U.S. National Parasite Collection, Beltsville, Maryland 20705, USA.

Based on the clinical history and the gross and histopathological observations, the goat apparently starved because of the physical interference by the neoplasm with




FIGURE 3. Photomicrograph of fibroma of a 6-yr-old mountain goat, with prominent fibrous stroma (H&E,  $\times 160$ ).

mastication and swallowing. Parasitism may also have been a contributing factor to the starvation.

The mountain goat (Family Bovidae) is not a true goat, but a mountain antelope with no close relatives in North America. Diseases of mountain goats have been summarized (Cowan, 1951, Proc. 5th Ann. Brit. Col. Game Conven. 5: 37-64; Brandborg, 1955, Life History and Management of the Mountain Goat in Idaho, Bull. No. 2, Idaho Fish and Game Dept., Boise, Idaho, pp. 110-114; Rideout and Hoffmann, 1975, Mammalian Species 63: 1-6; Foster, 1977, First Int. Mountain Goat Symp., Kalispell, Montana, pp. 226-243; Johnson, 1983, Mountain Goats and Mountain Sheep of Washington, Bio. Bull. No. 18, pp. 44-52), but to our knowledge this is the first oral fibroma reported from this host. These neoplasms have been reported from other ruminants (Cotchin, 1960, Vet. Rec. 72: 816-822; Anderson and Sandison, 1969, Vet. Pathol. 98: 253-263; Head, 1976, Bull. W.H.O. 53: 145-166). It is likely that because of the relatively inaccessible habitat of mountain goats, neoplasms and other diseases are not observed as frequently as in other wild and domestic ruminants.