BioOne COMPLETE

Muscovy Duck Mortality Not Caused by Haemoproteus

Authors: Julian, R. J., Beveridge, T. J., and Gait, D. E.

Source: Journal of Wildlife Diseases, 21(3) : 335-337

Published By: Wildlife Disease Association

URL: https://doi.org/10.7589/0090-3558-21.3.335

BioOne Complete (complete.BioOne.org) is a full-text database of 200 subscribed and open-access titles in the biological, ecological, and environmental sciences published by nonprofit societies, associations, museums, institutions, and presses.

Your use of this PDF, the BioOne Complete website, and all posted and associated content indicates your acceptance of BioOne's Terms of Use, available at www.bioone.org/terms-of-use.

Usage of BioOne Complete content is strictly limited to personal, educational, and non - commercial use. Commercial inquiries or rights and permissions requests should be directed to the individual publisher as copyright holder.

BioOne sees sustainable scholarly publishing as an inherently collaborative enterprise connecting authors, nonprofit publishers, academic institutions, research libraries, and research funders in the common goal of maximizing access to critical research.

Downloaded From: https://bioone.org/journals/Journal-of-Wildlife-Diseases on 25 Apr 2024
Terms of Use: https://bioone.org/terms-of-use

Journal of Wildlife Diseases, 21(3), 1985, pp. 335–337
© Wildlife Disease Association 1985

LETTER TO THE EDITOR . . .

Muscovy Duck Mortality Not Caused by *Haemoproteus*

R. J. Julian, Department of Pathology, University of Guelph, Guelph, Ontario N1G 2W1, Canada; **T. J. Beveridge,** Department of Microbiology, University of Guelph, Guelph, Ontario N1G 2W1, Canada; **and D. E. Galt,** Veterinary Laboratory Services, Ontario Ministry of Agriculture and Food, Brighton, Ontario K0K 1H0, Canada

An unusual disease of muscovy ducks (*Cairina moschata* L.) kept on lakes and ponds in association with wild waterfowl has been recognized in Ontario, Canada since 1970 (Julian and Galt, 1980, J. Wildl. Dis. 16: 39–44). Fourteen outbreaks of this disease in muscovy ducks in which part or all of the flock have died have now been recorded. Affected ducks have been in small farm flocks, but mortality has been high and has continued until the flock was moved from the pond. In several cases all of the ducks in the flock have died over a period of several weeks. Clinical signs included weakness and ataxia with respiratory distress terminally.

Received for publication 4 May 1984.

The original investigation indicated that the mortality was caused by schizonts of

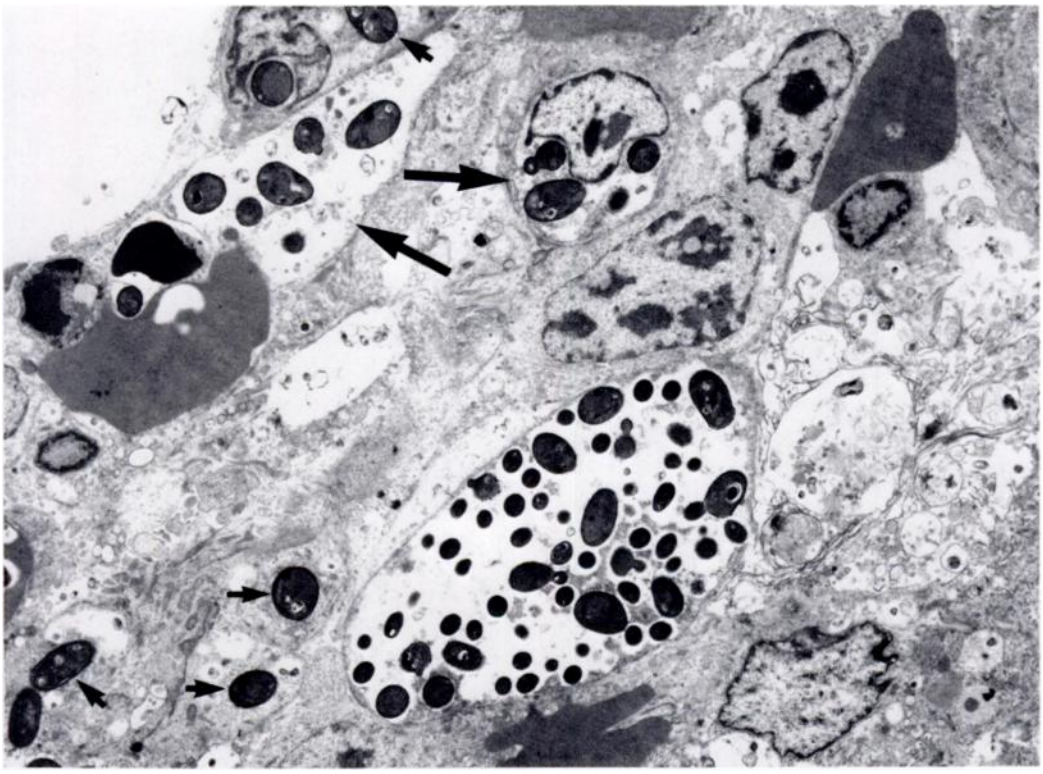

FIGURE 1. Large number of variable sized bacillae within a vacuole (lower center) in the cytoplasm of a pulmonary capillary endothelial cell of a muscovy duck. Small numbers of organisms are present in several other cells in the figure (arrows). ×4,800.

Downloaded From: https://bioone.org/journals/Journal-of-Wildlife-Diseases on 25 Apr 2024
Terms of Use: https://bioone.org/terms-of-use

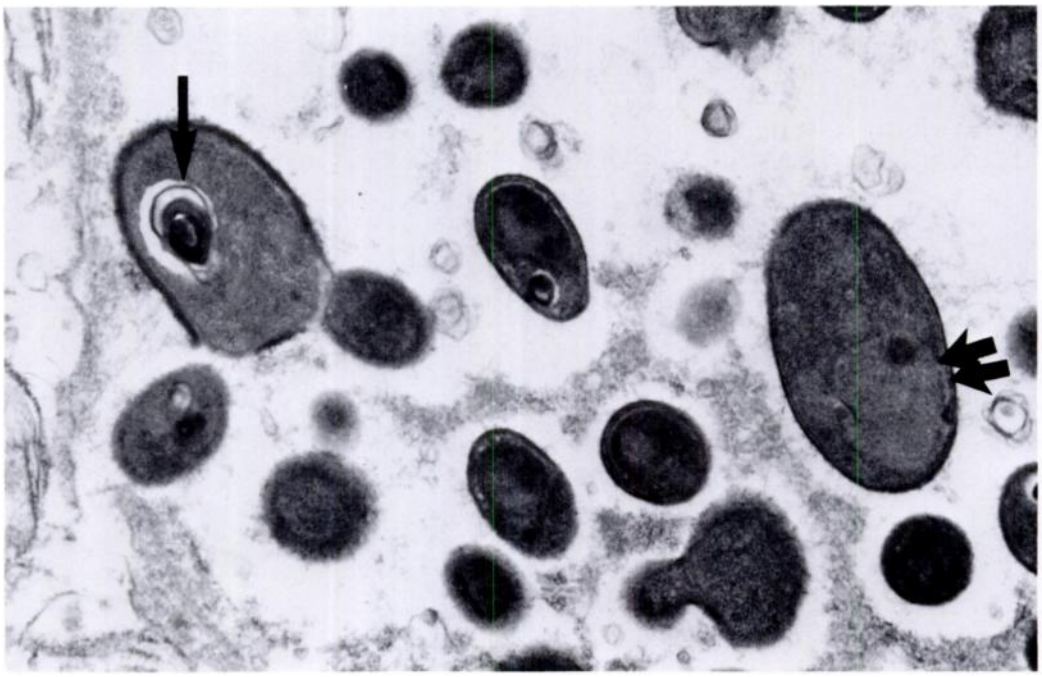

FIGURE 2. Higher magnification of the organisms in Figure 1. Single arrow points to a mesosome. Double arrow indicates the membranes associated with the initial events leading to sporulation. ×25,000.

Haemoproteus associated with severe pneumonitis, as has been reported with infection by *Plasmodium* in penguins (Fleischman et al., 1968, J. Am. Vet. Med. Assoc. 153: 928–935). Further study of the disease has revealed that it is not caused by *Haemoproteus*. Electron microscopic (EM) examination has identified the organisms in the endothelial cells of blood vessels as clusters of bacteria rather than haemoproteid schizonts as described in the 1980 paper (Julian and Galt, 1980, op. cit.). The intracellular bacteria have been identified as a *Bacillus* species (Figs. 1, 2).

In thin sections the bacteria appear to be rods, approximately 0.5–1.0 μm in diameter, which possess a typical Gram-positive wall (Beveridge, 1981, Int. Rev. Cytol. 72: 229–317). Some bacteria have intramembranous intrusions which are reminiscent of mesosomes, whereas other intrusions are more extensive and occur exclusively at the cell poles. These intrusions probably correspond to the initial engulfment events leading to sporulation (Fig. 2). Vegetative cells divide by septation. These bacteria have been identified in all of the outbreaks in which EM examination has been done (7/14) including the original case. The organism is present in large numbers in the endothelial cells of the lung and spleen and in smaller numbers throughout the body. Affected ducks die from respiratory failure because of lung edema and pneumonia and all have a swollen reactive spleen and swollen liver. Encephalitis is present in some affected ducks and the organisms are prominent in the vascular endothelium of the brain. The bacteria are blue when histologic preparations are stained with hematoxylin and eosin and Giemsa stains. They are red (Gram negative) with Brown and Brenn stain, in spite of the typical Gram-positive wall identified on EM. They are larger with a red perimeter and

Downloaded From: https://bioone.org/journals/Journal-of-Wildlife-Diseases on 25 Apr 2024
Terms of Use: https://bioone.org/terms-of-use

clear center with periodic acid–Schiff stain (probably due to a PAS positive capsule).

In August 1983 two natural outbreaks of the condition provided the opportunity for further investigation. One ml of a solution of 4 g of ground lung from a recently dead muscovy duck in 20 ml of saline, filtered through cheesecloth, was injected subcutaneously into three 8-wk-old muscovy and three 8-wk-old Pekin ducks. One muscovy was found dead on day 11 post-injection. The other two muscovy ducks showed mild lameness, slight depression and mouth breathing on days 11 and 12. They appeared brighter on day 13 and were killed for necropsy. None of the Pekin ducks showed signs of illness and they were killed for necropsy on day 13.

The muscovy which died on day 11 showed typical gross and histologic lesions with pneumonia, lung edema and marked splenomegaly and hepatomegaly. The two muscovy ducks killed on day 13 showed mild pneumonia and marked splenomegaly and hepatomegaly. Intracellular organisms were present in the lung, spleen and other organs of all three ducks with very large numbers in the duck which had died. The Pekin ducks were normal at necropsy and no lesions or organisms were present in the tissues.

The trial was repeated using lung from the duck which had died. The second passage produced no clinical signs and only mild pneumonia with moderate splenomegaly and hepatomegaly in the muscovy ducks which were killed at day 13. Only scattered clusters of organisms were found in endothelial cells of the lung and spleen. The Pekin ducks were again negative.

A third passage produced no gross lesions and on histologic examination only a moderate lymphoid (antigenic) reaction in the lung and spleen of the muscovy ducks necropsied on day 13.

The trial was repeated with negative results with lung tissue from the index case which had been held at −70 C.

In 1972 (Julian and Galt, 1980, op. cit.) the disease was passed in the laboratory from a healthy Pekin duck, which had been kept on a pond where the disease had occurred naturally on several occasions, to two of five muscovy ducks by intraperitoneal injection of venous blood from the Pekin duck. This would suggest that the organisms may circulate in monocytes of carrier waterfowl and may be spread by blood-sucking insects.

The 1983 cases also provided the opportunity for attempting culture of this intracellular bacterium, however, aerobic, anaerobic and reduced oxygen tension culture on blood agar, Sabouraud's agar and in meat broth was negative. Culture in embryonating turkey eggs was also negative in one trial.

Downloaded From: https://bioone.org/journals/Journal-of-Wildlife-Diseases on 25 Apr 2024
Terms of Use: https://bioone.org/terms-of-use