



## **Fatal Systemic Toxoplasmosis in a Wild Turkey**

Authors: Howerth, E. W., and Rodenroth, Nina

Source: Journal of Wildlife Diseases, 21(4) : 446-449

Published By: Wildlife Disease Association

URL: <https://doi.org/10.7589/0090-3558-21.4.446>

---

BioOne Complete ([complete.BioOne.org](https://complete.BioOne.org)) is a full-text database of 200 subscribed and open-access titles in the biological, ecological, and environmental sciences published by nonprofit societies, associations, museums, institutions, and presses.

Your use of this PDF, the BioOne Complete website, and all posted and associated content indicates your acceptance of BioOne's Terms of Use, available at [www.bioone.org/terms-of-use](https://www.bioone.org/terms-of-use).

Usage of BioOne Complete content is strictly limited to personal, educational, and non - commercial use. Commercial inquiries or rights and permissions requests should be directed to the individual publisher as copyright holder.

---

BioOne sees sustainable scholarly publishing as an inherently collaborative enterprise connecting authors, nonprofit publishers, academic institutions, research libraries, and research funders in the common goal of maximizing access to critical research.

mals, however, are very rare. Migaki (1978, op. cit.) reported the incidental finding of *Cryptococcus* infection in a captive Atlantic bottlenose dolphin (*Tursiops truncatus*) that died of septicemia resulting from a perforated gastric ulcer.

*Journal of Wildlife Diseases*, 21(4), 1985, pp. 446-449  
© Wildlife Disease Association 1985

## Fatal Systemic Toxoplasmosis in a Wild Turkey

**E. W. Howerth**, Southeastern Cooperative Wildlife Disease Study, Department of Parasitology, College of Veterinary Medicine, University of Georgia, Athens, Georgia 30602, USA; and **Nina Rodenroth**, Department of Anatomy and Radiology, College of Veterinary Medicine, University of Georgia, Athens, Georgia 30602, USA

*Toxoplasma gondii* is a protozoan parasite belonging to the phylum Apicomplexa, class Sporozoa, subclass Coccidia, order Eucoccidiida and suborder Eimeriina (Levine et al., 1980, J. Protozool. 27: 37-58). Cats and other Felidae are the only definitive hosts for this coccidian parasite, but a wide range of vertebrates including birds and mammals can act as intermediate hosts. The life cycle of this parasite has been reviewed by several authors (Dreesen and Lubroth, 1983, Compend. Cont. Ed. 5: 456-460; Greene and Prestwood, 1984, In Clinical Microbiology and Infectious Diseases of the Dog and Cat, W. B. Saunders, Philadelphia, Pennsylvania, pp. 826-840).

Infection by *T. gondii* most often is inapparent clinically with the formation of bradyzoite-containing tissue cysts which may persist for the life of the host. Occasionally, clinical toxoplasmosis develops during the primary infection by *T. gondii* or following relapse subsequent to immunosuppression or for unknown reasons (Dreesen and Lubroth, 1983, op. cit.). We believe this is the first report of fatal toxoplasmosis in a free-ranging wild turkey (*Meleagris gallopavo*).

In December 1983, a free-ranging female wild turkey, weighing 2.72 kg, was found dead on Blue Ridge Wildlife Management Area, Union County, Georgia. The carcass was frozen and submitted subsequently for necropsy.

At necropsy, massive splenomegaly was the most striking feature. Severe pneumonia, characterized by focal to confluent gray areas of consolidation, was present. Multiple 1- to 2-mm-diameter erosions covered by pseudomembranous exudate studded the cecal and colonic mucosa.

Representative samples of lung, spleen, liver, kidney, adrenal, esophagus, gizzard, proventriculus, brain, colon, and ovary were fixed in 10% buffered formalin, embedded in paraffin, sectioned at 7  $\mu$ m, and stained with hematoxylin and eosin, Giemsa, Gram's and periodic acid-Schiff. For electron microscopy, pieces of formalin-fixed lung were embedded in Spurr resin, thin sectioned, and stained with uranyl acetate and lead citrate.

Histologic examination of the spleen revealed diffuse necrosis with massive fibrinous exudation and scattered accumulations of macrophages. In the lung, there was nonsuppurative interstitial pneumonia involving many respiratory lobules. Walls of air capillaries were thickened by lymphocyte and macrophage infiltration

---

Received for publication 4 February 1985.

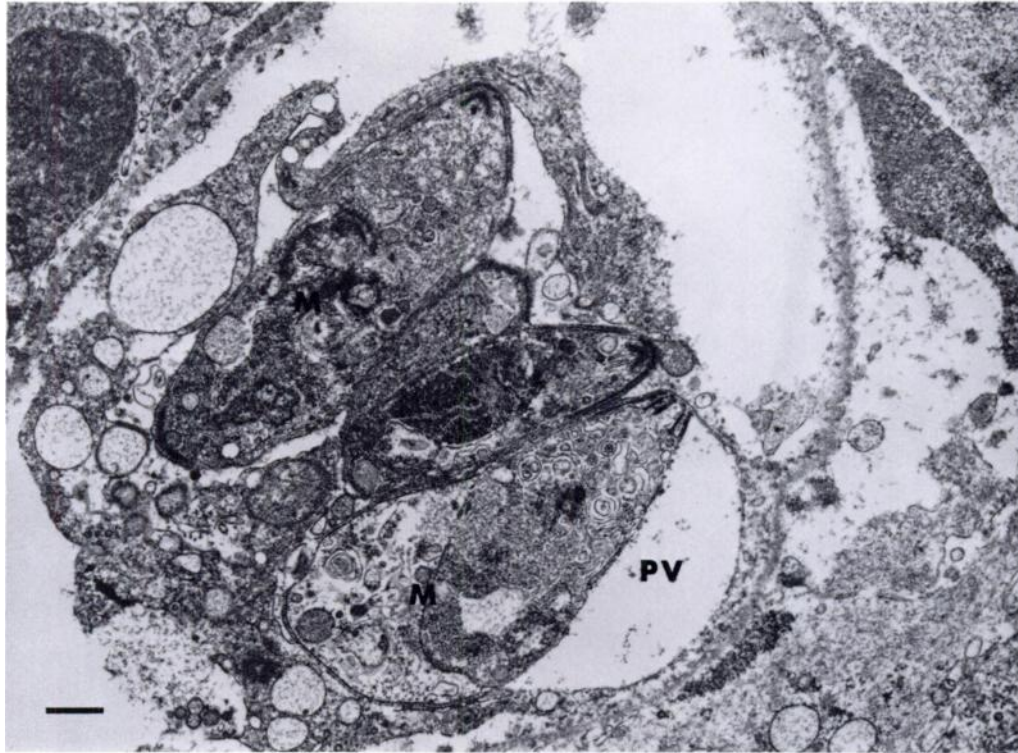


FIGURE 1. Electron micrograph of lung of wild turkey showing intracellular clone. Note dividing merozoites (M) within parasitophorous vacuole (PV). Bar = 0.5  $\mu$ m.

and air capillaries were filled with macrophages. Small foci of necrosis involving walls of air capillaries were scattered throughout the lung and interlobular septa were widened by edema fluid and macrophage infiltration.

Multiple focal areas of necrosis, infiltrated with variable numbers of macrophages, were present in the adrenal, white matter of the brain stem and cerebellar cortex, kidney, liver, lamina propria of the proventriculus, and tunica muscularis of the esophagus. Multiple foci of mucosal necrosis and ulceration were present in the colon. An intense infiltration of macrophages and lymphocytes was present in the wall underlying these areas, and ulcerated foci were covered by a layer of necrotic inflammatory cells. Adjacent to areas of necrosis and inflammation in the adrenal, brain, kidney, liver, proventric-

ulus, and spleen, there was segmental, transmural, necrotizing vasculitis, often with thrombosis.

Protozoa, either lying free or in intracellular clones, were found in areas of vascular and parenchymal necrosis and inflammation in the spleen, lung, adrenal, brain, kidney, liver, proventriculus, esophagus, and colon. Individual organisms measured 3 to 4  $\mu$ m in length and 1 to 2  $\mu$ m in diameter, with one end more rounded than the other, and a nucleus in the more rounded end. Single or multiple groups, ranging from 5 to 10  $\mu$ m in diameter and containing four to 25 organisms, were observed within macrophages, parenchymal cells, and vascular smooth muscle. The organisms stained well with hematoxylin and eosin and with Giemsa stain, but failed to stain with a Gram's stain or periodic acid-Schiff.

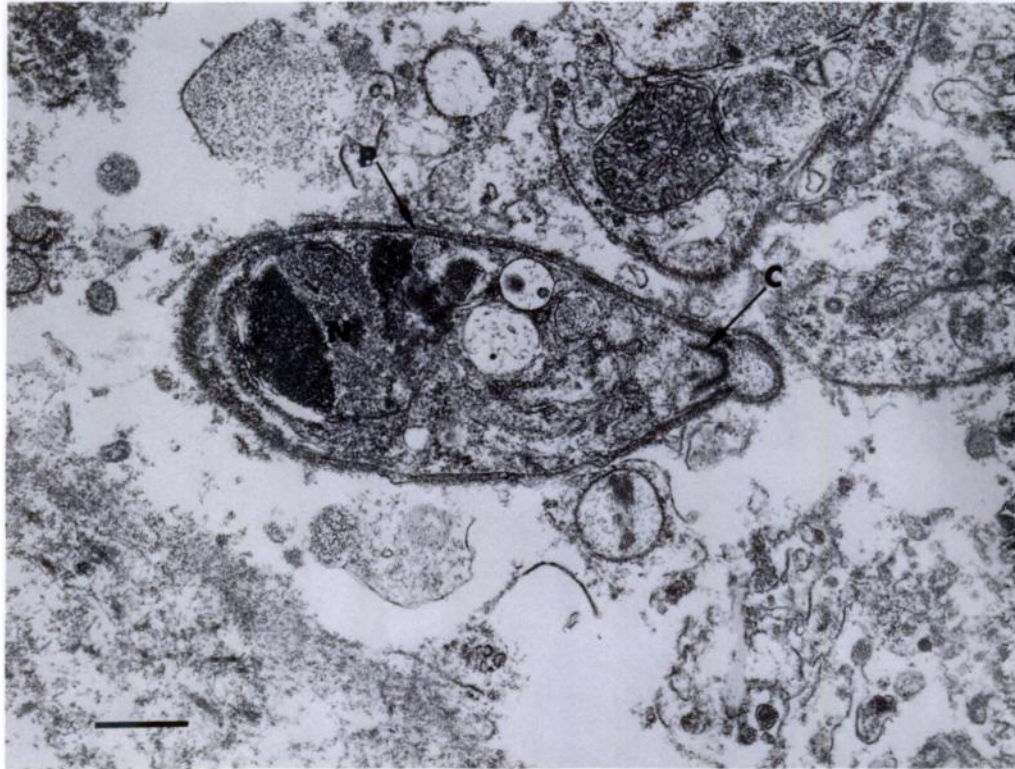


FIGURE 2. Electron micrograph of lung of wild turkey showing individual zoite. Note pellicle (P), conoid (C) in anterior end, and nucleus with nucleolus (N) in posterior end. Bar = 0.5  $\mu$ m.

Transmission electron microscopy of the lung revealed elongate, sometimes crescent-shaped, zoites approximately 4  $\mu$ m long and 1.5  $\mu$ m wide either lying free or intracellularly within a parasitophorous vacuole (Fig. 1). Individual zoites were bounded by a pellicle composed of two membranes—a complete outer membrane and an inner membrane with small interruptions that terminated at the polar ring in the anterior end. Just inside the polar ring, the pointed anterior end contained the conoid. A large nucleus with a nucleolus was present in the rounded posterior pole, but other organelles were difficult to identify due to swelling and degeneration of the organisms (Fig. 2).

Sections of spleen were suspicious for *T. gondii* on the direct fluorescent antibody test, but inoculation of mice with splenic

tissue failed to reveal the presence of the organism.

Gross and light and electron microscopic findings were compatible with a diagnosis of toxoplasmosis. The presence of both necrotizing and granulomatous lesions with vascular involvement occurs in toxoplasmosis in other species, including domestic poultry (Siim et al., 1963, Adv. Vet. Sci. 8: 335–429). The ultrastructural characteristics of the zoites were typical of the coccidian group Apicomplexa, including presence of a pellicle, polar ring, conoid, and large nucleus (Scholtyseck, 1979, *In Fine Structure of Parasitic Protozoa*, Springer-Verlag, New York, New York, pp. 15–34). The small size of the zoites, coupled with the fact that the zoites were separated from the host cell cytoplasm by a parasitophorous vacuole and

were not residing free within the host cell cytoplasm, indicated that the organisms probably were *Toxoplasma gondii* (Dubey et al., 1982, Am. J. Vet. Res. 43: 2147–2164; Sheffield and Melton, 1968, J. Parasitol. 54: 209–226) and not one of the other “cyst-forming” coccidia. The inconclusive direct fluorescent antibody test and negative mouse inoculation studies probably were the result of detrimental effects of freezing and thawing of the tissues or organisms prior to performing these tests.

Although the prevalence of *T. gondii* in wild turkeys has not been studied, there is evidence that other species of wild birds frequently are infected (Sanger, 1971, *In Infectious and Parasitic Diseases of Wild*

Birds, Iowa State Univ. Press, Ames, Iowa, pp. 313–316). However, *T. gondii* rarely causes clinical disease in wild birds, and toxoplasmosis apparently is not a significant cause of death in wild turkeys.

This study was supported by an appropriation from the Congress of the United States to the Southeastern Cooperative Wildlife Disease Study, Department of Parasitology, College of Veterinary Medicine, University of Georgia. Funds were administered and research coordinated under the Federal Aid in Wildlife Restoration Act (50 Stat. 917) and through Contract Number 14-16-0004-83-004, Fish and Wildlife Service, U.S. Department of the Interior.

*Journal of Wildlife Diseases*, 21(4), 1985, pp. 449–450  
© Wildlife Disease Association 1985

## **Microfilariae of *Tetrapetalonema llewellyni* in Raccoons of Cades Cove, Great Smoky Mountains National Park, Tennessee, USA**

**Alan R. Rabinowitz**, Ecology Program, University of Tennessee, Knoxville, Tennessee 37916, USA; **and Sharon Patton and Vicki Major**, Department of Pathobiology, College of Veterinary Medicine, University of Tennessee, Knoxville, Tennessee 37901, USA

Five species of filarial worms are known from the raccoon, *Procyon lotor*, in the United States; *Dirofilaria immitis*, *D. tenuis*, *Dipetalonema (Acanthocheilonema) procyonis* and *Tetrapetalonema llewellyni* were reported by Herman and Price (1965, J. Wildl. Manage. 29: 695–699) and *Brugia beaveri* by Ash and Little (1964, J. Parasitol. 50: 119–123). The objectives of this study were to determine the species of microfilariae present in the blood of free-ranging raccoons in Cades Cove, an

area of the Great Smoky Mountains National Park, Tennessee, and to evaluate the role of raccoons as a reservoir of filarial nematode infection for other animals in the park. Cades Cove is a protected, unmanaged area which is relatively isolated by mountains on three sides. There are tourist facilities and a campground on the extremities of the cove, thus the raccoons maintain some contact with humans and domestic pets. Also 50–100 cattle are permitted to graze within the cove. The area also has a wildlife community.

Raccoons were captured from September 1979 through September 1980 and

---

Received for publication 30 December 1981.