

Cleft Palate in a Tule Elk Calf

Authors: Gogan, Peter J. P., and Jessup, David A.

Source: Journal of Wildlife Diseases, 21(4) : 463-466

Published By: Wildlife Disease Association

URL: <https://doi.org/10.7589/0090-3558-21.4.463>

BioOne Complete (complete.BioOne.org) is a full-text database of 200 subscribed and open-access titles in the biological, ecological, and environmental sciences published by nonprofit societies, associations, museums, institutions, and presses.

Your use of this PDF, the BioOne Complete website, and all posted and associated content indicates your acceptance of BioOne's Terms of Use, available at www.bioone.org/terms-of-use.

Usage of BioOne Complete content is strictly limited to personal, educational, and non - commercial use. Commercial inquiries or rights and permissions requests should be directed to the individual publisher as copyright holder.

BioOne sees sustainable scholarly publishing as an inherently collaborative enterprise connecting authors, nonprofit publishers, academic institutions, research libraries, and research funders in the common goal of maximizing access to critical research.

earlier findings. Presence of small intracellular accumulations of hemosiderin in hepatocytes of infected liver, in red pulp cells of spleen and in alveolar epithelial cells of lungs may indicate that chronic vascular congestion leading to minute hemorrhages is the host response to eggs of *L. learedi* and *N. schistosomatoides*. Furthermore, Wolke et al. (1982, op. cit.), who also found hemosiderin in kidney, liver and spleen of heavily infected loggerhead turtles, *Caretta caretta* (L.), suggested that hemolytic anemia may be a significant factor in spirorchid infections, but we did not investigate this aspect.

Clinical signs of the disease that we observed resembled those described for other species of turtles by various workers, namely Glazebrook et al. (1981, op. cit.) in green turtles, Holliman et al. (1971, J. Parasitol. 57: 71–77) in painted turtles, *Chrysemys picta picta* (Herm.), and Wolke et al. (1982, op. cit.) in loggerhead turtles infected with spirorchids in each case.

In one turtle there were intense, multifocal lymphocytic infiltrations among red pulp cells of spleen, hepatocytes and lung epithelial cells. In two others, small intracellular accumulations of hemosiderin were present throughout the liver in hepatocytes and spleen in red pulp cells, but

were confined within granulomas in the lungs (Fig. 2), which also exhibited a marked interstitial pulmonary edema. Edema also occurred in subcutaneous tissues. This condition may be a sign of cachexia resulting from vascular damage and from increased blood pressure caused by obstruction of blood capillaries by eggs. It may have been compounded by the clumps composed of many spirorchid adults that we saw in all heart chambers and in a major arteriole serving the lungs. The structural changes and physiological impairment caused by the spirorchid infections may make the turtles more susceptible to predators and to bacterial and mycotic pathogens, and less able to cope with inclement weather. In these ways mortality in populations of wild turtles may be increased.

Representative specimens of *L. learedi* and *N. schistosomatoides* have been deposited in the U.S. National Parasite Collection, Beltsville, Maryland 20705, USA (USNM Nos. 77970 and 77971).

We are indebted to Dr. David Cone who provided research facilities, helpful advice and generous hospitality at Saint Mary's University, Halifax, Nova Scotia, Canada during the preparation of this manuscript.

Journal of Wildlife Diseases, 21(4), 1985, pp. 463–466
© Wildlife Disease Association 1985

Cleft Palate in a Tule Elk Calf

Peter J. P. Gogan, Department of Forestry and Resource Management, University of California, Berkeley, California 94720, USA; and **David A. Jessup**, Wildlife Investigations Laboratory, California Department of Fish and Game, 1701 Nimbus Rd., Suite D, Rancho Cordova, California 95670, USA

Causes of mortality of fetuses or neonates of free-ranging cervids are frequently difficult to determine because of

the secretive nature of females near parturition and the rapid disappearance of carcasses of young in the wild. We report here a previously unrecorded congenital deformity, a case of cleft palate in a premature stillborn tule elk (*Cervus elaphus*

Received for publication 28 January 1985.

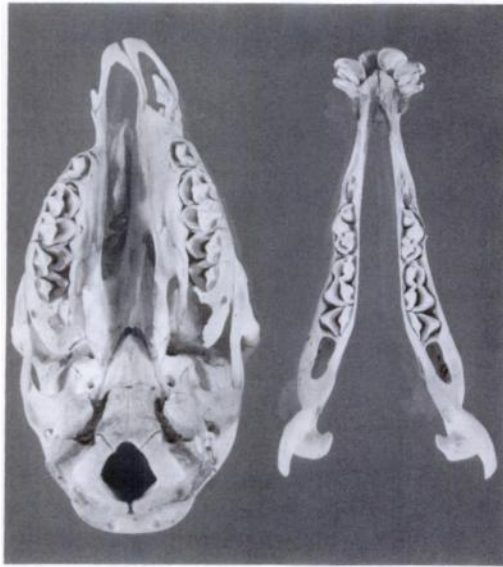


FIGURE 1. Photograph of skull of a premature fetus of a tule elk (*C. e. nannodes*) showing cleft palate. Photo by Jerry Morse.

nannodes). Three possible causes are identified and discussed.

Calving success of tule elk at Point Reyes National Seashore, Marin County, California, was monitored as part of a study of reintroduced tule elk. As the time of parturition approaches, pregnant elk become solitary and seek calving sites (McCullough, 1969, Univ. Calif. Publ. Zool. 88: 1-209). Such solitary females, many individually marked, were actively sought out to determine age-specific calving rates, perinatal loss, and to weigh and sex neonates. A 3-yr-old female born at Point Reyes in 1978 was sighted alone at 1810 hours on 8 May 1981, and observed until 2030 hours, at which time observations were discontinued. The female spent the entire period in sternal recumbency and frequently licked her perineum, and immediately behind her rear legs. The bedding site was examined at 0700 hours on 9 May. The female had left the area. The carcass of a calf, but no placenta, was found at the site. The carcass was immediately transported to the Wildlife Inves-

tigations Laboratory, California Department of Fish and Game, for necropsy. The skull was deposited at the Museum of Vertebrate Zoology, University of California, Berkeley (MVZ 169021).

The 9.5-kg carcass was that of a female, approximately 20 days premature as determined by size. Four live-born calves captured within a week of birth weighed an average of 15.3 kg (SE = 0.95). McCullough (1969, op. cit.) reported a mean weight of 13.0 kg for six tule elk calves. The umbilicus had been chewed off at the abdomen with no evidence of hemorrhage. The foot pads were unworn. There were no external lesions. The ductus arteriosus was patent. Fetal circulation to the umbilicus and hepatic portal vein were intact. The lungs were atelectatic and did not float in fluid. All other tissues and organs appeared normal. There were small reserves of subcutaneous, perirenal, mesenteric and cardiac fat.

Examination of the skull showed that the first and second incisors were symmetrical, but had not migrated into full-term position. The incisive bones deviated to the right as a result of a failure of the right maxillary and right palatine bones to form and fuse at the midline with those same bones on the left side (Fig. 1). As a result, the hard palate was absent on the right side of the skull, the nasal cavity being open to the oral cavity.

Congenital deformities in cattle occur in 1-3% of all births (Leipold, 1978, *In Effects of Poisonous Plants on Livestock*, Keeler et al. (eds.), Academic Press, New York, New York, pp. 429-440). Cleft palate is common in domestic stock (Runnells et al., 1965, *Principles of Veterinary Pathology*, Iowa State Univ. Press, Ames, Iowa, 958 pp.). The few documented accounts of cleft palate in free-ranging cervids are undoubtedly due in part to the nearly always fatal outcome of the affliction and the rapid disappearance of the remains of neonates under field condi-

tions. We found no published accounts of cleft palate in elk. Non-fatal brachygnathia inferior has been observed in tule elk at the Tule Elk State Reserve, Kern County, California. Tule elk at Point Reyes are descended directly from those at the state reserve.

A case of cleft palate in an adult male white-tailed deer (*Odocoileus virginianus*) has been reported (Dahlberg and Guettinger, 1956, The White-tailed Deer in Wisconsin, Technical Wildl. Bull. No. 14, Wisconsin Conservation Department, Madison, Wisconsin, 282 pp.). Similarly, cleft palate was among a number of congenital abnormalities reported in black-tailed deer (*O. hemionus columbianus*) in Tillamook County, Oregon; 31% of 16 does dropped or carried deformed fetuses over a 6-yr period (Hines, 1975, Black-tailed Deer Behavior and Population Dynamics in the Tillamook Burn, Oregon, Wildl. Res. Rep. No. 5, Oregon Wildlife Commission, Portland, Oregon, 31 pp.). Although 19% of 64 pregnant black-tailed deer from Camp Pendleton, San Diego County, California, carried abnormal fetuses, none of the deformities included cleft palate (Bischoff, 1958, Calif. Fish Game 44: 253–259).

The causes of this case of cleft palate remain unclear and the following discussion is of necessity speculative. Tule elk at Point Reyes have been affected by paratuberculosis (Jessup et al., 1981, J. Am. Vet. Med. Assoc. 179: 1252–1254) and copper deficiency (Gogan, unpubl. data) as well as a prior population bottleneck (McCullough, 1969, op. cit.). The teratogenic effects of certain range plants must also be considered (Keeler, 1978, *In Effects of Poisonous Plants on Livestock*, Keeler et al. (eds.), Academic Press, New York, New York, pp. 397–408).

No suggestion that paratuberculosis produces congenital birth defects could be found in published literature. Inbreeding in populations of a species which normally

outcross may lead to a reduction of viability of young (Templeton and Read, 1983, *In Genetics and Conservation*, Schonewald-Cox et al. (eds.), Benjamin/Cummings Publishing Co., Inc., Menlo Park, California, pp. 241–261). Arthrogryposis and cleft palate are inherited as autosomal recessive traits in some breeds of cattle (Shupe et al., 1967, J. Hered. 58: 311–313; Green et al., 1973, Am. J. Vet. Res. 34: 887–891; Leipold, 1978, op. cit.). Presumably, cleft palate in the tule elk calf could also be the result of a recessive trait. All tule elk are descendent from a remnant population of approximately 12 individuals in 1873 (McCullough, 1969, op. cit.). The affected calf's dam and the two largest male elk at Point Reyes during the 1980 rut were descended from a small tule elk herd at San Luis Island National Wildlife Refuge, Merced County, California. The affected calf was likely sired by one of these two males. Consequently, it may be even more inbred.

Copper deficiency in domestic stock has resulted in congenital ataxia and gross cavitation of the cerebral hemispheres in severe cases (Kavanagh et al., 1972, Vet. Rec. 90: 538–540). Complicated copper deficiency can cause incomplete calcification of cartilaginous plates (Allcroft and Parker, 1949, Br. J. Nutr. 3: 205–217). Neither of these lesions was evident in the tule elk fetus. Copper deficiency in tule elk at Point Reyes was most pronounced in the summer of 1979 and winter 1981, the latter being the gestation period associated with this abnormality (Gogan, unpubl. data). Also, antler deformity in the single adult male surviving copper deficiency was evident 2 yr later despite dietary supplementation.

The maternal ingestion of certain range plants containing alkaloid teratogens produces a syndrome known as "crooked calf disease" in domestic stock (Keeler et al., 1977, J. Range Manage. 30: 97–102; Keeler, 1978, op. cit.). Normally, less than 10%

of the stock in a herd are affected (Shupe et al., 1967, J. Am. Vet. Med. Assoc. 151: 191–197). The syndrome is characterized by arthrogryposis, scoliosis, torticollis, and cleft palate. Cleft palate may occur with other abnormalities, but occasionally it is the only detectable deformity (Shupe et al., 1967, op. cit.). The disease is the result of pregnant animals ingesting plants containing teratogenic alkaloids between the 40th and 70th days of pregnancy. One genus noted for its teratogenic alkaloids is *Lupinus* (Keeler et al., 1977, op. cit.; Keeler, 1978, op. cit.). The gestation period in tule elk is approximately 250 days with the rut in September and most calving in May or early June (McCullough, 1969, op. cit.). Thus, the period of insult in tule elk would be in October and November. Dietary records for September 1980, through May 1981 (Gogan, unpubl. data), showed that *Lupinus* spp. (mainly *L. arboreus*) constituted between 2 and 31% of the diet in bimonthly samples between early September and late November 1980, and less than 1% in bimonthly samples between early December 1980, and May 1981.

Thus, the diet of tule elk included a plant species with the potential to contain high levels of teratogenic alkaloids during a critical period of fetal development.

The causes of the cleft palate in this calf remain speculative. Circumstantial evidence suggests inbreeding or teratogenic plant alkaloids as possible causes. Closer inspection of fetuses from cervid species with varying levels of inbreeding and use of teratogenic plants may provide insight into the frequency and cause of this deformity.

We wish to thank Randy Wilson for assisting with the original observations and Bob Jones for preparing the specimen. Lori Merkle typed the manuscript. Research was supported by National Park Service Contract CX 800-9-0029, Project 3501-MS of the California Agricultural Experiment Station, Pittman Robertson Project W-52-R, "A Wildlife Investigations Laboratory," Tule Elk Investigations 775, and a Rob and Bessie Welder Wildlife Foundation fellowship to the senior author. Welder Wildlife Foundation Contribution 195.

Journal of Wildlife Diseases, 21(4), 1985, pp. 466–469
© Wildlife Disease Association 1985

Brain Cholinesterase Activity in Starlings and Japanese Quail Dosed with Methiocarb

Mahmoud E. Tharwat, Plant Protection Department, Faculty of Agriculture, Ain Shams University, Cairo, Egypt; and **Joseph G. Zinkl**,¹ Department of Clinical Pathology, School of Veterinary Medicine, University of California, Davis, California 95616, USA

Many species of birds damage agricultural crops. Grain (Besser et al., 1968, J. Wildl. Manage. 32: 179–180; Besser, 1973, Internat. Rice Comm. Newsletter (22: 9–

14; Shefte et al., 1981, Denver Wildlife Research Center, Bird Damage Res. Rep. No. 124, 7 pp.) and fruit (Guarino et al., 1974, J. Wildl. Manage. 38: 338–342; Dolbeer et al., 1974, Proc. 6th Bird Control Sem., pp. 28–40) can be severely damaged by birds producing significant mon-

Received for publication 30 October 1984.

¹ To whom reprint requests should be addressed.