

Infection in an Australian Wood Duck by a Spore-Forming Bacterium

Authors: S. C. Groom, R. J. Julian, and T. J. Beveridge

Source: Journal of Wildlife Diseases, 22(2) : 260-262

Published By: Wildlife Disease Association

URL: <https://doi.org/10.7589/0090-3558-22.2.260>

BioOne Complete (complete.BioOne.org) is a full-text database of 200 subscribed and open-access titles in the biological, ecological, and environmental sciences published by nonprofit societies, associations, museums, institutions, and presses.

Your use of this PDF, the BioOne Complete website, and all posted and associated content indicates your acceptance of BioOne's Terms of Use, available at www.bioone.org/terms-o-use.

Usage of BioOne Complete content is strictly limited to personal, educational, and non - commercial use. Commercial inquiries or rights and permissions requests should be directed to the individual publisher as copyright holder.

BioOne sees sustainable scholarly publishing as an inherently collaborative enterprise connecting authors, nonprofit publishers, academic institutions, research libraries, and research funders in the common goal of maximizing access to critical research.

Infection in an Australian Wood Duck by a Spore-Forming Bacterium

S. C. Groom and R. J. Julian, Department of Pathology, Ontario Veterinary College, University of Guelph, Guelph, Ontario N1G 2W1, Canada; and T. J. Beveridge, Department of Microbiology, College of Biological Science, University of Guelph, Guelph, Ontario N1G 2W1, Canada

On 14 October 1983 a 1.5-yr-old male Australian wood duck (*Chenonetta jubata*) was submitted to the Wildlife necropsy service at the University of Guelph. The duck had been raised at a local waterfowl park and was housed in an outdoor enclosure with access to a pond. The bird was found dead with no premonitory signs; other birds in the group were unaffected.

The bird was in fair body condition with adequate muscle mass and fat deposits and moderate dehydration. The lungs were congested, edematous with dorsal consolidation. Fibrin was present over the lung surface, pericardium and hepatic capsule. The liver, kidney, and spleen were swollen and firm.

Selected tissues were cultured aerobically and others were fixed in formalin and processed routinely for light microscopy. Sections were cut at 6- μ m thickness and stained with hematoxylin and eosin, periodic acid-Schiff (PAS), Giemsa and the Brown and Brenn Gram stain for bacteria. Selected pieces of formalin-fixed lung, brain and spleen were rinsed in phosphate buffered saline, pH 7.4, fixed in phosphate buffered 3.0% paraformaldehyde and 1.0% glutaraldehyde for 18 hr and post-fixed in phosphate buffered 1.0% osmium tetroxide for 1 hr, dehydrated in graded alcohol and embedded in plastic. Ultra-thin sections were cut and stained with uranyl acetate and lead citrate, and examined with an electron microscope.

Large numbers of *Plesiomonas shigell-*

loides were recovered from lung, liver and spleen by aerobic culture.

Histopathologic examination revealed significant lesions in all tissues examined: lung, liver, spleen, brain, muscle and heart. The lung was consolidated markedly and the air capillaries were occluded with fibrin, edema and mixed leukocytic inflammatory infiltrate consisting of heterophils, monocytes and lymphocytes. Many endothelial cells were distended with basophilic, round to oval structures (Figs. 1, 2) which varied from 10 to 60 μ m in diameter and contained individual microorganisms approximately 1 μ m in diameter. Hepatic architecture was intact, but distorted with random hepatocellular necrosis and diffuse mild mixed inflammatory cell infiltrate. Microorganisms similar to those present in the lung were associated frequently with necrotic cells in the liver. An infiltrate of heterophils was present in the spleen. Heart and skeletal myofibers were separated by focal accumulations of inflammatory cells. Clusters of organisms were present commonly in endothelial cells in the spleen, heart, skeletal muscle but infrequent in the brain. The microorganisms were Gram negative, PAS negative, and metachromatic with Giemsa stain.

Ultrastructural examination of the lesions revealed numerous rod-shaped bacteria free in the cytoplasm of endothelial cells. The organisms ranged in diameter from 0.6 to 0.8 μ m and length from 4.0 to 4.6 μ m and contained numerous round to oval 0.6-1.3- μ m subterminal endospores (Figs. 3, 4). The sporangium (mother bacteria) had a cell wall typical of Gram pos-

Received for publication 22 April 1985.

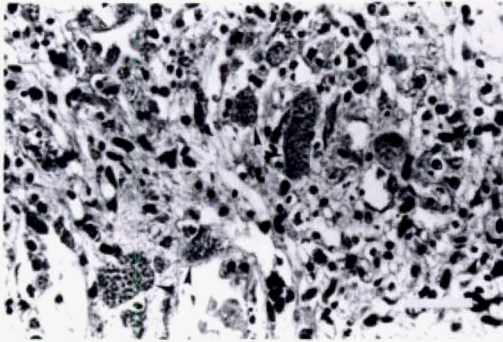


FIGURE 1. Mixed leukocytic infiltrate and oval to round pseudocyst-like structures (arrows), possibly within the cytoplasm of endothelial cells, in lung tissue from an Australian wood duck. H&E, bar = 50 μm .

itive organisms (Beveridge, T. J., 1981, *Int. Rev. Cytol.* 72: 229–317) and the endospore had a prominent spore coat and cortex (Fig. 4) (Warth, 1978, *Adv. Microbiol. Physiol.* 17: 1–45). Among the medically important pathogenic bacteria only those of the genera *Bacillus* and *Clostridium* form spores (Cowan, 1974, *Manual for the Identification of Medical Bacteria*, Cambridge University Press, Cambridge, England, pp. 67–71). Other genera of Gram positive and negative bacteria produce spores, but the pathogenicity of these organisms is frequently unknown (Gerhart et al., 1975, *Spores VI*, *Am. Soc. Microbiol.*, Washington, D.C., 128 pp.). Of the

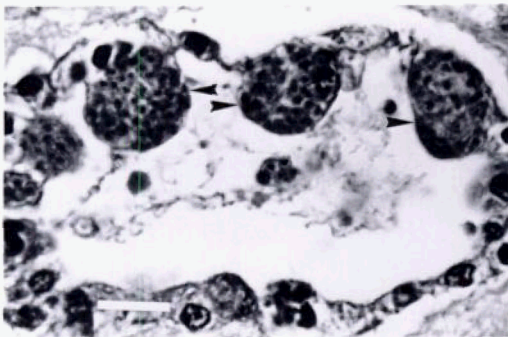


FIGURE 2. Intracytoplasmic structures (arrows) containing dense endospores in endothelial cells of vessels in lung of an Australian wood duck. H&E, bar = 20 μm .

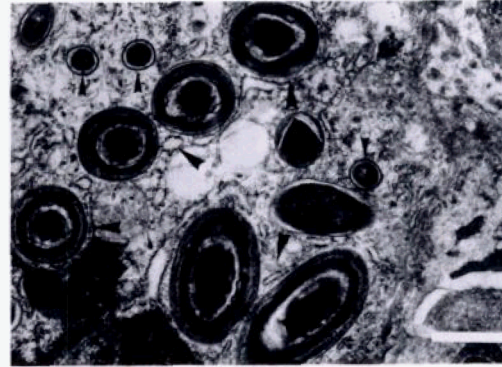


FIGURE 3. Electron micrograph of oval to round intracytoplasmic bacterial endospores (large arrows) and bacteria without endospores (small arrows) with peripheral filaments in necrotic cell in lung of an Australian wood duck. TEM, bar = 1.0 μm .

endospore-forming bacteria, those found in the tissues of this duck most closely resemble the genera *Clostridium* or *Bacillus*. It appeared that most of the organisms were located in degenerating endothelial cells.

The tentative diagnosis following bacteriological and light microscopic histopathological examination was infection by *Haemoproteus* sp. The histological appearance of the inflammatory lesions containing the organisms was similar to previously described natural and experi-

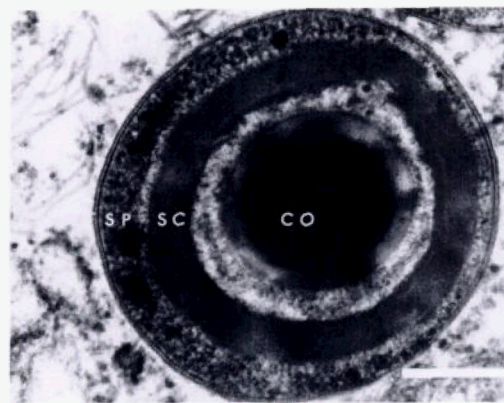


FIGURE 4. Electron micrograph of endospore showing core (CO), spore coat (SC), sporangium (SP) and filaments in cytoplasm of a necrotic cell in lung of an Australian wood duck. TEM, bar = 0.25 μm .

mental disease attributed to *Haemoproteus* (Julian et al., 1980, J. Wildl. Dis. 16: 39-44), but subsequently shown to be caused by a *Bacillus* species (Julian et al., 1985, J. Wildl. Dis. 21: 335-337). The bacterium in the present case differed from the *Bacillus* sp. previously described. This organism was larger and contained numerous prominent endospores. Most notably the cell wall had a well defined surface array rather than a thick capsule. The wall was not stained with PAS in contrast to the positive reaction of the *Bacillus*. It is unusual that this organism stained Gram negative in tissue sections, however, the tissues were necrotic and the structure stained were spores rather than the intact bacterium. Swollen sporangia, terminal to subterminal endospores and walls with surface arrays are typical of clostridia. The advanced degree of tissue necrosis (Fig. 2) could produce microaerophilic to anaerobic conditions which would optimize clostridial growth. Taken together these observations suggest that the spore-former may belong to the

genus *Clostridium*, but we must emphasize that an unequivocal identification has been impossible. Clinical disease associated with infection of *Bacillus* sp. and *Clostridium* sp. is usually not considered to be highly contagious, commonly affecting individual animals. This animal was not debilitated suggesting an acute primary infection with this organism. Frozen tissues were not available to attempt spore germination for definitive identification of the bacteria. *Plesiomonas shigelloides* is a Gram negative bacterium which is infrequently isolated from a variety of human and animal submissions (Carter, 1984, Diagnostic Procedures in Veterinary Bacteriology and Mycology, Thomas Books, Springfield, Illinois, pp. 77-78). It occasionally has clinical significance, but it is unlikely that it was significant in this case.

The authors are grateful to C. Skene for technical assistance with electron microscopy. This work was supported in part by a grant from the Ontario Ministry of Natural Resources.

Journal of Wildlife Diseases, 22(2), 1986, pp. 262-264
© Wildlife Disease Association 1986

Isolation of *Salmonella* spp. from a Colony of Wading Birds

Carl E. Kirkpatrick, Department of Pathobiology, School of Veterinary Medicine, University of Pennsylvania, 3800 Spruce Street, Philadelphia, Pennsylvania 19104, USA

Among birds that inhabit marine environments, gulls (*Larus* spp.) are the most widely recognized hosts of *Salmonella* spp. (e.g., Nielsen, 1960, Nord. Veterinaermed. 12: 417-424; Müller, 1965, Nature 207: 1315; Snoeyenbos et al., 1967, Avian Dis. 11: 642-646; Wuthe, 1973, Berl. Münch. Tierärztl. Wsch. 86: 255-256; Kapperud and Rosef, 1983, Appl.

Environ. Microbiol. 45: 375-380; Fenlon, 1983, J. Hyg. 91: 47-52; Fricker, 1984, J. Appl. Bacteriol. 56: 499-502). Some other species of marine birds have been found to harbor *Salmonella* spp., also (Steiniger and Hahn, 1953, Acta Pathol. Microbiol. Scand. 23: 401-408; White and Forrester, 1979, J. Wildl. Dis. 15: 235-237; Ferreira Garcia and Schönhofen, 1982, Arq. Biol. Tecnol. (Curitiba) 25: 237-242). Locke et al. (1974, J. Wildl. Dis. 10: 143-145) re-

Received for publication 23 August 1985.