



EIMERIA FRATERCULAE SP. N. IN THE KIDNEYS OF ATLANTIC PUFFINS (FRATERCULA ARCTICA) FROM NEWFOUNDLAND, CANADA: SPECIES DESCRIPTION AND LESIONS

Authors: Leighton, Frederick A., and Gajadhar, Alvin A.

Source: Journal of Wildlife Diseases, 22(4) : 520-526

Published By: Wildlife Disease Association

URL: <https://doi.org/10.7589/0090-3558-22.4.520>

BioOne Complete (complete.BioOne.org) is a full-text database of 200 subscribed and open-access titles in the biological, ecological, and environmental sciences published by nonprofit societies, associations, museums, institutions, and presses.

Your use of this PDF, the BioOne Complete website, and all posted and associated content indicates your acceptance of BioOne's Terms of Use, available at www.bioone.org/terms-of-use.

Usage of BioOne Complete content is strictly limited to personal, educational, and non - commercial use. Commercial inquiries or rights and permissions requests should be directed to the individual publisher as copyright holder.

BioOne sees sustainable scholarly publishing as an inherently collaborative enterprise connecting authors, nonprofit publishers, academic institutions, research libraries, and research funders in the common goal of maximizing access to critical research.

EIMERIA FRATERCULAE SP. N. IN THE KIDNEYS OF ATLANTIC PUFFINS (*FRATERCULA ARCTICA*) FROM NEWFOUNDLAND, CANADA: SPECIES DESCRIPTION AND LESIONS

Frederick A. Leighton¹ and Alvin A. Gajadhar²

ABSTRACT: Renal coccidiosis is reported for the first time in an auk (Alcidae). Infection was detected in seven of 50 nestling Atlantic puffins (*Fratercula arctica*) and a new species of coccidia, *Eimeria fraterculae* sp. n., is described. The structure and sporulation of oocysts are characterized. Meronts, gamonts, and developing oocysts were present in collecting duct epithelium of medullary cones. The predominant host response was hypertrophy of infected cells, tubule dilation, and a mild localized peritubular infiltration with mononuclear inflammatory cells.

INTRODUCTION

Coccidia have been found in the kidneys of several species of birds representing a wide range of orders and families (Munday et al., 1971; Wobeser, 1974; Montgomery et al., 1978; Thompson and Wright, 1978; Obendorf and McColl, 1980; Gajadhar et al., 1983a; Gajadhar et al., 1983b). To our knowledge, renal coccidia have not been described from any member of the family Alcidae (auks), the predominant family of marine birds in the Northern Hemisphere. In this paper we describe renal coccidiosis in a North Atlantic alcid, the Atlantic puffin, and a new species of the genus *Eimeria*.

MATERIALS AND METHODS

Specimens for this study were from pre fledgling young puffins collected as part of a larger study of the toxic effects of crude oil on marine birds (Leighton et al., 1983). All birds were from Great Island, 50 km south of St. John's, Newfoundland, and were collected in July of 1968,

1982 and 1984. The age of the birds was not known. All were feathering and were probably ≤ 7.5 wk old, the approximate mean age of fledging for puffins on Great Island (Nettleship, 1972). In 1982, 22 birds were maintained in captivity in artificial burrows for 15 days prior to necropsy (Leighton et al., 1984). In 1984, 27 birds were used in oil intoxication studies while they remained in their native burrows, and were dissected on the day they were removed from the field. The birds were killed by decapitation. Renal tissue from all birds was fixed in 10% neutral-buffered formalin. In 1984, one kidney from each bird was placed in 2.5% aqueous potassium dichromate solution and held at 4 C until processed for oocyst isolation 2 mo later. One additional bird included in this study was a fledgling that had been collected and fixed in formalin in 1968.

A cross-section of the caudal division of each formalin-fixed kidney collected in 1968 and 1982, and from each 1984 specimen identified as positive for oocysts by flotation, was embedded in paraffin, sectioned, stained with hematoxylin and eosin, and viewed with a light microscope. Potassium dichromate-preserved kidneys were homogenized and processed for isolation of oocysts by flotation as previously described (Gajadhar et al., 1983a). Oocysts were suspended in a thin layer of 2.5% aqueous potassium dichromate solution in a petri dish at 20 ± 2 C for 21 days and examined daily for sporulation. The suspension of oocysts was then kept at 4 C for 5 days and was again examined. One hundred oocysts were measured using an eyepiece micrometer and 40 sporocysts were measured using a drawing tube and millimeter scale. Measurements were expressed as mean \pm one standard deviation (range).

Received for publication 8 July 1985.

¹ Department of Veterinary Pathology, Western College of Veterinary Medicine, University of Saskatchewan, Saskatoon, Saskatchewan S7N 0W0, Canada.

² Department of Veterinary Microbiology, Western College of Veterinary Medicine, University of Saskatchewan, Saskatoon, Saskatchewan S7N 0W0, Canada.

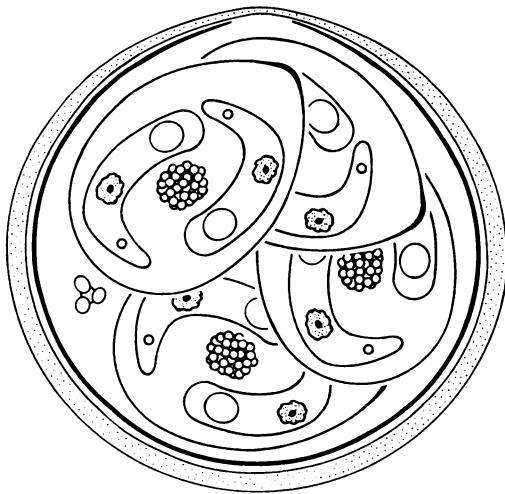

FIGURE 1. Line drawing of a sporulated oocyst of *Eimeria fraterculae* sp. n. from the kidney of an Atlantic puffin.

RESULTS

Prevalence

Stages of renal coccidia were detected histologically in two of 22 puffins collected in 1982. Both were females and were control birds that had received no oil. Oocysts were isolated from four of 27 kidneys collected in 1984. These were from two males, one female, and one of undetermined sex. All had received oral crude oil (0.3 or 1.0 ml per day) for the 5 days immediately preceding necropsy. Coccidia were detected histologically in the kidneys of the female puffin collected in 1968.

Description of parasite: *Eimeria fraterculae* sp. n.

Type host: *Fratercula arctica*.

Type locality: Great Island, Newfoundland, Canada.

Location in host: Renal collecting tubules.

Etymology: The specific name is de-

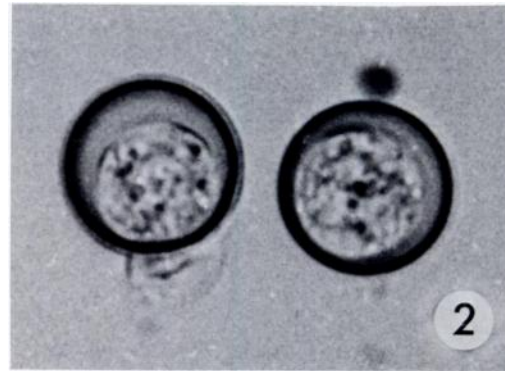


FIGURE 2. Unstained wet preparation of oocysts of *E. fraterculae* sp. n. from Atlantic puffins. Unsporulated oocysts with contracted sporonts, $\times 1,250$.

rived from the generic name of the type host.

Description: Characteristic of the genus *Eimeria*: sporulated oocyst (Fig. 1) has four sporocysts, each sporocyst containing two sporozoites. Unsporulated and sporulated oocysts (Figs. 2, 3) are subspherical and have a wall approximately $1.5 \mu\text{m}$ thick which consists of a translucent, thick, greenish outer layer and a thin, dense inner layer. Oocysts measure 18.6 ± 0.5 (17.6 – 19.6) μm in diameter along the axis through the micropyle and 19.2 ± 0.5 (17.6 – 20.0) μm in diameter elsewhere. An inconspicuous micropyle is present but at

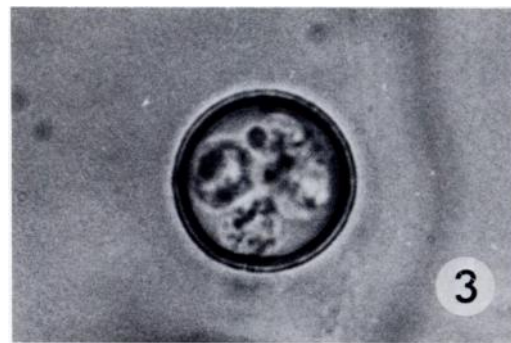

FIGURE 3. Unstained wet preparation of oocysts of *E. fraterculae* sp. n. from Atlantic puffins. Four sporocysts enclosed by an oocyst wall composed of a dense inner layer and a translucent outer layer, $\times 1,250$.

most orientations oocysts appear spherical and to lack a micropyle. An oocyst residuum is present as a small cluster of granules in sporulated oocysts. Sporocysts are oval to ellipsoidal, measure 9.8 ± 0.5 (9.0–10.8) \times 7.1 ± 0.6 (6.2–8.0) μm , have a Stieda body and contain a prominent sporocyst residuum. Sporozoites are arranged in a curved position within sporocysts and contain two refractile globules and a nucleus.

Sporulation

After 21 days at 20 C no sporulated oocysts were observed, but there were contracted central sporonts. Approximately 5% of oocysts were sporulated completely after a further 5 days at 4 C.

Endogenous stages

All developmental stages of *E. fraterculae* sp. n. were found in the collecting duct epithelium of renal medullary cones (Figs. 4, 5). The parasites consistently occupied the apical portion of the host cell, relative to the nucleus. Usually, all cells of affected ducts were parasitized (Figs. 5–8). Meronts and gamonts occupied most of the epithelium. Mature meronts contained more than 20 banana-shaped merozoites (Fig. 6). Occasionally individual merozoites appeared free in the lumen. Various stages of immature and mature micro- and macrogamonts were present in the same duct (Fig. 7). Single epithelial cells appeared parasitized by several gamonts. Macrogamonts were more or less spherical, and contained a prominent central nucleus and many small eosinophilic wall-forming bodies. Microgamonts were oval, were generally larger than macrogamonts and contained small nuclei. Mature microgamonts were irregular in shape and had peripheral layers of dense, basophilic microgametes.

Developing oocysts fully occupied the cytoplasm of host cells and characteristically contained several large eosinophilic

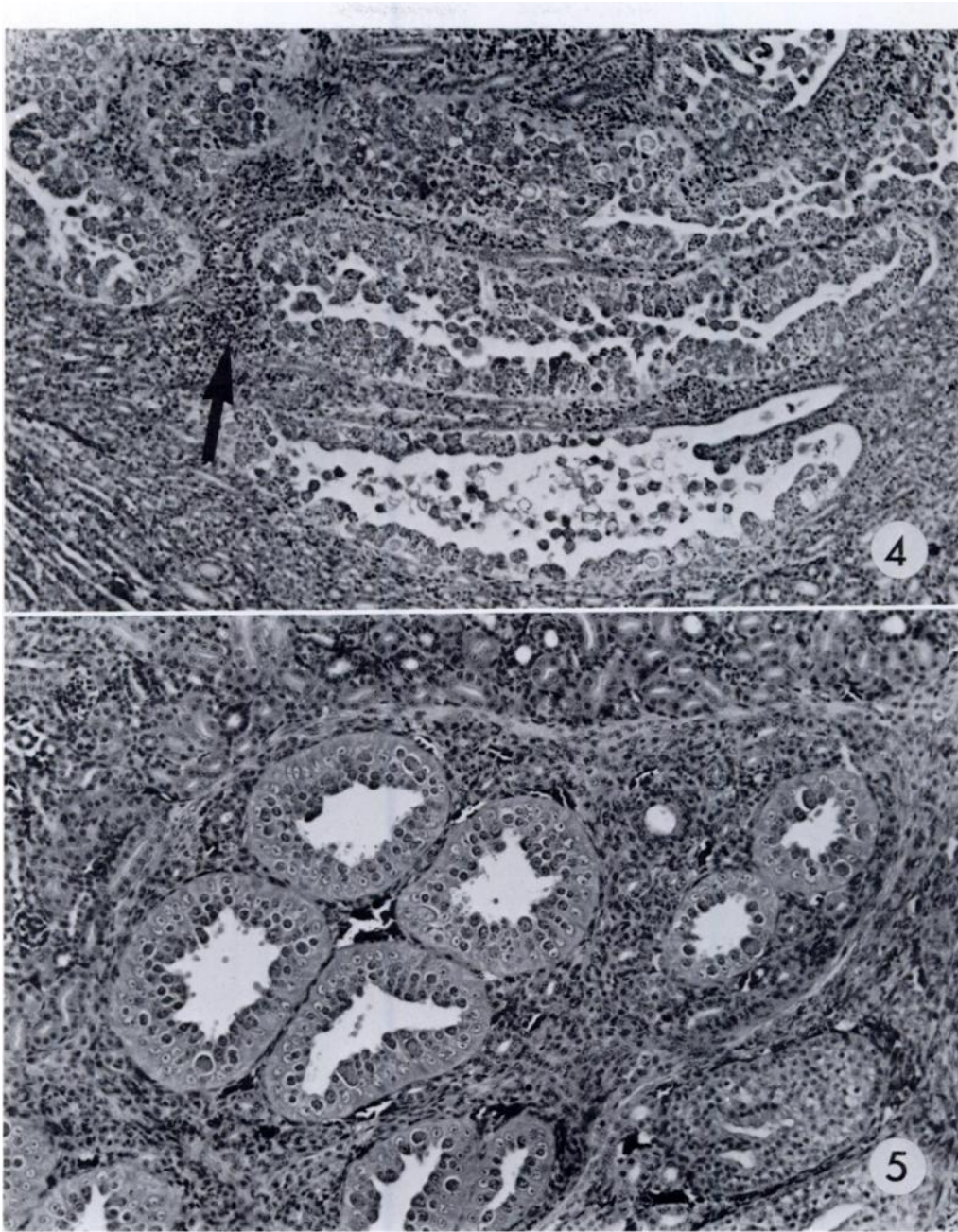
granules of varying density (Fig. 8). Oocysts with collapsed walls were present in the lumina of collecting ducts, and a few were seen within host cells.

Pathology

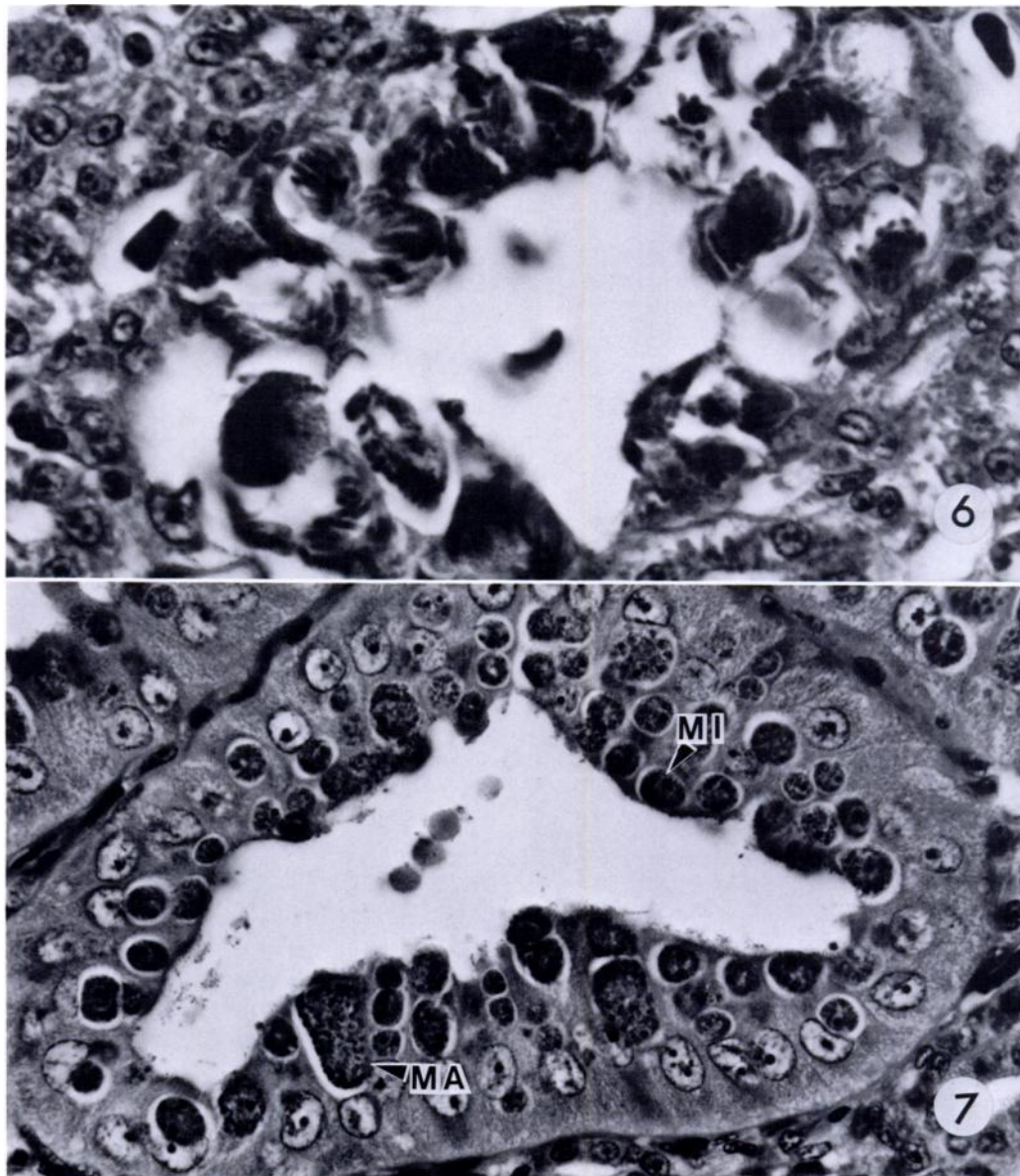
Small pale foci were noted grossly on the ventral surfaces and on cut surfaces of the two infected kidneys collected in 1982. These foci corresponded to areas of particularly intense infection with coccidia. Hypertrophy of infected epithelial cells was present in association with merogony (Fig. 6) and was pronounced in association with gametogony (Fig. 7) and oocyst formation (Fig. 8). The tubule epithelium changed from its normal morphology as a monolayer of cuboidal cells to a layer of tall, irregularly shaped cells with their apices massively distended by tiers of developing parasites (Figs. 7, 8). This was accompanied by dilation of the tubule to several times its normal diameter and, in some foci, by development of papillary luminal projections of infected epithelium (Fig. 4). In some areas, the massive epithelial hypertrophy resulted in apparent occlusion of the collecting duct lumen. There was a mild to moderate infiltration of the immediate peritubular interstitium with mononuclear inflammatory cells and a few granulocytes. The epithelium of collecting ducts from which oocytes were being shed into the lumen consisted of a monolayer of thin attenuated cells or low cuboidal cells. Ulceration of the epithelium was evident in a few affected tubules.

DISCUSSION

This study describes a new species of renal coccidia of the genus *Eimeria* and renal coccidiosis in an additional family of birds: the Alcidae. Alcids are all marine birds and it is of interest that most reports of renal coccidia in birds are from hosts that occupy marine or fresh water habitats. It is uncertain to what extent renal



FIGURES 4, 5. Histological sections of kidney from Atlantic puffins infected with *E. fraterculae* sp. n., H&E stain. 4. Longitudinal section of heavily infected collecting ducts in a medullary cone. Collapsed oocysts are present within the dilated lumina. Mild mononuclear inflammatory cell infiltration (arrow), $\times 120$. 5. Cross-section of medullary cone with developmental stages in collecting duct epithelium, $\times 160$.



FIGURES 6, 7. Histological sections of kidney from Atlantic puffins infected with *E. fraterculae* sp. n., H&E stain. 6. Mature meronts in collecting duct cells contain banana-shaped merozoites, $\times 1,100$. 7. Immature and mature macrogamonts (MA) and microgamonts (MI) in the apices of epithelial cells. Host cells are hypertrophied and appear to contain multiple gamonts, $\times 560$.

coccidia of the genus *Eimeria* are host-specific. Some contend that there is no cross-infection among hosts of different genera (Pellerdy, 1974). Cross-infection among host species within the genus *An-*

ser has been documented (Gajadhar et al., 1982). The geographic range of the type host of *E. fraterculae* sp. n. does not overlap that of other species of the genus *Fratercula*, although it overlaps extensively

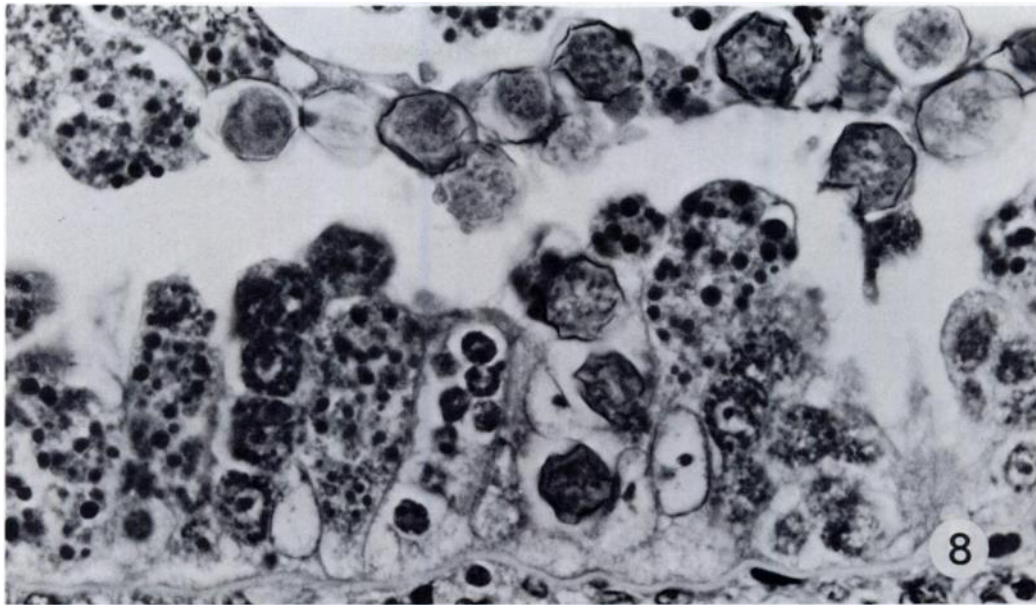


FIGURE 8. Histological section of kidney from an Atlantic puffin infected with *E. fraterculae* sp. n., H&E stain. Oocysts developing within massively enlarged host cells and free in the dilated collecting duct lumen. Large eosinophilic (black) granules evident in developing oocysts, $\times 775$.

that of other alcids, including the genera *Uria*, *Alca*, *Cepphus*, and *Alle*. The host and geographic range of *E. fraterculae* sp. n. remains to be defined.

The prevalence of renal coccidiosis in Atlantic puffins may be underestimated. Histological techniques sample only a small fraction of renal tissue, and flotation techniques detect only oocysts. Thus, it is likely that the prevalence of infection is higher than that reported here. However, the prevalence of infection was low compared with that detected with similar techniques in several species of waterfowl (Gajadhar et al., 1983a). The puffins in this study were from a dense nesting colony estimated in 1973 to contain 148,000 pairs (Brown et al., 1975). However, puffins are hatched and reared alone in individual burrows and are in contact only with their own parents until they fledge. Thus, there is limited opportunity for transmission of the parasite among individuals in the colony and nestlings are

probably infected by their own parents or with oocysts derived from residents of the burrow in previous years.

Eimeria fraterculae sp. n. is an unusual coccidium in several respects. Most oocysts appeared spherical, but by careful manipulation they were shown to be subspherical, with the shortest diameter along the axis of the inconspicuous micropyle. They also have a very thick oocyst wall which has a greenish hue in unstained preparations. Sporulation appeared to require a period of warmth (20 C) followed by a cold period (4 C). There are no reports of other coccidia with similar sporulation requirements. Eggs of the parasitic nematodes *Nematodirus battus* and *N. filicollis* of ruminants require an alternating sequence of warm and cold periods before they will hatch, and this requirement appears to ensure that infective stages appear in the spring when conditions for infection are optimal (Dunn, 1978). The apparently similar need for alternating

periods of warmth and cold in the sporulation of *E. fraterculae* may help entrain the organism to the strictly seasonal breeding cycle of its type host. The temperature requirements for sporulation of this coccidium need confirmation and further study, however; the long period of storage before processing and sporulation in the present study may have altered normal requirements.

The lesion associated with *E. fraterculae* sp. n. infection was predominantly a hypertrophic reaction of infected epithelium and a local mononuclear cell response. Similar lesions are seen in association with *E. stiedae* and *E. hiepei* infections in the livers of rabbits and mink (Grafner et al., 1967; Pellerdy, 1974). Inflammation in response to the infection was generally mild. Tubule integrity appeared to be maintained during infection, and it seems likely that infection is usually followed by restoration of function in affected nephrons.

It is unlikely that renal coccidiosis caused significant renal dysfunction in any of the birds found to be infected in this study. Relatively small amounts of tissue were affected in each case. However, the organism caused severe focal lesions, and thus has the potential to cause significant renal disease. Renal coccidiosis is recognized as a serious and potentially lethal disease in some species of waterfowl (Wobeser, 1974; Gajadhar et al., 1983b).

ACKNOWLEDGMENTS

Support for this study was from the Canadian Wildlife Service and the Departments of Veterinary Pathology and Veterinary Microbiology, Western College of Veterinary Medicine, University of Saskatchewan. Particular thanks are extended to R. Butler, M. Georgi, A. Harfenist, D. Jeffrey, C. Neitzel, D. Peakall, and L. Pura, to G. Cody who prepared the line drawing and to D. Nettleship who provided the 1968 specimen. Birds were collected under permit from the Canadian Wildlife Service and with permission from the Government of Newfoundland and Labrador.

LITERATURE CITED

- BROWN, R. G. B., D. N. NETTLESHIP, P. GERMAIN, C. E. TULL, AND T. DAVIS. 1975. Atlas of Eastern Canadian Seabirds, 1st Ed. Canadian Wildlife Service, Ottawa, Ontario, 220 pp.
- DUNN, A. M. 1978. Veterinary Helminthology, 2nd Ed. William Heinemann Medical Books, London, England, 323 pp.
- GAJADHAR, A. A., R. J. CAWTHORN, AND D. J. RAINNIE. 1982. Experimental studies on the life cycle of a renal coccidium of lesser snow geese (*Anser c. caerulescens*). Can. J. Zool. 60: 2085-2092.
- , G. A. WOBESER, AND P. H. G. STOCKDALE. 1983a. Prevalence of renal coccidia in wild waterfowl in Saskatchewan. Can. J. Zool. 61: 2631-2633.
- , G. WOBESER, AND P. H. G. STOCKDALE. 1983b. Coccidia of domestic and wild waterfowl (Anseriformes). Can. J. Zool. 61: 1-24.
- GRAFNER, G., H. D. GRAUBMANN, AND W. DOBBRINER. 1967. Hepatic coccidiosis in mink (*Lutreola vison* Schreb) caused by a newly identified species of coccidia, *Eimeria hiepei* n. sp. Monatsh. Veterinaarmed. 22: 696-700.
- LEIGHTON, F. A., D. B. PEAKALL, AND R. G. BUTLER. 1983. Heinz-body hemolytic anemia from the ingestion of crude oil: A primary toxic effect in marine birds. Science 220: 871-873.
- , ———, AND ———. 1984. A simple method for maintaining nestling puffins in captivity. J. Wildl. Manage. 48: 1033-1035.
- MONTGOMERY, R. D., M. N. NOVILLA, AND R. B. SHILLINGER. 1978. Renal coccidiosis caused by *Eimeria gaviae* n. sp. in a common loon (*Gavia immer*). Avian Dis. 22: 809-814.
- MUNDAY, B. L., R. W. MASON, R. J. H. WELLS, AND J. H. ARUNDEL. 1971. Further studies on "limey-disease" of Tasmanian mutton birds (*Puffinus tenuirostris*). J. Wildl. Dis. 7: 126-129.
- NETTLESHIP, D. N. 1972. Breeding success of the common puffin (*Fratercula arctica* L.) on different habitats at Great Island, Newfoundland. Ecol. Monogr. 42: 239-268.
- OBENDORF, D. L., AND K. MCCOLL. 1980. Mortality in little penguins (*Eudyptula minor*) along the coast of Victoria, Australia. J. Wildl. Dis. 16: 251-259.
- PELLERDY, L. P. 1974. Coccidia and Coccidiosis, 2nd Ed. Verlag Paul Parey, Berlin, West Germany, 959 pp.
- THOMPSON, E. J., AND I. G. A. WRIGHT. 1978. Coccidiosis in Kiwis. N.Z. Vet. J. 28: 167.
- WOBESER, G. 1974. Renal coccidiosis in mallard and pintail ducks. J. Wildl. Dis. 10: 249-255.