

## **Sporulated Coccidian Oocysts Resembling *Goussia* Labbe, 1896 in the Viscera of Nile Crocodiles**

Authors: Gardiner, C. H., Imes, George D., Jacobson, Elliott R., and Foggin, Chris M.

Source: *Journal of Wildlife Diseases*, 22(4) : 575-577

Published By: Wildlife Disease Association

URL: <https://doi.org/10.7589/0090-3558-22.4.575>

---

BioOne Complete ([complete.BioOne.org](https://complete.BioOne.org)) is a full-text database of 200 subscribed and open-access titles in the biological, ecological, and environmental sciences published by nonprofit societies, associations, museums, institutions, and presses.

Your use of this PDF, the BioOne Complete website, and all posted and associated content indicates your acceptance of BioOne's Terms of Use, available at [www.bioone.org/terms-of-use](https://www.bioone.org/terms-of-use).

Usage of BioOne Complete content is strictly limited to personal, educational, and non - commercial use. Commercial inquiries or rights and permissions requests should be directed to the individual publisher as copyright holder.

---

BioOne sees sustainable scholarly publishing as an inherently collaborative enterprise connecting authors, nonprofit publishers, academic institutions, research libraries, and research funders in the common goal of maximizing access to critical research.

with immunodeficiency. In the case reported here, the immunocompetence of the sloth was not known. The microbiologic findings of *Enterobacter* spp. and *Acinetobacter anitratus* were considered

to be findings of opportunistic invading organisms. There was no gross or microscopic evidence of other significant concurrent disease.

*Journal of Wildlife Diseases*, 22(4), 1986, pp. 575-577

### **Sporulated Coccidian Oocysts Resembling *Goussia* Labbe, 1896 in the Viscera of Nile Crocodiles**

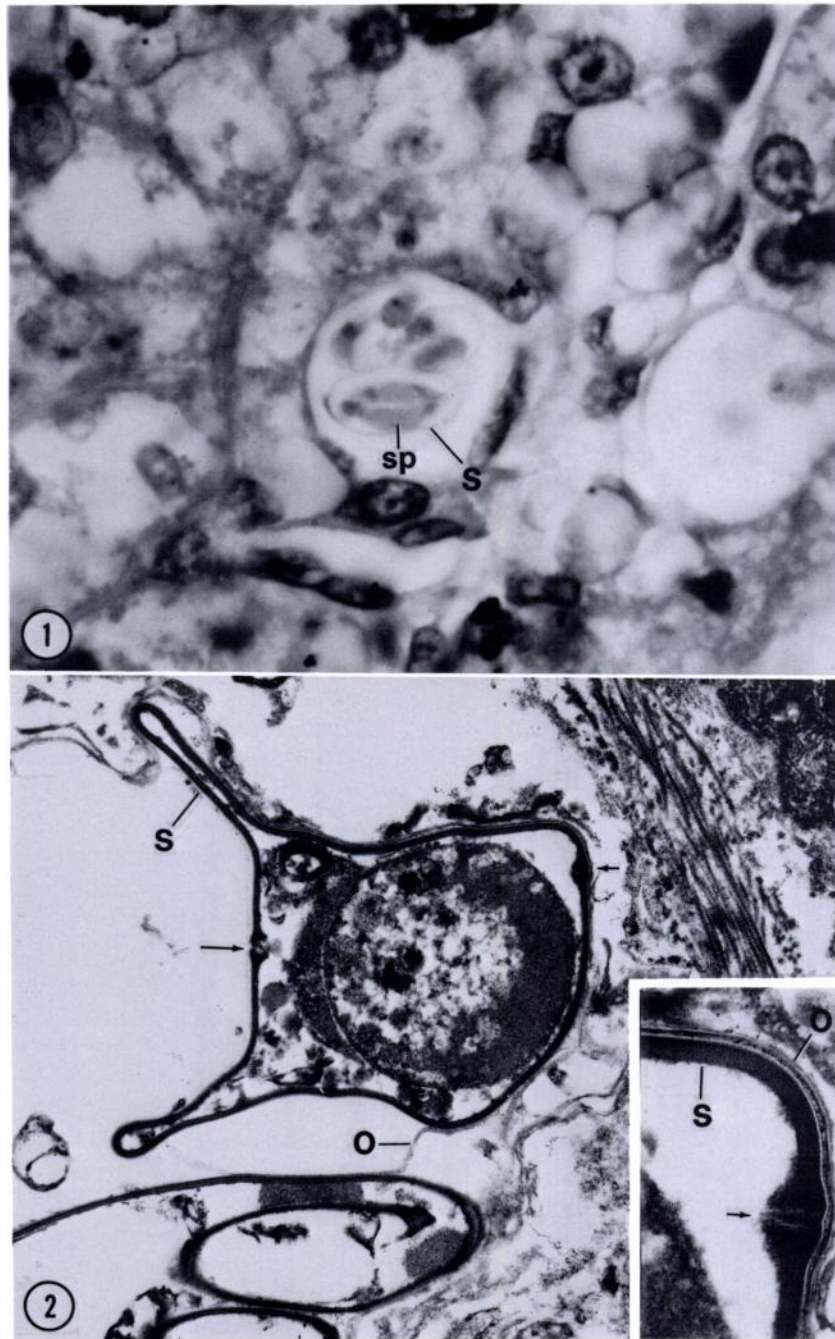
**C. H. Gardiner**, Department of Parasitology, Naval Medical Research Institute Detachment, Lima, Peru, APO Miami, Florida 34031, USA; **George D. Imes, Jr.**, Department of Veterinary Pathology, Armed Forces Institute of Pathology, Washington, D.C. 20306, USA; **Elliott R. Jacobson**, Department of Special Clinical Sciences, College of Veterinary Medicine, University of Florida, Gainesville, Florida 32610, USA; and **Chris M. Foggin**, Veterinary Research Laboratory, P.O. Box 8101 Causeway, Zimbabwe

Three dead adult (3-4 yr of age) Nile crocodiles (*Crocodylus niloticus* Laurenti, 1768) from a crocodile farm in Zimbabwe were submitted for evaluation. They had been dead 1-2 hr prior to necropsy. No gross lesions were seen at necropsy. Available for histology were pieces of liver, spleen and lung fixed in neutral-buffered 10% formalin. Tissues were processed routinely (i.e., dehydrated in ethanol series, embedded in paraffin, sectioned at 5  $\mu\text{m}$ ). For electron microscopy formalin-fixed tissues were post-fixed in Dalton's osmium-dichromate solution (Dalton, 1955, Anat. Rec. 121: 128), embedded in Epon, and cut at 8 nm. Sections were stained with lead citrate and uranyl acetate.

Histologically the red pulp of the spleen was infiltrated by leucocytes, primarily lymphocytes, but the white pulp was still easily recognizable. There were many sporulated oocysts of a coccidian in the red pulp area and impinging on and within the periphery of the lymphoid sheaths. A mild hemosiderosis was present in the red pulp. Numerous oocysts were found within the interstitium of the lung. It was

difficult to determine the exact location of the oocysts. It was determined that they were within macrophages or endothelial cells. Some oocysts were extracellular. Diffuse hydropic changes were present in hepatocytes. Oocysts were numerous in sinusoids and often were found in cells with flattened nuclei. These parasites were probably in Kupfer cells, but may have been in circulating macrophages. In general there was no inflammatory response to the parasites in any organ.

Oocysts were found singly or in clusters. The only stage of parasite found was sporulating or sporulated oocysts (Fig. 1). The oocyst wall was thin (less than 0.5  $\mu\text{m}$ ) and was folded or collapsed during sectioning and oocysts were spherical and approximately 20  $\mu\text{m}$  in diameter. Four sporocysts were present within each oocyst. These were ovoidal and measured approximately 15  $\times$  6  $\mu\text{m}$  when mature. Each sporocyst contained two elongate sporozoites with their sides abutting one another. Sporozoites measured 12  $\times$  2.5  $\mu\text{m}$  and each contained a small basophilic nucleus and large eosinophilic globules (when stained with hematoxylin and eo-



FIGURES 1, 2. Oocysts of *Goussia*-like organism in liver of Nile crocodile. 1. Histological section of oocyst. Note two intact sporocysts (s), each containing two sporozoites (sp). Hematoxylin and eosin,  $\times 1,500$  (AFIP MIS #84-9574). 2. Transmission electron microscopy (TEM) of oocyst. Two sporocysts (s) are seen, the lower of the two has ruptured at suture. Sporocysts are contained within a thin oocyst wall (o) and each has two sutures (arrows). TEM,  $\times 15,650$  (AFIP MIS #84-12094-5). Inset. Higher magnification of intact sporocyst suture. TEM,  $\times 48,700$  (AFIP MIS #84-12094-4).

sin). Sporozoites were formed by globular bodies in sporocysts. Mature sporozoites were acid fast stained with a Ziehl-Neelsen acid fast procedure (Luna, 1960, Manual of Histologic Staining Methods of the Armed Forces Institute of Pathology, McGraw-Hill Book Company, New York, p. 220); developing sporozoites were not acid fast. Representative sections are deposited in the U.S. National Parasite Collection, Beltsville, Maryland 20705, USA (Accession No. 79046).

On transmission electron microscopy (Fig. 2) the oocyst wall fractured in numerous places. The sporocyst wall was bivalved (i.e., contained two sutures). When collapsed the sporocyst wall coiled upon itself (Fig. 2, lower sporocyst). Sporulating or mature sporozoites were present within most sporocysts. Nuclear material in the sporozoite had no nuclear membrane (Fig. 2).

In 1984 a new family, Calyptosporidae, was established for coccidians that possess sporulated oocysts within tissues of their poikilothermic hosts, have sporocysts which lack Stieda bodies, and require invertebrate intermediate hosts (Overstreet et al., 1984, J. Protozool. 31: 332-339). Two genera are presently in this family,

i.e., *Calyptospora* and *Goussia*. Both genera possess oocysts with four sporocysts, but differ in the fact that (1) sporocysts of *Calyptospora* are covered with a thin veil supported by sporopodia and those of *Goussia* either lack a veil or if they have a veil lack supporting sporopodia and (2) sporocysts of *Calyptospora* have a membrane-covered apical opening with one associated suture while those of *Goussia* have no apical opening and have two sutures. The organism in this case report has features of *Goussia*. The lack of a veil places it in the subgenus *Goussia*. Although study of the life cycle of this organism is needed before exact taxonomic status can be determined, this preliminary report establishes the fact that *Goussia*-like organisms can be found in non-picine definitive hosts. Sporulated coccidian oocysts have been noted in crocodiles previously (Griner, 1983, Pathology of Zoo Animals, Zoological Society of San Diego, San Diego, California, p. 88), but no morphologic features were given. In addition oocysts similar to the ones reported in this case have been seen by one of us (CG) in internal organs of gavials (*Gavialis gangeticus* Gmelin, 1789).

*Journal of Wildlife Diseases*, 22(4), 1986, pp. 577-579  
© Wildlife Disease Association 1986

## Helminths of the Red-knobbed Coot (*Fulica cristata*) from Barberspan, Republic of South Africa

J. Daniel McLaughlin, Department of Biology, Concordia University, 1455 de Maisonneuve Boulevard West, Montreal, Quebec H3G 1M8, Canada

The red-knobbed or crested coot (*Fulica cristata*) is a sedentary species which is distributed widely throughout the Ethiopian region of Africa (Voous, 1960, Atlas

of European Birds, Vol. 6, Thomas Nelson and Sons, London, p. 87). It is the most abundant waterbird at Barberspan in the western Transvaal (Milstein, 1975, Ostrich Suppl. 10: 1-74; Skead and Dean, 1977, Ostrich Suppl. 12: 3-42) where it is a regular breeder.

Received for publication 2 October 1985.