

Renal Hyperostotic Osteodystrophy Associated with Unilateral Renal Aplasia in a Captive Maned Wolf

Authors: Feedback, Daniel L., Jensen, James M., and Kosanke, Stanley D.

Source: Journal of Wildlife Diseases, 22(4) : 595-600

Published By: Wildlife Disease Association

URL: <https://doi.org/10.7589/0090-3558-22.4.595>

BioOne Complete (complete.BioOne.org) is a full-text database of 200 subscribed and open-access titles in the biological, ecological, and environmental sciences published by nonprofit societies, associations, museums, institutions, and presses.

Your use of this PDF, the BioOne Complete website, and all posted and associated content indicates your acceptance of BioOne's Terms of Use, available at www.bioone.org/terms-of-use.

Usage of BioOne Complete content is strictly limited to personal, educational, and non - commercial use. Commercial inquiries or rights and permissions requests should be directed to the individual publisher as copyright holder.

BioOne sees sustainable scholarly publishing as an inherently collaborative enterprise connecting authors, nonprofit publishers, academic institutions, research libraries, and research funders in the common goal of maximizing access to critical research.

Renal Hyperostotic Osteodystrophy Associated with Unilateral Renal Aplasia in a Captive Maned Wolf

Daniel L. Feedback,^{1,3} James M. Jensen,² and Stanley D. Kosanke,³ ¹Department of Anatomical Sciences, University of Oklahoma Health Sciences Center, Oklahoma City, Oklahoma 73190, USA; ²Oklahoma City Zoo, Oklahoma City, Oklahoma 73111, USA; and ³Department of Pathology, University of Oklahoma Health Sciences Center, Oklahoma City, Oklahoma 73190, USA

A captive 12-yr-old female maned wolf (*Chrysocyon brachyurus*) who had been on breeding loan to the Oklahoma City Zoo for 5 yr became progressively anorexic over a 4-mo period. Her eyes appeared sunken and her overall appearance was unthrifty. Clinical examination during life disclosed the presence of a diffuse gingival hypertrophy and loss of several teeth from their alveolar sockets.

An initial serum chemistry profile revealed a blood urea nitrogen (BUN) concentration of 42 mg/dl (normal geriatric canine range: 7.0–31.5 mg/dl), and a creatinine concentration of 1.6 mg/dl (normal geriatric canine range: 0.10–1.0 mg/dl). The serum calcium, inorganic phosphate and alkaline phosphatase values were normal.

Over the next 10 mo the wolf became progressively thin, had difficulty in chewing her food and continued to have a poor appetite and appearance. She had developed a stiff gait and occasionally had difficulty in rising from a recumbent position. The animal was observed daily at a distance and chemically-immobilized twice for closer examination during the same period. Examination of the oral cavity revealed the presence of additional loose teeth and an irregular thickening of the maxillary and mandibular alveolar arches. Clinical treatment consisted of extraction of loose dentition to restore better masticatory function accompanied by antibiotic and vitamin regimens.

During the same 10-mo period serum

concentrations of BUN and creatinine had increased progressively to a high of 230 mg/dl and 8.4 mg/dl, respectively. The serum concentration of inorganic phosphate had risen to 15 mg/dl (normal geriatric canine range: 2.5–4.4 mg/dl) while serum calcium and alkaline phosphatase values remained normal. Eventually, the animal became anambulatory, moribund and expired despite medical intervention.

At necropsy, the wolf was somewhat thin, its eyes appeared sunken and evidence of a chronic oculonasal discharge was present. Significant gross findings included diffuse, irregular hyperostotic changes of the maxilla and mandible (Fig. 1), parathyroid hyperplasia (Fig. 2), aplasia of the right kidney and old, partially-healed as well as recent, multiple rib fractures. Radiographs taken at necropsy confirmed a generalized osteopenia and demonstrated poorly mineralized calluses associated with the rib fractures (Fig. 3) noted grossly. There was no evidence of soft tissue metastatic calcification by radiography or gross tissue examination. Portions of the right ureter and collecting system were identified, but the right kidney was totally absent. With the exception of some mild cortical scarring, the left kidney was otherwise grossly unremarkable in situ or on cut section (Fig. 4). Blood obtained at necropsy (within 4 hr of death) revealed a BUN of 420 mg/dl, creatinine of 22.0 mg/dl, calcium of 7.1 mg/dl (normal geriatric canine range: 8.4–10.5 mg/dl), inorganic phosphate of 29.0 mg/dl and

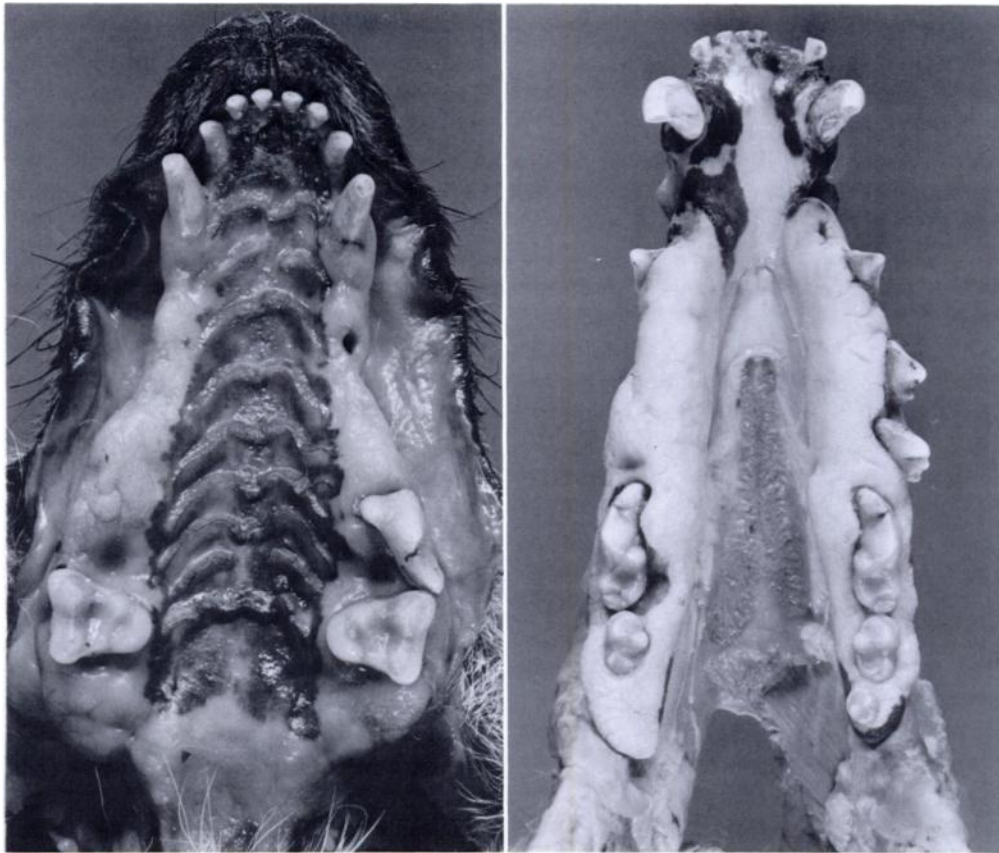


FIGURE 1. Gross photograph of the hyperostotic maxilla (left) and mandible (right) of a captive maned wolf.

an alkaline phosphatase concentration of 52 IU/liter (normal geriatric canine range: 6–80 IU/liter).

Microscopic sections of mandibular and maxillary cancellous bone (Fig. 5) were characterized by increased numbers of osteoclasts, hyperplastic-appearing osteoblasts associated with exuberant osteoid production and loose, highly-vascularized fibrous connective tissue proliferation within the medullary cavity. Histologic examination of other bones, especially those of the abaxial skeleton, showed similar osteodystrophic changes, but were grossly isostotic. All parathyroid glands examined had a similar histologic appearance consisting largely of a diffuse chief cell hyperplasia. Representative sections

of the left kidney were characterized by the presence of a moderate cortical atrophy, focal subcortical scarring, mild chronic interstitial nephritis and moderate nephrocalcinosis. Only occasional senescent glomeruli were observed and the majority of the tubules were normal in appearance. There was no histologic evidence of arteriolar nephrosclerosis, glomerulosclerosis, amyloidosis, or acute or chronic glomerulonephritis.

Fibrous osteodystrophy (osteodystrophia fibrosa) develops in association with prolonged and excessive production of parathormone (PTH) or other calcium-mobilizing agents. Causes include primary, ectopic and secondary hyperparathyroidism.

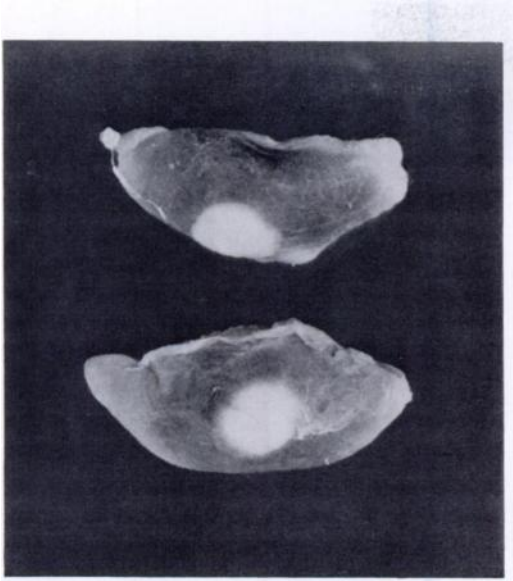


FIGURE 2. Bilaterally enlarged parathyroids III (caudal parathyroids) of a captive maned wolf.

Primary hyperparathyroidism is most often associated with functional benign or malignant primary tumors of the parathyroid, but may also be seen with idiopathic hyperplasia. In the usual case, the involvement is uniglandular and characterized by excessive and autonomous production of PTH. As a cause of fibrous osteodystrophy in domestic or wild animals, primary hyperparathyroidism seems to be implicated only rarely. A few cases have been described in domestic dogs and cats (Krook, 1957, *Acta Pathol. Microbiol. Scand.* 41(Suppl. 122): 1-88; Legendre et al., 1976, *J. Am. Vet. Med. Assoc.* 168: 694-696).

Ectopic hyperparathyroidism which is sometimes referred to as "pseudohyperparathyroidism" occurs secondary to pro-

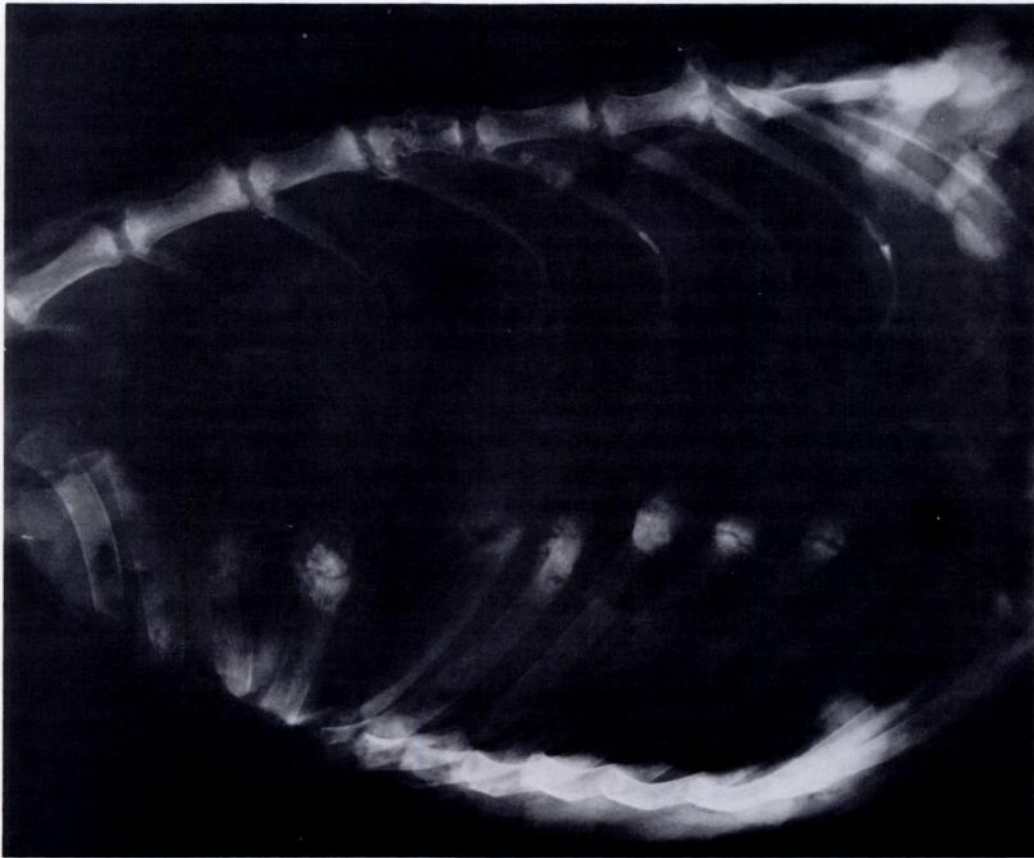


FIGURE 3. Radiograph of right thorax of a captive maned wolf showing recent and old, partially-healed rib fractures and poorly mineralized calluses. Note also fracture of vertebral body.

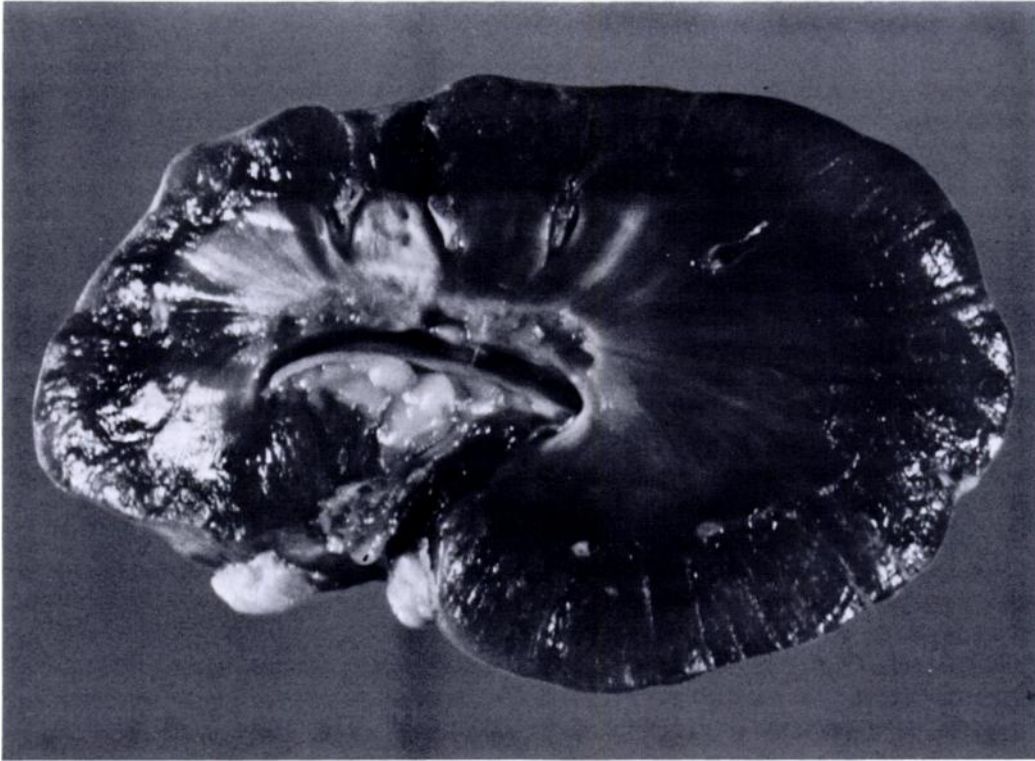


FIGURE 4. Gross photograph of remaining left kidney of a captive maned wolf.

duction of calcium-mobilizing substances by nonparathyroid tumors. Responsible neoplasms include carcinomas of breast, lung, kidney, pancreas, perianal glands, testis, stomach and colon as well as certain hematopoietic and lymphoreticular cancers (Engleman et al., 1985, *Cancer* 56: 777-781).

Secondary hyperparathyroidism results from parathyroid hyperplasia due to either nutritional or renal abnormalities. Nutritional osteodystrophy occurs commonly in dogs (Krook, 1957, *op. cit.*), cats (Palmer, 1968, *Aust. Vet. J.* 44: 151-155), cows, certain nonhuman primates (Krook and Barrett, 1962, *Cornell Vet.* 52: 459-492), horses (Krook and Lowe, 1964, *Vet. Pathol.* 1(Suppl. 1): 1-98), domestic and wild birds (Arnold et al., 1974, *Cornell Vet.* 64: 37-46) and reptiles (Wallach and Hoessle, 1968, *J. Am. Vet. Med. Assoc.* 153: 863-865). More frequently, secondary hyper-

parathyroidism is associated with various congenital or acquired kidney lesions (Jackson et al., 1960, *J. Indiana State Med. Assoc.* 53: 1112-1114; Krook, 1957, *op. cit.*), most commonly chronic renal insufficiency. Occurrence has been described in humans, rats and domestic canines (Itakura et al., 1977, *Vet. Pathol.* 14: 463-469; Krook, 1957, *op. cit.*).

Based on the clinical and pathologic data, the present case represents an example of renal osteodystrophy occurring in a captive wild canine. This case is unusual and important for various reasons. The absence of the right kidney, presumably, but in this case not equivocally a congenital condition, is noteworthy and an association between unilateral renal aplasia and uremia exists. In a series of 9,000 canine necropsies (Krook, 1957, *op. cit.*), nine cases of unilateral renal aplasia were noted. Significant uremia was present in

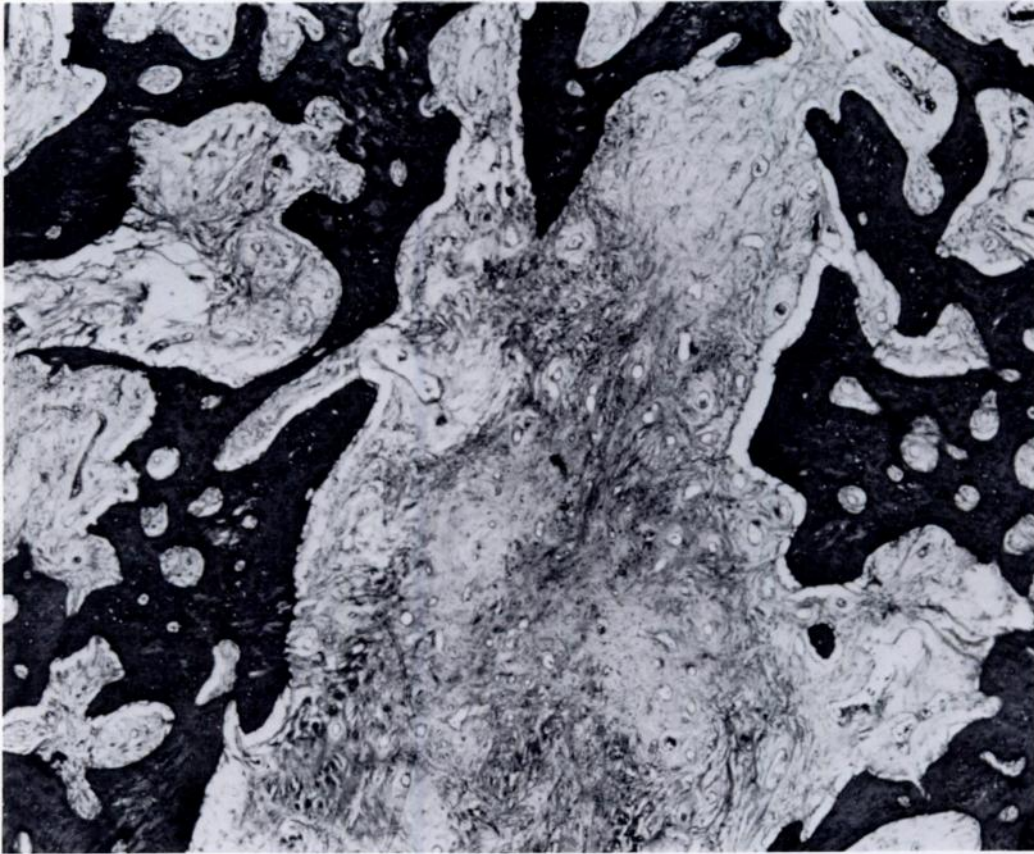


FIGURE 5. Photomicrograph of osteodystrophy in bone from a captive maned wolf with renal insufficiency and unilateral renal agenesis.

four cases, in six dogs the right kidney was involved, and in four cases the aplasia was not accompanied by other renal abnormalities. One dog suffered a spontaneous pathologic fracture. Other lesions of the kidney associated with osteodystrophy in the dog include bilateral hypoplasia, unilateral hypoplasia, renal cortical hypoplasia, and isolated chronic nephritis.

Captive maned wolves in zoological collections have an exceedingly high prevalence of the inherited metabolic disease cystinuria (Bush and Bovee, 1978, *J. Am. Vet. Med. Assoc.* 173: 1159–1162) being as high as 81% in 42 animals tested in one series (Bush et al., 1981, *Science* 212: 919–920). There was no prior history of nephrectomy nor any indication at necropsy

that the absence of the right kidney was acquired during life. Screening tests (nitroprusside method) for cystine in the urine of the wolf described herein were negative for cystine and no renal or urinary bladder calculi were present at the time of necropsy. Recent evidence (Burton, pers. comm.) indicates a possible genetic predisposition for unilateral cryptorchidism in this species as well adding yet another challenge to successful breeding in captivity. The maned wolf is listed as a species vulnerable to extinction (Thornback and Jenkins, eds., 1982, *The International Union for Conservation of Nature and Natural Resources Red Data Book, Part 1: Threatened Mammalian Taxa of the Americas and the Australasian*

Zoogeographic Region, Unipub, New York, 560 pp.) and since there is evidence that unilateral renal aplasia may have some genetic background then such an occurrence may have further impact on an already genetically-compromised species. In this particular case, however, the female wolf was an unsuccessful breeder and

thus has not contributed any further to the present gene pool. Unknown, however, is the prevalence of this abnormality in the existing gene pool, its mode of inheritance, complete pattern of expression and long term effect on successful propagation of this species.

Journal of Wildlife Diseases, 22(4), 1986, pp. 600-603

Failure of Yohimbine Hydrochloride to Antagonize Ketamine Hydrochloride Immobilization of Gray Wolves

Terry J. Kreeger, Department of Fisheries and Wildlife, University of Minnesota, St. Paul, Minnesota 55108, USA; and **Ulysses S. Seal**, Research Service, Veteran's Administration Medical Center, Minneapolis, Minnesota 55417, USA and Departments of Biochemistry and Fisheries and Wildlife, University of Minnesota, St. Paul, Minnesota 55108, USA

The indolealkylamine, yohimbine hydrochloride (HCl), has been used to antagonize ketamine HCl-xylazine HCl anesthesia in a variety of wild and domestic animals (Jessup et al., 1983, *J. Am. Vet. Med. Assoc.* 183: 1339-1340; Hsu and Lu, 1984, *J. Am. Vet. Med. Assoc.* 185: 886-888; Jacobson and Kollias, 1984, *Proc. Am. Assoc. Zoo Vet.*, p. 57; Kitzman et al., 1984, *Am. J. Vet. Res.* 45: 875-879; Jacobson et al., 1985, *J. Am. Vet. Med. Assoc.* 187: 1195-1198; Mech et al., 1985, *J. Wildl. Dis.* 21: 405-410; Ramsay et al., 1985, *J. Wildl. Dis.* 21: 396-400). Although the ability of yohimbine HCl to antagonize xylazine HCl sedation has been well established (Hsu, 1981, *J. Pharmacol. Exp. Ther.* 218: 188-192; Kitzman et al., 1982, *Am. J. Vet. Res.* 43: 2165-2169; Jensen et al., 1983, *Proc. Am. Assoc. Zoo Vet.*, pp. 65-66; Hsu and Schulaw, 1984, *J. Am. Vet. Med. Assoc.* 185: 1301-1303; Hatch et al., 1985, *Am. J. Vet. Res.* 46: 371-375; Jessup et al., 1985, *J. Am. Vet. Med. Assoc.* 187:

1251-1253; Renecker and Olsen, 1985, *J. Am. Vet. Med. Assoc.* 187: 1199-1201), the ability of yohimbine HCl to antagonize ketamine HCl anesthesia is equivocal. "Arousal times" (the ability to regain righting reflex) were shortened significantly in domestic cats anesthetized with 20.0 mg/kg ketamine HCl, then given 0.25 mg/kg yohimbine HCl. Ambulation times, however, were lengthened (Hatch et al., 1983, *Am. J. Vet. Res.* 44: 417-423). Also, yohimbine HCl (0.5 mg/kg) failed to antagonize ketamine HCl (10.0 mg/kg) anesthesia in rhesus monkeys (Lynch and Line, 1985, *Lab. An. Sci.* 35: 417-418). Coyotes anesthetized with 2.0 mg/kg xylazine HCl and 4.0 mg/kg ketamine HCl, then given 0.2 mg/kg yohimbine HCl, appeared to have a residual ketamine HCl effect which emerged after the antagonism of xylazine HCl (Kreeger and Seal, 1986, *J. Wildl. Dis.* 22: 604-606). The purpose of the present paper was to determine if yohimbine HCl could antagonize ketamine HCl anesthesia in gray wolves (*Canis lupus* L.).

Ten adult gray wolves (five female, five

Received for publication 25 February 1986.