

## **Ostertagiosis in a White-tailed Deer due to *Ostertagia ostertagi***

Authors: Conti, Joseph A., and Howerth, Elizabeth W.

Source: Journal of Wildlife Diseases, 23(1) : 159-162

Published By: Wildlife Disease Association

URL: <https://doi.org/10.7589/0090-3558-23.1.159>

---

BioOne Complete ([complete.BioOne.org](https://complete.BioOne.org)) is a full-text database of 200 subscribed and open-access titles in the biological, ecological, and environmental sciences published by nonprofit societies, associations, museums, institutions, and presses.

Your use of this PDF, the BioOne Complete website, and all posted and associated content indicates your acceptance of BioOne's Terms of Use, available at [www.bioone.org/terms-of-use](https://www.bioone.org/terms-of-use).

Usage of BioOne Complete content is strictly limited to personal, educational, and non - commercial use. Commercial inquiries or rights and permissions requests should be directed to the individual publisher as copyright holder.

---

BioOne sees sustainable scholarly publishing as an inherently collaborative enterprise connecting authors, nonprofit publishers, academic institutions, research libraries, and research funders in the common goal of maximizing access to critical research.

to protect exposed personnel and point to the importance of these routines.

This work was supported in part by Federal Aid in Wildlife Restoration, Wy-

oming Project FW-3-R. We would like to thank Mr. Rod Pfister who brought this case to our attention and Mr. John Sugimoto for the photography.

*Journal of Wildlife Diseases*, 23(1), 1987, pp. 159-162  
© Wildlife Disease Association 1987

## Ostertagiosis in a White-tailed Deer due to *Ostertagia ostertagi*

Joseph A. Conti and Elizabeth W. Howerth, Southeastern Cooperative Wildlife Disease Study, Department of Parasitology, College of Veterinary Medicine, The University of Georgia, Athens, Georgia 30602, USA

A debilitated yearling male white-tailed deer (*Odocoileus virginianus*) was found in a cattle pasture in Wilkes County, Georgia, on 2 April 1985 and submitted to the Southeastern Cooperative Wildlife Disease Study for examination. The deer was emaciated (20 kg) and covered by thousands of lonestar ticks (*Amblyomma americanum*), especially on the ears and around the anus. The latter was swollen and contained numerous purulent fistulous tracts. The animal could not stand, and neither deep pain reflexes nor a paniculus response could be elicited. Tick paralysis was suspected, the animal was lightly tranquilized (Rompun), and a large number of ticks were individually removed with forceps. The deer was then dipped with an organophosphate pesticide (Dermaton H) to kill the remaining ticks and given an intramuscular injection of penicillin. The deer died during the night and was necropsied the following morning.

At necropsy, there was widespread individual to confluent nodular thickening of the abomasal mucosa which spared the pyloric antrum (Fig. 1). The margins of the mucosal folds were most severely involved and had scattered petechial and

ecchymotic hemorrhages. Generalized enlargement of lymph nodes, splenic lymphoid hyperplasia, serous atrophy of fat, pale and swollen kidneys, and a few small, poorly circumscribed, pale foci in the heart were present. On a blood smear, many monocytes contained a granular rickettsial-type intracytoplasmic inclusion body, as well as a variety of bacilli and cocci. Mononuclear cells in lymph node smears contained similar rickettsial-type inclusion bodies and bacteria. Tentative diagnoses of ostertagiosis, rickettsiosis, and bacteremia secondary to tick infestation were made.

A dilution count (Eve and Kellogg, 1977, *J. Wildl. Manage.* 41: 169-177) was performed to estimate the total number of nematodes in the abomasum. A total of 3,660 nematodes was estimated, composed of approximately 2,620 adult and 1,040 larval forms. Of the adult total, ratios of identifiable male worms showed 68.4% (1,793) of the nematodes recovered to be the medium stomach worm, *Ostertagia ostertagi*. The remaining parasites were two other medium stomach worms, *Ostertagia dikmansii* (2.6%), and *Apteria odocoilei* (2.6%), the large stomach worm, *Haemonchus contortus* (7.9%), and three small stomach worms, *Trichostrongylus axei* (10.5%), *T. askivali* (5.3%), and *T. dosteri* (2.6%). Morphologically, it

---

Received for publication 9 January 1986.

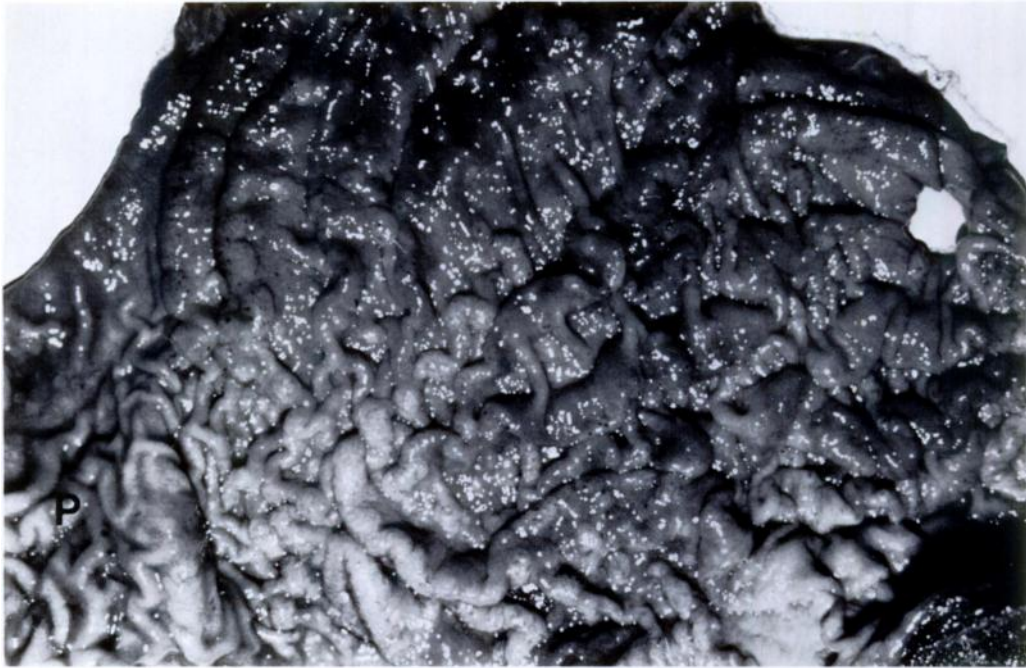


FIGURE 1. Severe widespread nodular hyperplasia of the abomasal mucosa of a white-tailed deer. Note sparing of pyloric area (P).

appeared that the *O. ostertagi* were primarily subadults since the majority of males had lightly sclerotized and incompletely developed spicules, while most of the females lacked eggs in the uterus. The remaining species of parasites were mainly adult worms. Representative specimens were deposited in the U.S. National Parasite Collection, Beltsville, Maryland 20705, USA (Accession Numbers 79102–79108).

Histological examination of the abomasum revealed small scattered superficial erosions and irregular thickening of the mucosa due to hyperplasia in the foveolate and neck regions of the glands (Fig. 2). Occasionally, cystic empty glands and small foci of mucus cell hyperplasia occurred in the midzone-to-deep mucosa (Fig. 2). Multiple focal lymphoid accumulations were present deep in the lamina propria (Fig. 2). Additional findings were mild lymphocytic encephalitis and mild lymphocytic epicarditis.

Rickettsial-type organisms were not observed in ultrathin sections of lymph node and spleen examined by transmission electron microscopy. Lymph node and spleen were submitted to the Athens Diagnostic Laboratory, Athens, Georgia, for egg inoculation, but rickettsiae were not isolated after two passages. An alpha *Streptococcus* sp. and *Flavobacterium multivorum* were isolated from a lymph node.

In cattle, heavy infections with *Ostertagia ostertagi* (at least 10,000 worms or greater, depending on age) can result in severe gastric disease (Levine, 1980, *Nematode Parasites of Domestic Animals and of Man*, Burgess Pub. Co., Minneapolis, Minnesota, 477 pp.). Infected cattle may exhibit two syndromes of infection: ostertagiosis type I from maturation of larvae shortly after ingestion, or ostertagiosis type II from the sudden and spontaneous maturation of larvae after a period of arrested development (Schillhorn

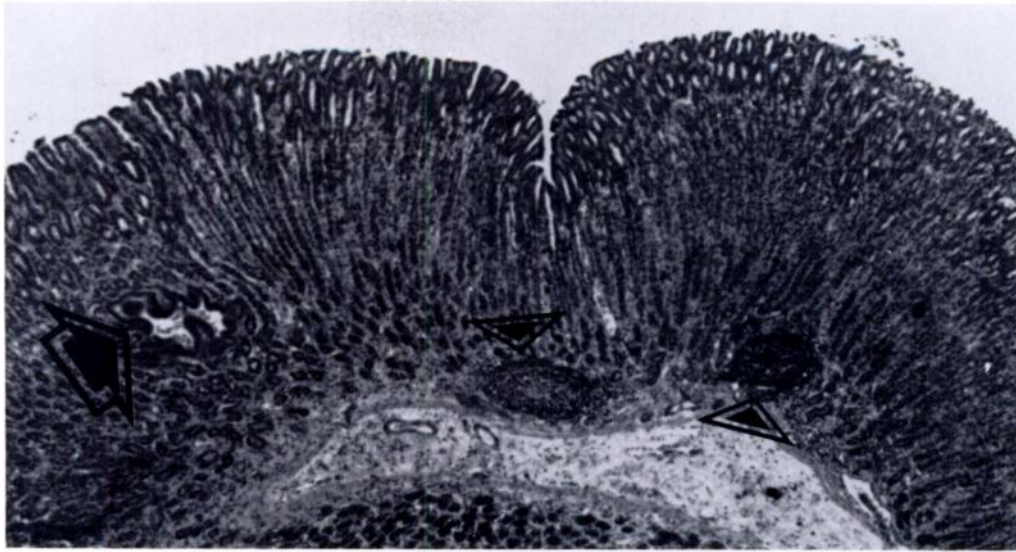


FIGURE 2. Abomasal mucosa of a white-tailed deer with hyperplasia of the foveolate and neck regions of the glands. Note small area of mucus cell hyperplasia (arrow) and two lymphoid nodules (arrowheads). H&E,  $\times 30$ .

van Veen, 1981, *Comp. Cont. Educ.* 3: 175–183; Snider et al., 1983, *Am. J. Pathol.* 113: 410–412). The type I syndrome results in greater morbidity than mortality. The type II syndrome is usually more pathogenic, often producing death due to severe abomasal lesions and associated gastric dysfunction (Snider et al., 1983, *op. cit.*).

The clinical, pathologic, and parasitologic findings in this deer were compatible with a diagnosis of ostertagiosis due to *O. ostertagi*, most similar to the type II syndrome of cattle. Although the number of worms present was low as compared to the number present in ostertagiosis in cattle, studies in the southeastern United States have shown that deer with an abomasal parasite count greater than 1,500 usually are in poor condition (Eve and Kellogg, 1977, *op. cit.*). Therefore, the *O. ostertagi* infection alone may have been severe enough to cause clinical disease in this deer. In addition, the condition of this deer may have been worsened by the presence of the other six species of aboma-

sal parasites. Snider et al. (1985, *Am. J. Vet. Res.* 46: 1748–1752) found abomasal lesions to be more severe in cattle infected with both *O. ostertagi* and *T. axei* than in cattle with single species infections. Greater larval inhibition also was observed due to the synergistic effect of these two species of parasites.

The fact that most male and female *O. ostertagi* were at the same subadult stage indicates that sudden and spontaneous development of larvae occurred as seen in ostertagiosis type II. However, the time of year when the deer was found (April) does not coincide with the occurrence of the type II syndrome as reported in previous work with cattle in the southeastern United States. In Louisiana, Williams et al. (1983, *Int. J. Parasitol.* 13: 133–143) found that peak acquisition of inhibition-prone larvae occurred during March–May followed by a summer of arrested development and the onset of ostertagiosis type II in the fall. This phenomenon is quite different from what occurs in northern temperate climates, where the type II infec-

tion is observed in the spring following a winter of arrested development. Williams et al. (1983, op. cit.) did acknowledge that considerable variations in the incidence of either the type I or type II disease syndromes might occur based on the diversities of physiographic and climatic conditions, as well as cattle management strategies. It is quite possible that the epidemiological conditions in the habitat occupied by this deer in the piedmont region of Georgia were suitable for the development of ostertagiosis type II during April as in northern temperate climates. Alternatively, it is possible that inhibition of larvae did occur in March, but was interrupted after a few weeks due to some immunosuppressive factor such as concomitant disease or nutritional stress.

Because *O. ostertagi* is a pathogen in domestic livestock, Prestwood and Pursglove (1981, *In Diseases and Parasites of White-tailed Deer*, Davidson et al. (eds.), Tall Timbers Res. Sta. Pub. No. 7, Tallahassee, Florida, pp. 318–350) suggested

that under unusual conditions it may be a pathogen for deer. *Ostertagia ostertagi* does not occur commonly in deer, and experimental evidence shows white-tailed deer to be a poor host for this parasite (McGhee, 1981, *J. Parasitol.* 67: 969–970). Thus, the discovery of ostertagiosis due to *O. ostertagi* in a free-ranging white-tailed deer is unusual and unexpected. Whether there were any synergistic effects of the rickettsial-type organism, bacteria, or ticks with *O. ostertagi* is unknown.

This study was supported by an appropriation from the Congress of the United States to the Southeastern Cooperative Wildlife Disease Study, Department of Parasitology, College of Veterinary Medicine, The University of Georgia. Funds were administered and research was coordinated under the Federal Aid to Wildlife Restoration Act (50 Stat. 917) and through Contract Number 14-16-0004-85-007, Fish and Wildlife Service, U.S. Department of the Interior.

*Journal of Wildlife Diseases*, 23(1), 1987, pp. 162–165  
© Wildlife Disease Association 1987

## Clinical Mange of the Black Bear (*Ursus americanus*) Caused by *Sarcoptes scabiei* (Acarina, Sarcoptidae)

Stephen M. Schmitt, Thomas M. Cooley, and Paul D. Friedrich, Rose Lake Wildlife Disease Laboratory, Michigan Department of Natural Resources, East Lansing, Michigan 48823, USA; and Tjaart W. Schillhorn van Veen, College of Veterinary Medicine, Michigan State University, East Lansing, Michigan, 48824 USA

Sarcoptic mange has been reported in numerous species of wild mammals including: red fox (*Vulpes vulpes*) and coyote (*Canis latrans*) (Trainer and Hale, 1969, *Bull. Wildl. Dis. Assoc.* 5: 387–391); gray wolf (*Canis lupus*) (Todd et al., 1981, *Proc. First Worldwide Furbearer Conf.* 2: 706–729); gray fox (*Urocyon cinereoar-*

*genteus*) (Stone et al., 1982, *N.Y. Fish Game J.* 29: 102–103); fisher (*Martes pennanti*) (O'Meara et al., 1960, *J. Wildl. Manage.* 24: 339); porcupine (*Erethizon dorsatum*) (Payne and O'Meara, 1958, *J. Wildl. Manage.* 22: 321–322); and eastern fox squirrel (*Sciurus niger*) (Allen, 1942, *Am. Midl. Nat.* 27: 338–379). Surveys and reviews of black bear ectoparasites make no mention of *Sarcoptes scabiei* (Rogers and Rogers, 1976, *Proc. 3rd Int. Conf. Bear*

Received for publication 2 December 1985.