

## **Septicemic Listeriosis in a Reindeer Calf**

Authors: Evans, M. G., and Watson, G. L.

Source: Journal of Wildlife Diseases, 23(2) : 314-317

Published By: Wildlife Disease Association

URL: <https://doi.org/10.7589/0090-3558-23.2.314>

---

BioOne Complete ([complete.BioOne.org](https://complete.BioOne.org)) is a full-text database of 200 subscribed and open-access titles in the biological, ecological, and environmental sciences published by nonprofit societies, associations, museums, institutions, and presses.

Your use of this PDF, the BioOne Complete website, and all posted and associated content indicates your acceptance of BioOne's Terms of Use, available at [www.bioone.org/terms-of-use](https://www.bioone.org/terms-of-use).

Usage of BioOne Complete content is strictly limited to personal, educational, and non - commercial use. Commercial inquiries or rights and permissions requests should be directed to the individual publisher as copyright holder.

---

BioOne sees sustainable scholarly publishing as an inherently collaborative enterprise connecting authors, nonprofit publishers, academic institutions, research libraries, and research funders in the common goal of maximizing access to critical research.

## Septicemic Listeriosis in a Reindeer Calf

M. G. Evans and G. L. Watson, Department of Pathology and the Animal Health Diagnostic Laboratory, College of Veterinary Medicine, Michigan State University, East Lansing, Michigan 48824, USA

**ABSTRACT:** Septicemic listeriosis is described in a 2-day-old reindeer calf (*Rangifer tarandus tarandus*) from a local zoo. The gross and microscopic lesions were typical of disease caused by bacterial septicemia. Major lesions included necrosis of the liver, lung, adrenal gland, spleen, and lymph node. The diagnosis was suspected by special histopathological stains and confirmed by isolation of *Listeria monocytogenes* from multiple organs. This is the first report of listeriosis in a reindeer.

**Key words:** Reindeer, *Rangifer tarandus*, *Listeria monocytogenes*, listeriosis, septicemia, calf, case report.

Tissues from a 2-day-old female reindeer calf (*Rangifer tarandus tarandus*), born in late May 1985 were submitted to the Animal Health Diagnostic Laboratory at Michigan State University after it was found dead by a zookeeper. The calf appeared underweight at birth but had been nursing. There was no reported crowding, unusual weather, or illness in her dam. Other animals in the herd were not affected, and listeriosis had not been recently diagnosed in other zoo animals or personnel.

Grossly, the animal was severely dehydrated but had no other external abnormalities. The prosectors described multiple abscesses throughout the parenchyma of the liver, spleen, and kidney. The lungs had multifocal consolidation. Curdled milk and grass were found in the abomasum. The colon had normal feces. Swabs for bacteriologic culture (submitted from the zoo) were prepared from the liver, lung, and kidney and streaked onto blood agar. Brain and kidney were not submitted for evaluation.

Histologically, the most significant changes were noted in the liver, lung, ad-

renal gland, spleen, and lymph node. The liver had multiple, variably-sized, foci of hepatocellular necrosis which occasionally coalesced. These foci were characterized by a marked fibrinous exudation and an irregular infiltration of inflammatory cells. Inflammatory cells were mainly intact neutrophils and degenerative cells with a small scattering of mononuclear cells and occasional macrophages. Occasional thrombosis was also observed. Sections of lung had multiple foci of interstitial necrosis and inflammation (Fig. 1). Fibrin exudation was accompanied by an infiltration of neutrophils and mononuclear cells. Some lung lobules contained severe diffuse seroproteinaceous exudate, and neutrophils were observed within terminal bronchioles. Neutrophilic inflammation was evident in the adrenal cortex accompanied by a solitary focus of necrosis (Fig. 2). Sections of spleen had severe, multiple, and variable-sized necrotic foci. Some foci were virtually devoid of inflammatory cell infiltrates while others had marked accumulations of neutrophils. A large splenic vessel was thrombosed. Sections of a lymph node located adjacent to the pancreas had multifocal areas of necrosis mainly within cortical regions. There was intense fibrin exudation within the subcapsular sinus and between the layers of the capsule. Fibrin thrombi were found in numerous blood vessels of this node. Sections of heart, skeletal muscle, pancreas, and aorta were histologically normal.

Microscopic examination of Warthin-Starry-stained sections of liver, lung, adrenal gland, and lymph node revealed multiple, approximately  $1 \times 3 \mu\text{m}$ , rod-shaped bacteria associated with foci of ne-

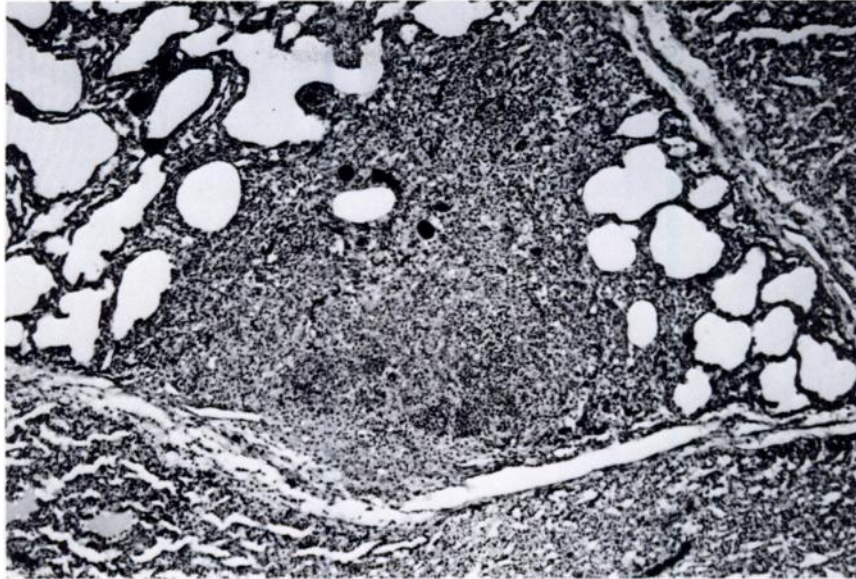


FIGURE 1. Section of lung with large focus of necrosis. H&E, 90 $\times$ .

crisis (Fig. 3). Blood agar cultures yielded *Listeria monocytogenes* from liver, lung, and kidney. Subtyping and serotyping were not performed. There were no other demonstrable etiologic agents in any of the tissues examined.

Listeriosis occurs as a sporadic disease

in many mammalian species such as deer, hares, rabbits, and chinchillas, as well as in man, poultry, fish, crustaceans, and ticks (Buxton and Fraser, 1977; Jones and Hunt, 1983). The most common laboratory tests for differentiation and identification are gram stain results from broth culture, mo-

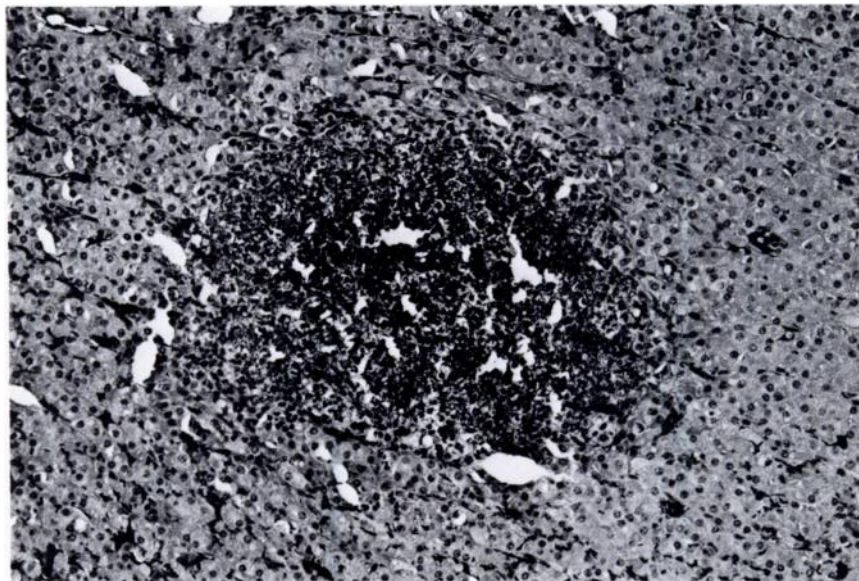


FIGURE 2. Section of adrenal gland with necrosis and inflammatory cells. H&E, 120 $\times$ .

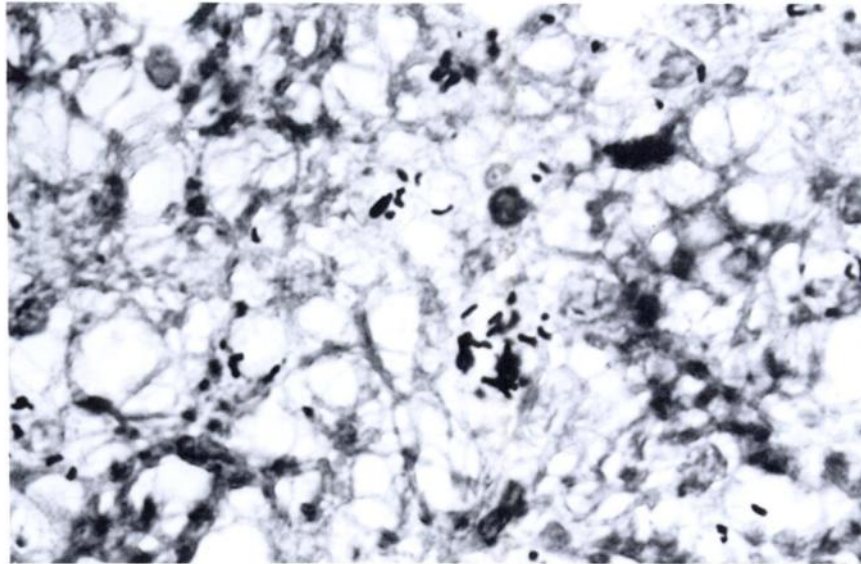


FIGURE 3. Section of spleen. Note short, rod-shaped *Listeria monocytogenes*. Warthin-Starry, 350 $\times$ .

tility, and catalase activity (Gray and Killinger, 1966; Buxton and Fraser, 1977). There are five designated serotypes and a number of subtypes.

The suspected route of infection with *L. monocytogenes* is generally thought to be oral. The organisms have the ability to penetrate epithelial cells. It is thought that phagocytosis and transport by macrophages results in the septicemic process (Jones and Hunt, 1983). Onset of the disease may be related to stress, but the pathogenesis is poorly understood. Culture of affected tissues in cases of septicemic listeriosis usually yields the causative agent. However, the organism may be difficult to isolate from neural tissue of ruminants with the central nervous system form of the disease. While the disease has been described in many ruminant species, including cattle, sheep, goats, buffalo, moose, roe deer, white-tailed deer, and pronghorn antelope (Gray and Killinger, 1966; Eveland, 1970; Wallach and Boever, 1983), we found no published reports of listeriosis in reindeer.

Listeriosis must be considered in any disease of ruminants in which multiple necrotic foci are observed in numerous or-

gans. Other diseases that could cause these lesions include septicemic salmonellosis, septicemic pasteurellosis, and Tyzzer's disease. Sudden death of the neonate may be seen in any of these conditions. Tyzzer's disease can best be differentiated by histologic examination of Warthin-Starry-stained sections. Septicemic salmonellosis and pasteurellosis can be diagnosed by isolation of the causative agent from multiple tissues.

There are three described forms of listeriosis. The meningoencephalitic form occurs in several species of large animals. It must be differentiated from rabies, the nervous form of acetonemia in cattle, and pregnancy toxemia in sheep. The latter two diseases are associated with ketonuria. Microabscessation and perivascular mononuclear cell cuffing with or without neutrophils in the pons, medulla oblongata, and spinal cord are considered the typical histopathologic lesions in affected neural tissue (Jones and Hunt, 1983).

Listerial abortion has been described in cattle, sheep, goats, and (rarely) pigs. The incidence of listerial abortion may reach 15% in sheep and goats (Blood et al., 1983).



Listerial abortion must be differentiated from abortion due to infection with *Bruceella* spp.

Listerial septicemia usually does not occur in adult ruminants but is more commonly seen in monogastric neonates, including foals, young pigs, and newborn lambs and calves. The disease presents as depression, wasting, emaciation, and pyrexia. Except for pyrexia, these clinical signs were observed in our reindeer calf. Interestingly, this form of the disease has been reported in mature ewes and goats with retention of fetal membranes following listerial abortion (Blood et al., 1983). Listerial septicemia has also been described in domestic rabbits and was associated with listerial abortion (Flatt, 1974; Watson and Evans, 1985). As with any septicemic process, multiple tissues may contain necrotic foci. Metritis may be seen with both the septicemic and abortive forms of listeriosis because the organism seemingly has a predilection for the gravid uterus (Watson and Evans, 1985).

The route of infection in this calf is difficult to determine. Given the nearly chronic nature of some of the histologic lesions, intrauterine infection was possible. Infected milk is also a known source of *L. monocytogenes* to man and animals. No attempt was made to culture the dam in this case, but she has reportedly remained healthy. However, in women it is known that asymptomatic carriers can spread the

disease to the newborn either transplacentally or during parturition (Hoepflich, 1983).

#### LITERATURE CITED

- BLOOD, D. C., D. M. RADOSTITS, AND J. A. HENDERSON. 1983. Diseases caused by bacteria I. In *Veterinary medicine*, 6th ed. Bailliere Tindal, London, England, pp. 523-526.
- BUXTON, A., AND G. FRASER. 1977. *Listeria*. In *Animal microbiology*, Vol 1. Blackwell Scientific Publications, Oxford, England, pp. 189-193.
- EVELAND, W. C. 1970. Listeriosis. In *Infectious diseases of wild animals*, J. W. Davis, L. H. Karsted, and D. O. Trainer (eds.). The Iowa State University Press, Ames, Iowa, pp. 273-282.
- FLATT, R. E. 1974. Bacterial diseases. In *The biology of the laboratory rabbit*, S. H. Weisbroth, R. E. Flatt, and A. L. Kraus (eds.). Academic Press, New York, New York, pp. 219-221.
- GRAY, M. L., AND A. H. KILLINGER. 1966. *Listeria monocytogenes* and listeric infections. *Bacteriological Reviews* 30: 309-382.
- HOEPFICH, P. D. 1983. Infections caused by *Listeria monocytogenes* and *Erysipelas rhusiopathiae*. In *Harrison's principles of internal medicine*, 10th ed., R. G. Petersdorf, R. D. Adams, E. Braunwald, K. J. Isselbacher, and J. B. Martin (eds.). McGraw-Hill, New York, New York, pp. 989-991.
- JONES, T. C., AND R. D. HUNT. 1983. Diseases due to simple bacteria. In *Veterinary pathology*, 5th ed. Lea and Febiger, Philadelphia, Pennsylvania, pp. 631-634.
- WALLACH, J. D., AND W. J. BOEVER. 1983. Ruminants. In *Diseases of exotic animals*. W. B. Saunders Co., Philadelphia, Pennsylvania, p. 257.
- WATSON, G. L., AND M. G. EVANS. 1985. Listeriosis in a rabbit. *Veterinary Pathology* 22: 191-193.

Received for publication 12 June 1986.