

Blastomycosis in Wild Wolves

Author: Thiel, Richard P.

Source: Journal of Wildlife Diseases, 23(2) : 321-323

Published By: Wildlife Disease Association

URL: <https://doi.org/10.7589/0090-3558-23.2.321>

BioOne Complete (complete.BioOne.org) is a full-text database of 200 subscribed and open-access titles in the biological, ecological, and environmental sciences published by nonprofit societies, associations, museums, institutions, and presses.

Your use of this PDF, the BioOne Complete website, and all posted and associated content indicates your acceptance of BioOne's Terms of Use, available at www.bioone.org/terms-of-use.

Usage of BioOne Complete content is strictly limited to personal, educational, and non - commercial use. Commercial inquiries or rights and permissions requests should be directed to the individual publisher as copyright holder.

BioOne sees sustainable scholarly publishing as an inherently collaborative enterprise connecting authors, nonprofit publishers, academic institutions, research libraries, and research funders in the common goal of maximizing access to critical research.

Blastomycosis in Wild Wolves

Richard P. Thiel, Bureau of Endangered Resources, Department of Natural Resources, Box 7921, Madison, Wisconsin 53707; **L. David Mech**,¹ U.S. Fish & Wildlife Service, Patuxent Wildlife Research Center, Laurel, Maryland 20708; **George R. Ruth**, Department of Veterinary Diagnostic Investigations, University of Minnesota, St. Paul, Minnesota 55108; **John R. Archer**, State Lab of Hygiene, 465 Henry Mall, Madison, Wisconsin 53706; and **Leo Kaufman**, Division of Mycotic Diseases, Center for Infectious Diseases, Centers for Disease Control, U.S. Public Health Service, Department of Health and Human Services, Atlanta, Georgia 30333. ¹ Mailing address: North Central Forest Experiment Station, 1992 Folwell Ave., St. Paul, Minnesota 55108

ABSTRACT: Blastomycosis was fatal to a wild wolf in Minnesota, and serologic evidence of blastomycosis was found in a Wisconsin wolf. No unusual movements were detected in the Minnesota animal from October 1983 through October 1985. However, by early December 1985, this wolf was weak and debilitated, and it perished on 14 December after approaching a human residence.

Key words: Blastomycosis, immunodiagnosis, fungus, Minnesota, pneumonia, timber wolf, zoonosis, *Canis lupus*.

Blastomycosis is a primary pulmonary disease of humans and dogs, and occasionally of other animals (Jungerman and Schwartzman, 1972; Stroud and Coles, 1980; Legendre et al., 1981), which can disseminate to the skin and other organs. It is a chronic pyogranulomatous disease caused by the dimorphic fungus, *Blastomyces dermatitidis*. Canine blastomycosis is characterized by chronic cough, dyspnea, weakness, lethargy, lameness, anorexia, weight loss, nasal and eye discharge, and cutaneous lesions or tumor-like lumps. The untreated disease is often fatal (Legendre et al., 1984).

This note reports a case of blastomycosis in a wild wolf (*Canis lupus*) from Minnesota and serologic evidence of blastomycosis from another free-ranging wolf in Wisconsin. The Minnesota specimen, an adult male wolf (6530) from the Perch Lake pack (Mech and Hertel, 1983), was live-trapped (Mech, 1974) in St. Louis County four times between 12 August and 6 October 1983. He weighed from 23.6 to 32.3 kg, the latter with his stomach full. He was

located by radio telemetry 135 times over a 1,867 km² area through 30 October 1985, during which time no unusual movements were detected.

The animal was lost to tracking attempts from 6 October until 8 December 1985 when he was observed feeding on a deer (*Odocoileus virginianus*) carcass approximately 100 m from a cabin 16 km east of our study area. The cabin residents reported that the wolf was weak and debilitated. He remained in the vicinity through 0300 hr on 14 December 1985. At that time the wolf thrust against a cabin window and almost broke it. The residents threw a blanket over him, and brought him inside where he offered no resistance and failed to respond to attempts to feed him. He died a few hours later.

At necropsy, the lungs contained many firm nodules to 2.0 cm in diameter. The larger nodules were cavitated. Other lesions were not detected. Histologically, there were many focal concentrations of macrophages throughout the lungs. In areas of granulomatous inflammation there were many yeast-like round cells that had a refractile thin wall with a nucleus separated from it by a clear thin space (Fig. 1). The yeast-like structures were budding, and some were found within macrophages. These findings led to a diagnosis of pulmonary blastomycosis, which was confirmed by specific immunofluorescent staining of the yeast cells in the lung tissue (Kaplan and Kaufman, 1963).

In the serologic study, wolves were live-

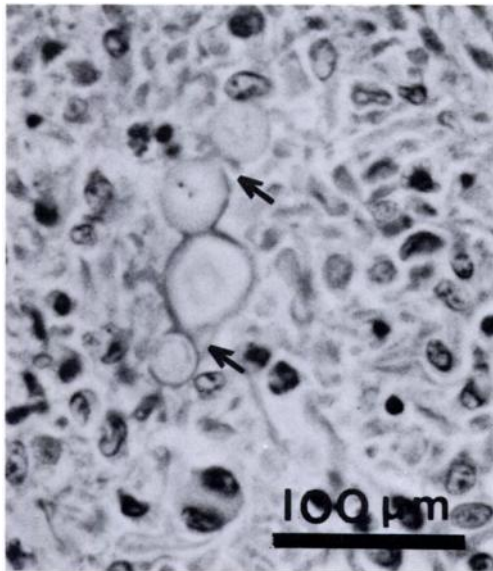


FIGURE 1. Wolf lung tissue showing granulomatous inflammation and budding (arrows) yeast-like cells.

trapped, anesthetized with ketamine hydrochloride and promazine hydrochloride, and blood-sampled (Mech, 1974). Merthiolate was added to the blood serum to give a concentration of $1:1 \times 10^4$, and the sera were frozen and tested at the Centers for Disease Control, Atlanta, Georgia. Immunodiffusion (ID) tests were conducted on all sera. Six of the sera were retested using the enzyme-linked immunosorbent assay (ELISA) technique (Turner et al., 1986). A positive antibody reaction to the specific A antigen in ID is considered diagnostic for blastomycosis. ELISA titers of 1:8 and 1:16 are considered presumptive evidence of blastomycosis, and titers $\geq 1:32$ are diagnostic. Serum from 18 wolves, three coyotes (*C. latrans*) and one bobcat (*Felis rufus*) captured in Wisconsin during 1982–1985, and from 28 wolves caught in northcentral and northwestern Minnesota in 1982–1983 were tested for blastomycosis, and all were negative except an adult male wolf (021) from Douglas County, Wisconsin.

Wolf 6530, whose stored serum from a 4 September 1983 capture was tested in

1986, was negative by ID and had a titer of 1:8 by ELISA. Wolf 021 had a serum A precipitin and a diagnostic ELISA titer of 1:128. The animal weighed 32.7 kg when captured on 22 May 1982, showed no symptoms, and appeared healthy. His weight was close to the mean (33.0 kg) of 12 adult males captured in May. Wolf 021 was located 71 times in the 262 days before his collar was chewed off by other wolves about 8 February 1983 (Thiel and Fritts, 1983). While wolf 021 was monitored, his movements and activities were considered normal, and he appeared healthy on the 13 occasions he was observed.

Blastomycosis is enzootic in Minnesota (Schlosser, 1980), Wisconsin (Sarosi et al., 1979; McDonough and Kuzma, 1980), and infections or outbreaks were geographically concentrated in areas with sandy, acid soils and along waterways especially on or near impoundments (Archer, 1985).

Blastomycosis is not known to be contagious. Infection is thought to be associated with certain point sources in the environment. *Blastomyces dermatitidis* has been isolated from soil associated with a beaver (*Castor canadensis*) lodge in northern Wisconsin (Klein et al., 1986). Wolves prey on beaver and sometimes situate summer homesites near beaver-created flowages where perhaps they become exposed to the fungus. Because of the potential impact of blastomycosis on Wisconsin's endangered wolf population, continued surveillance for the disease is recommended.

This study was supported by the U.S. Fish and Wildlife Service and the U.S.D.A. North Central Forest Experiment Station. Steven H. Fritts generously supplied the Minnesota wolf sera.

LITERATURE CITED

- ARCHER, J. 1985. Epidemiology of canine blastomycosis in Wisconsin. M.S. Thesis. University of Wisconsin, Stevens Point, Wisconsin, 48 pp.
- JUNGERMAN, P. F., AND R. M. SCHWARTZMAN. 1972. Veterinary medical mycology. Lea and Febiger, Philadelphia, Pennsylvania, pp. 124–138.
- KAPLAN, W., AND L. KAUFMAN. 1963. Specific flu-

- orescent antiglobulins for detection and identification of *Blastomyces dermatitidis* yeast-phase cells. *Myopathologia et Mycologia Applicata* 19: 173-180.
- KLEIN, B. S., J. M. VERGERONT, R. J. WEEKS, U. N. KUMAR, G. MATHAI, B. VARKEY, L. KAUFMAN, R. W. BRADSHER, J. F. STOEBIG, AND J. P. DAVIS. 1986. Isolation of *Blastomyces dermatitidis* in soil associated with a large outbreak of blastomycosis in Wisconsin. *New England Journal of Medicine* 314: 529-534.
- LEGENBRE, A. M., B. A. SELCER, D. F. EDWARDS, AND R. STEVENS. 1984. Treatment of canine blastomycosis with amphotericin B and ketoconazole. *Journal of the American Veterinary Medical Association* 184: 1249-1254.
- , M. WALKER, N. BUYUKMIHCI, AND R. STEVENS. 1981. Canine blastomycosis: A review of 47 clinical cases. *Journal of the American Veterinary Medical Association* 178: 1163-1168.
- MCDONOUGH, E. S., AND J. F. KUZMA. 1980. Epidemiological studies on blastomycosis in the state of Wisconsin. *Sabouraudia* 18: 173-183.
- MECH, L. D. 1974. Current techniques in the study of elusive wilderness carnivores. *Proceedings XIth International Congress of Game Biologists* 11: 315-322.
- , AND H. H. HERTEL. 1983. An eight-year demography of a Minnesota wolf pack. *Acta Zoologica Fennica* 174: 249-250.
- SAROSI, C. A., M. R. ECKMAN, S. P. DAVIES, AND W. F. LASKEY. 1979. Canine blastomycosis as a harbinger of human disease. *Annals of International Medicine* 91: 733-735.
- SCHLOSSER, W. D. 1980. Canine blastomycosis in Minnesota. M.S. Thesis. University of Minnesota, Minneapolis, Minnesota, 54 pp.
- STROUD, R. K., AND E. M. COLES. 1980. Blastomycosis in an African lion. *Journal of the American Veterinary Medical Association* 177: 842-844.
- THIEL, R. P., AND S. H. FRITTS. 1983. Chewing-removal of radio-collars by gray wolves in Wisconsin. *Journal of Wildlife Management* 47: 851-852.
- TURNER, S., L. KAUFMAN, AND M. JALBERT. 1986. Diagnostic assessment of an enzyme-linked immunosorbent assay for human and canine blastomycosis. *Journal of Clinical Microbiology* 23: 294-297.

Received for publication 8 July 1986.