

MYCOBACTERIOSIS IN CULTURED STRIPED BASS FROM CALIFORNIA

Authors: Hedrick, R. P., McDowell, T., and Groff, J.

Source: Journal of Wildlife Diseases, 23(3) : 391-395

Published By: Wildlife Disease Association

URL: <https://doi.org/10.7589/0090-3558-23.3.391>

BioOne Complete (complete.BioOne.org) is a full-text database of 200 subscribed and open-access titles in the biological, ecological, and environmental sciences published by nonprofit societies, associations, museums, institutions, and presses.

Your use of this PDF, the BioOne Complete website, and all posted and associated content indicates your acceptance of BioOne's Terms of Use, available at www.bioone.org/terms-of-use.

Usage of BioOne Complete content is strictly limited to personal, educational, and non - commercial use. Commercial inquiries or rights and permissions requests should be directed to the individual publisher as copyright holder.

BioOne sees sustainable scholarly publishing as an inherently collaborative enterprise connecting authors, nonprofit publishers, academic institutions, research libraries, and research funders in the common goal of maximizing access to critical research.

MYCOBACTERIOSIS IN CULTURED STRIPED BASS FROM CALIFORNIA

R. P. Hedrick, T. McDowell, and J. Groff

Aquaculture and Fisheries Program, Department of Medicine, School of Veterinary Medicine, University of California, Davis, California 95616, USA

ABSTRACT: Striped bass (*Morone saxatilis*) juveniles raised in an intensive culture system had chronic mortality resulting from infections with *Mycobacterium marinum*. Approximately one-half of a population of 900 yearlings succumbed to the disease and 80% of those remaining were infected. The bacteria were isolated on Petrignani's medium after 7 days at 25 C and subcultures grew at temperatures from 20 to 37 C. The disease was characterized by systemic nodular lesions in all major organs. Older tubercles contained numerous acid-fast bacilli. Chemotherapy by feeding rifampin (6 mg/100 g of food for 60 days) was not an effective treatment. Subclinical mycobacteriosis in adult striped bass may be the source for vertical transmission to their progeny.

Key words: Mycobacteriosis, striped bass, *Mycobacterium marinum*, aquaculture, *Morone saxatilis*.

INTRODUCTION

Striped bass (*Morone saxatilis*), since their introduction from the eastern United States in 1879 and 1881 (Boyle, 1980), have become a popular sport fish in the Sacramento and San Joaquin river systems in California. They are currently the focus of aquaculture programs that will provide more fish for sportfishing and to sell as food fish. Difficulties in rearing larvae and diseases are the major problems associated with culturing this species.

The reasons for the decline in feral populations are unknown, but adult striped bass undergo seasonal periods of high mortality (Kohlhorst, 1975). The suspected causes are pollution, temperature stress and diseases due to microbial pathogens (Sakanari et al., 1983; Coutant, 1986).

Mycobacteria are common pathogens of many vertebrates (Good, 1985), including fish (Parisot, 1970). Nigrelli and Vogel (1963) reported mycobacteriosis in striped bass maintained in an aquarium. More recently, Sakanari et al. (1983) found subclinical mycobacterial infections in feral adult striped bass from the Sacramento and San Joaquin rivers. Mycobacteriosis was common in Pacific salmon in the western United States, but discontinuing the feeding of raw adult carcasses to young fish and the use of pasteurized fish meal in diets

substantially reduced the prevalence of this disease (Parisot and Wood, 1960).

The present study describes an outbreak of systemic mycobacteriosis in cultured striped bass reared as part of a state sponsored program to rehabilitate their diminishing numbers in the Sacramento and San Joaquin estuaries of northern California.

MATERIALS AND METHODS

Striped bass with mycobacteriosis were submitted to the Fish Pathology Diagnostic Laboratory, University of California, Davis, California. Additional fish from the same population were obtained directly from a private farm located near Sacramento, California. The fish were approximately 8 mo old with an average mean weight of 0.80 ± 0.05 kg and were reared in 5 m concrete circular tanks receiving 22 C well water. These bass were being held as potential broodstock after a majority had been released into the delta and bay as part of a state program to increase their numbers in the Sacramento and San Joaquin river systems.

Fish were swabbed on the ventral surface with tincture of iodine and opened with a sterile scalpel. Bacterial isolations were made directly from the kidney, spleen and livers of 10 fish by removing tissue with a sterile loop. The inocula were spread on both brain heart infusion (BHI) and Petrignani's agar (Grand Island Biological Company, Grand Island, New York 14072, USA) and incubated at 25 C. Smears from the same tissues were prepared on glass microscope slides, air dried, heat-fixed and duplicate slides stained with Gram's or Ziehl-Neelsen acid-fast reagents.

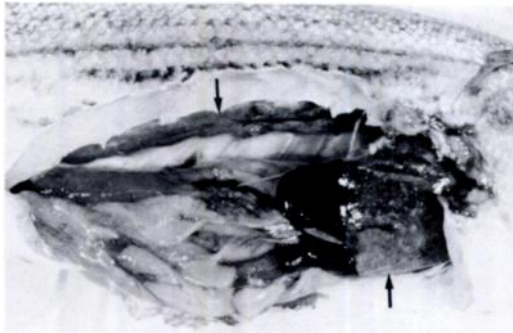


FIGURE 1. Granulomatous lesions (arrows) in liver and discolored kidney of a striped bass with mycobacteriosis.

Tissues from infected fishes, including kidney, liver, spleen, gill, heart and intestine, were placed into Davidson's fixative (Humason, 1979) for 12 hr and transferred to 70% ethanol for routine histological processing, embedded in paraffin, sectioned at 5 μ m, and stained with hematoxylin and eosin or Ziehl-Neelsen acid-fast reagent.

Subcultures from the original bacterial isolations were tested for growth at 20, 25, 30 and 37 C on Petragnani's medium. The color of the colonies both exposed and unexposed to light and the rapidity of growth at the selected temperatures were used in the preliminary identification of the organism. Species confirmation of the bacterium was made by biochemical tests as described by Wayne and Kubica (1986).

RESULTS AND DISCUSSION

Chronic mortalities of yearling striped bass at a private culture facility resulted from a systemic granulomatous disease caused by *Mycobacterium marinum*. During a 6-mo-period approximately one-half of the total population of 900 fish died. Most fish had systemic mycobacterial infections based on gross signs in internal organs. Usually, there were no external clinical signs in dead fish, other than emaciation. However, several specimens had small blisters to shallow ulcerations in the epidermis. All of the fish with these cutaneous lesions were infected, and had numerous nodular lesions in the kidney, liver and spleen (Fig. 1).

Histologically, tubercles in all stages of

development were present. Soft tuberculous lesions had a center filled with caseous necrotic material and acid-fast bacilli surrounded by a sheath of epithelioid cells (Fig. 2). Younger tubercles were hard and did not have a defined epithelioid sheath or central necrosis (Fig. 2). Lesions with both types of tubercles are typical of the proliferative form of the disease, but calcification of older tubercles and the presence of giant cells are not typical of piscine tuberculosis (Wolke and Stroud, 1978; Majeed et al., 1981). Additionally, large numbers of the bacteria were evident in tubercles from the striped bass (Fig. 2). In contrast, there are usually few or no bacilli observed in mammalian mycobacteriosis (Wolke and Stroud, 1978).

The organisms were easily cultured from affected tissues on Petrignani's medium and BHI. There was noticeable growth after 5 to 7 days at 25 C upon primary isolation and with subcultures at 3 to 5 days. The colonies were typically rough and yellow in appearance. Numerous organisms were observed also in smears from internal organs. They had a banded or beaded appearance and ranged in size from 0.3 to 0.5 \times 1.0 to 1.5 μ m. Longer rods up to 7 μ m were seen also in stained smears from infected fish. Growth of the bacterium following subculture was examined at 20, 25, 30, and 37 C. The isolate grew at the three lower temperatures at 3 to 5 days and at 7 days at 37 C. Because it had rapid growth at the lower temperatures and it was pigmented and acid-fast, the organism was suspected to be *M. marinum*. This was confirmed by the biochemical tests as shown in Table 1. Although *M. marinum* is grouped with the slower growing mycobacteria (≥ 7 days for noticeable growth), the isolate in our study grew somewhat more rapidly. However, Wayne and Kubica (1986) indicated that some overlap or intermediate growth rates may be observed in certain strains. This may explain the disparity in the growth of the isolate

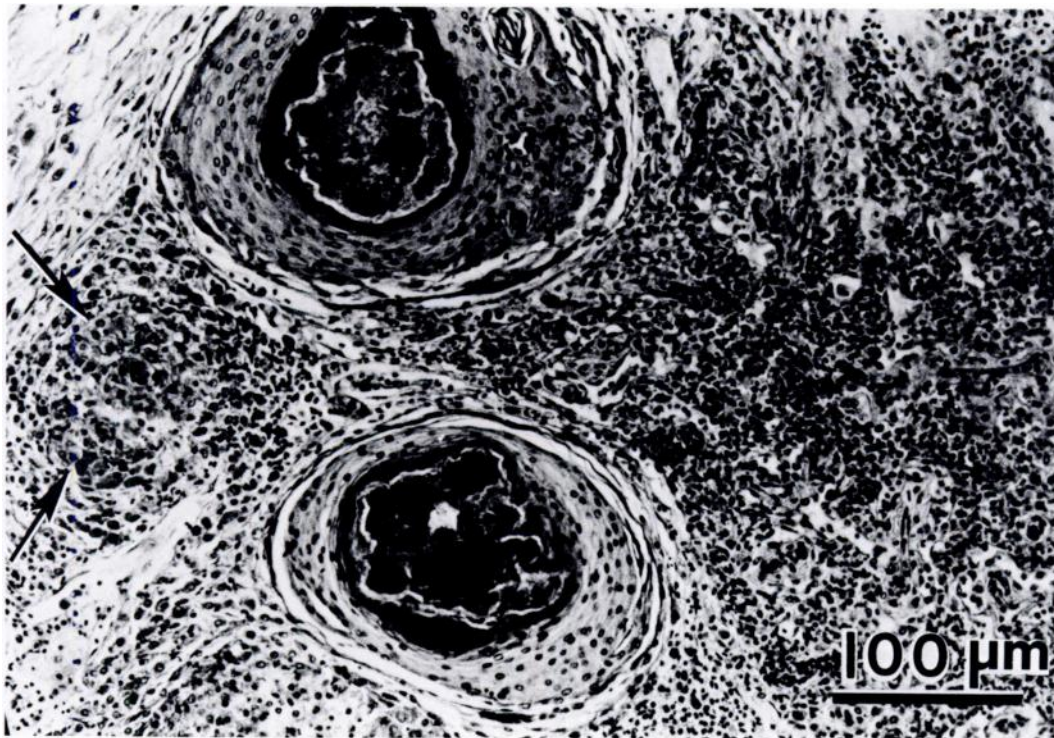


FIGURE 2. Splenic granulomatous lesions of *Mycobacterium marinum* in striped bass illustrating soft tubercles with necrotic centers and a hard tubercle (arrows), H & E.

from striped bass compared to those in previous reports.

Following diagnosis of the disease, we attempted to control the fish mortality with chemotherapy. Because of the large volume of water, treatment by bath exposures with isoniazid or kanamycin (Dulin, 1976; Santacana et al., 1982) was discounted. Instead, rifampin was administered in the feed (6 mg/100 g of food, fed for 60 days) as suggested by Dulin (1976). After treatment, 10 fish netted from the approximately 450 remaining in the population were examined for gross and microscopic evidence of infection. Additionally, kidney tissues from each fish were cultured on Petraghani's medium incubated at 25 C.

Eight of the 10 fish had gross clinical signs of infection and *M. marinum* was cultured from 5 kidney samples. Because

of the apparent inefficacy of rifampin treatment, the remaining population was incinerated and the culture tanks were sterilized with 200 ppm chlorine for 3 days and then air-dried.

The source of *M. marinum* detected in striped bass in this study is unknown. An examination of the same population 4 mo prior to the first mortality showed no indication of infection and the fish were cleared for liberation. Approximately 900 of these fish were held for potential freshwater broodstock. It was in this group that mortality was detected. These fish were progeny of feral adults from the Sacramento River that were artificially spawned earlier in the previous year. Unfortunately, these adults were not examined for mycobacteria. Although Parisot (1970) failed to transmit the organism to Pacific

TABLE 1. Biochemical properties of mycobacterial isolate from striped bass.

Test	Result
Pigment production at 37 C	2+
Urease	+
Thiopen-2-carboxylic acid hydrazide sensitivity (1 µg/ml)	+
Nitrate reduction	-
Catalase	-
Tween hydrolysis	+
Arylsulfatase	2+ (3 days), 3+ (14 days)
Pyrazinamidase	+

salmon by introducing it with the milt at spawning, several investigators have suggested that vertical transmission from adult to progeny does occur (Nigrelli and Vogel, 1963; Conroy, 1966; Ashburner, 1977). However, Arakawa and Fryer (1984) have shown that *M. chelonae*, the principal mycobacteria species found in Pacific salmon, is different from the organism described by Ashburner (1977). The latter author proposed that the organism observed in mycobacteriosis epizootics in Pacific salmon from Australia had resulted from the import of eggs from infected North American broodstock.

Sakanari et al. (1983) reported subclinical infections in adult striped bass from the Sacramento and San Joaquin rivers in California and the Coos River in Oregon. Whether these adults can act as carriers or transmit the disease to their progeny is unknown. The isolate obtained from adult striped bass does show similar growth, colony morphology or pigmentation to the *M. marinum* isolated in our study (R. P. Hedrick, unpubl. data). If adult fish are the source of the infection, the disease may have only become fulminate as a result of the intensive culture system. Under these crowded conditions transmission through the water, fecal products, or by feeding on dead fish may have resulted in the high

prevalence and subsequent mortality. We are currently examining the pathogenesis of the disease following experimental infections by water-borne exposures and injections of *M. marinum* into juvenile striped bass. Additional studies on the disease in striped bass in salt water are planned. This should provide further information regarding the potential significance of the disease on the survival of cultured striped bass released for mitigation purposes.

ACKNOWLEDGMENTS

This work is a result of research sponsored in part by NOAA, National Sea Grant College Program, Department of Commerce, under grant number NA85AA-D-SG140, Project R/F-100, through the California Sea Grant College Program. The U.S. Government is authorized to reproduce and distribute information contained herein for governmental purposes. We would like to thank Anita Wong for her helpful advice.

LITERATURE CITED

- ARAKAWA, C. K., AND J. L. FRYER. 1984. Isolation and characterization of a new subspecies of *Mycobacterium chelonae* infectious for salmonid fish. *Helgolander Meeresunters* 37: 329-342.
- ASHBURNER, L. D. 1977. Mycobacteriosis in hatchery-confined chinook salmon (*Oncorhynchus tshawytscha*) Walbaum, in Australia. *Journal of Fish Biology* 10: 523-528.
- BOYLE, R. H. 1980. *Bass*. Norton and Company, Inc., New York, New York, 160 pp.
- CONROY, D. A. 1966. Observaciones sobre casos espontaneos-de tuberculosis ictica. *Microbiologia Espana* 19: 93-113.
- COULTANT, C. C. 1986. Thermal niches of striped bass. *Scientific American* 32: 98-104.
- DULIN, M. P. 1976. A review of tuberculosis (mycobacteriosis) in fish. *Veterinarian, Small Animal Clinician* May 1979: 731-735.
- GOOD, R. C. 1985. Opportunistic pathogens in the genus *Mycobacterium*. *Annual Reviews of Microbiology* 39: 347-369.
- HUMASON, G. L. 1979. *Animal tissue techniques*. W. H. Freeman and Co., San Francisco, California, 661 pp.
- KOHLHORST, D. W. 1975. The striped bass (*Morone saxatilis*) die-off in the Sacramento-San Joaquin estuary in 1973 and a comparison of its characteristics with those of the 1971 and 1972 die-offs.

- California Department of Fish and Game, Anadromous Fisheries Branch Administrative Report 73-7, Sacramento, California, 21 pp.
- MAJEED, S. K., C. GOPINATH, AND D. W. JOLLY. 1981. Pathology of spontaneous tuberculosis and pseudotuberculosis in fish. *Journal of Fish Diseases* 4: 507-512.
- NIGRELLI, R. F., AND H. VOGEL. 1963. Spontaneous tuberculosis in fishes and in other cold blooded vertebrates with special reference to *Mycobacterium fortuitum* Cruz from fish and human lesions. *Zoologica* 48: 131-144.
- PARISOT, T. J. 1970. Fish mycobacteriosis (tuberculosis). Fish Disease Leaflet No. 7. United States Fish and Wildlife Service, Department of the Interior, Washington, D.C., 2 pp.
- , AND E. M. WOOD. 1960. A comparative study of the causative agent of a mycobacterial disease of salmonid fishes. II. A description of the histopathology of the disease in chinook salmon (*Oncorhynchus tshawytscha*) and a comparison of the strain characteristics of the fish disease with leprosy and human tuberculosis. *American Review of Respiratory Diseases* 82: 212-222.
- SAKANARI, J. A., C. A. REILLY, AND M. MOSER. 1983. Tubercular lesions in Pacific coast populations of striped bass. *Transactions of the American Fisheries Society* 112: 565-566.
- SANTACANA, J. A., D. A. CONROY, M. E. MUJICA, C. MARIN, AND N. DE LOPEZ. 1982. Acid-fast bacterial infection and its control in three-spot gouramies, *Trichogaster trichopterus* Pallas. *Journal of Fish Diseases* 5: 545-547.
- WAYNE, L. G., AND G. P. KUBICA. 1986. The mycobacteria. In *Bergey's manual of systemic bacteriology*, Vol. 2, Peter H. A. Sneath (ed.). Williams and Wilkins, Baltimore, Maryland, pp. 1440.
- WOLKE, R. E., AND R. K. STROUD. 1978. Piscine mycobacteriosis. In *Mycobacterial infections of zoo animals*, R. J. Montali (ed.). Symposia of the National Zoological Park, Smithsonian Institution Press, Washington, D.C., pp. 269-275.

Received for publication 8 October 1986.