

MASS STRANDING OF ODONTOCETI CAUSED BY PARASITOGENIC EIGHTH CRANIAL NEUROPATHY

Authors: T. Morimitsu, T. Nagai, M. Ide, H. Kawano, A. Naichuu, et. al.

Source: Journal of Wildlife Diseases, 23(4) : 586-590

Published By: Wildlife Disease Association

URL: <https://doi.org/10.7589/0090-3558-23.4.586>

BioOne Complete (complete.BioOne.org) is a full-text database of 200 subscribed and open-access titles in the biological, ecological, and environmental sciences published by nonprofit societies, associations, museums, institutions, and presses.

Your use of this PDF, the BioOne Complete website, and all posted and associated content indicates your acceptance of BioOne's Terms of Use, available at www.bioone.org/terms-o-use.

Usage of BioOne Complete content is strictly limited to personal, educational, and non - commercial use. Commercial inquiries or rights and permissions requests should be directed to the individual publisher as copyright holder.

BioOne sees sustainable scholarly publishing as an inherently collaborative enterprise connecting authors, nonprofit publishers, academic institutions, research libraries, and research funders in the common goal of maximizing access to critical research.

MASS STRANDING OF ODONTOCETI CAUSED BY PARASITOGENIC EIGHTH CRANIAL NEUROPATHY

T. Morimitsu,¹ T. Nagai,¹ M. Ide,¹ H. Kawano,¹ A. Naichuu,¹ M. Kono,² and A. Ishii³

¹ Department of Otorhinolaryngology, Miyazaki Medical College, Kiyotake, Miyazaki, 889-16 Japan

² Department of Second Pathology, Miyazaki Medical College, Kiyotake, Miyazaki, 889-16 Japan

³ Department of Parasitology, Okayama University School of Medicine, Shikatachou, Okayama, 700 Japan

ABSTRACT: Hearing organs of the Odontoceti from two mass strandings in 1983 and 1986 were examined histopathologically. In the 1983 stranding, two of three pilot whales (*Globicephala macrorhynchus*) were necropsied and numerous *Nasitrema* sp. were found close to the eighth cranial nerve (*nervus vestibulo cochlearis*) in both animals. Patchy degeneration of the eighth cranial nerve in and out of the modiolus of the cochlea was observed. In the 1986 stranding, five of 125 false killer whales (*Pseudorca crassidens*) were examined and numerous trematodes (*Nasitrema gondo*) were found in the tympanic cavities. Severe degeneration of the eighth cranial nerve was discovered and there were many trematode eggs in the nervous and surrounding tissues. Parasitogenic eighth neuropathy is proposed again as the cause of mass stranding of the Odontoceti.

Key words: Dolphin, Odontoceti, mass stranding, *Nasitrema gondo*, parasitogenic neuropathy, *Globicephala macrorhynchus*, *Pseudorca crassidens*, eighth cranial nerve.

INTRODUCTION

In 1982, one female of 125 mass-stranded dolphins (*Peponocephala electra*) was examined by us and many trematodes (*Nasitrema* sp.) were found in the tympanic cavities (Morimitsu et al., 1986). Histological examination of the cochlea revealed eighth cranial nerve degeneration and trematode eggs at the introitus of the internal ear canal. From the results obtained, we proposed that parasitogenic eighth cranial neuropathy was a possible cause of mass stranding of the Odontoceti. However, this proposed origin of mass stranding was not accepted without objection because our results were obtained from necropsy of only one animal from a mass stranding.

In 1983 and 1986, the authors investigated two additional instances of mass strandings of the Odontoceti at Miyazaki and Iki, Japan. In this paper, we discuss the histopathological findings in the ears of live mass-stranded dolphins and present additional evidence for the parasitogenic origin of mass stranding in the Odontoceti.

MATERIAL AND METHODS

The 1983 stranding

On the afternoon of 22 May 1983 about 12 pilot whales (*Globicephala macrorhynchus*)

came to the seashore and some of them stranded on Aoshima Beach, Miyazaki Prefecture, Japan (31°41'N, 131°29'E). Many surfers and fishermen tried to return them to the water, but three whales died on the beach of which one was lost by the flood tide. One pilot whale was necropsied at the beach about 20 hr after death, and the second whale was decapitated and the head was refrigerated and examined 3 days later at the Aoshima Fishery Laboratory. The tympano-periotic bones with the eighth cranial nerve were excised and fixed in 10% formalin. They were decalcified for over 6 wk, embedded in paraffin, serially sectioned and stained with hematoxylin and eosin, Bodian's, and Klüver-Barrera's stains.

The 1986 stranding

In the early morning of 16 September 1986, 125 false killer whales (*Pseudorca crassidens*) were found mass stranded at Tsutsugajou Beach of Iki Island, Nagasaki Prefecture, Japan (33°42'N, 129°44'W). According to our request by telephone, five of these were selected at random by the staff of the Ishida Fishermen's Union and the heads were stored in a freezer from 12 to 36 hr after death. On 30 September 1986, the tympano-periotic bones of the five false killer whales were extracted during the natural defrost and stored in 10% formalin. Eight tympano-periotic bones were decalcified for 2 wk, sectioned, and stained with hematoxylin and eosin and Klüver-Barrera's stains.

RESULTS

The 1983 stranding

At necropsy of the first pilot whale, numerous trematodes were found in the bi-




FIGURE 1. *Nasitrema gondo* (P) found near the eighth cranial nerve (N) of a mass-stranded dolphin.

lateral pterygoid air sinuses and in the tympanic cavities. The number of trematodes was >600 in one side. These were identified as *Nasitrema gondo*. The tympanic mucous membrane was edematous. A few squid beaks were found in the stomach, but the intestines were empty. Although nematodes (*Anisakis* sp.) found in

the stomach were alive, all trematodes (*N. gondo*) recovered from the air sinuses and tympanic cavities were dead. In the second pilot whale, numerous trematodes were found also in the tympanic cavities. Some were recovered from the internal auditory meatus near the eighth cranial nerve (Fig. 1) or from the oval and round windows.

Histopathological study of the periotic bones showed that the eighth cranial nerve in or near the modiolus had mosaically distributed severe degeneration. Ganglion cells connected to the degenerated nerve were decreased or had disappeared. Between the degenerated nerve fibers, normal nerve fibers and the ganglion cells were recognized. These findings indicate that the observed degeneration of the eighth cranial nerve was not a result of postmortem changes (Fig. 2). Bodian's and Klüver-Barrera's staining of the nerve fibers also indicated severe degeneration of both the

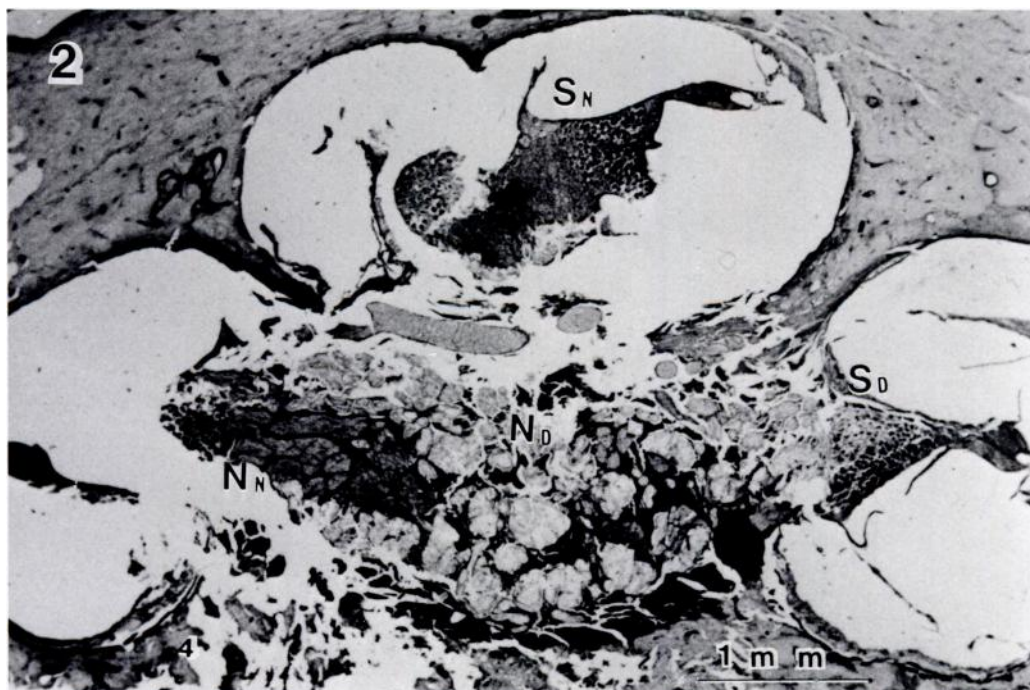

FIGURE 2. A high-power view of the cochlea of a pilot whale stranded in 1983. N_D indicates the area in which the nerve fibers were degenerated severely. N_N indicates the areas in which the nerve remained normal. S_D indicates the degenerated spiral ganglion and decreased numbers of ganglion cells. S_N indicates the spiral ganglion that remained normal. H&E.

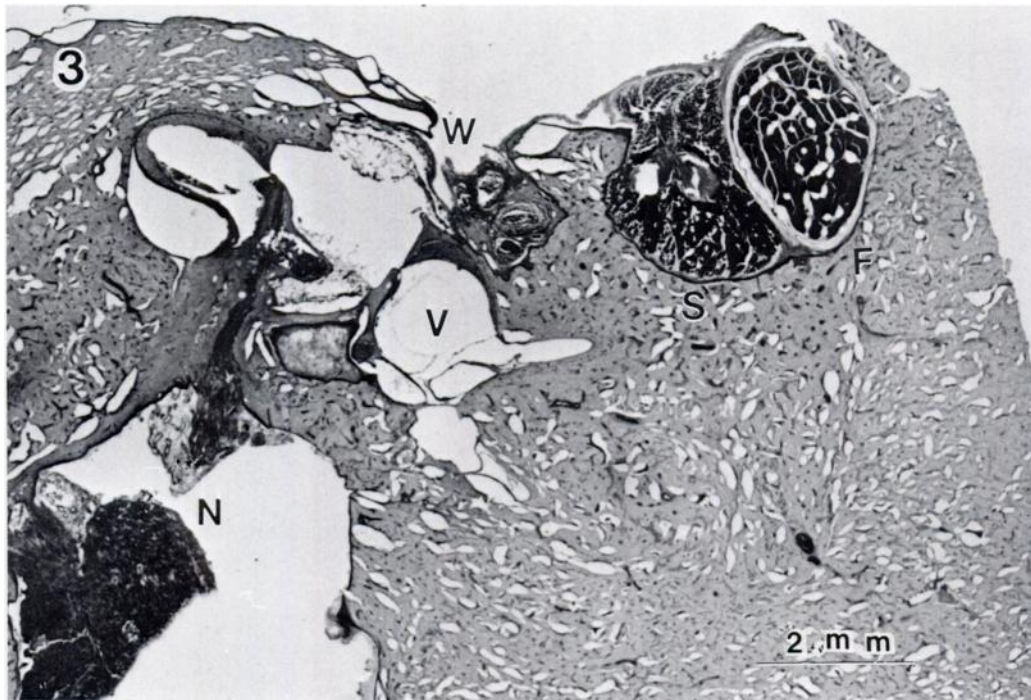


FIGURE 3. A low-power view of the periotic bone of a dolphin stranded in 1986: N, the eighth cranial nerve in the internal auditory meatus; F, the facial nerve in almost normal condition; S, the stapedial muscle; W, the oval window niche in which eggs were found as indicated in Figure 4; V, the vestibulum with no sign of labyrinthitis. H&E.

axon and sheath. The organ of Corti showed some degeneration attributable to autolysis but there were no signs of labyrinthitis. In the pilot whales, trematode eggs were not observed histologically. The above find-

ings were consistent with a parasitogenic eighth cranial neuropathy.

The 1986 stranding

In four false killer whales, 40–50 trematodes were found in the tympanic cavity. We were unable to record the number of parasites in one animal because they were very fragile due to postmortem degeneration. Many of the trematodes were localized in the cleft of the tympanic cavity. The eighth cranial nerves were fragile and extracted easily at the fundus of the internal acoustic meatus in all the animals. The tympanic mucous membrane showed few pathologic changes. The ossicles, the stapedial muscle, and the round window niche appeared almost normal. However, gelatinous fatty material, which is characteristic in the tympanum of the *Odonotoceti*, was absent.

In the histopathological studies of the cochlea, the eighth nerve in the modiolus

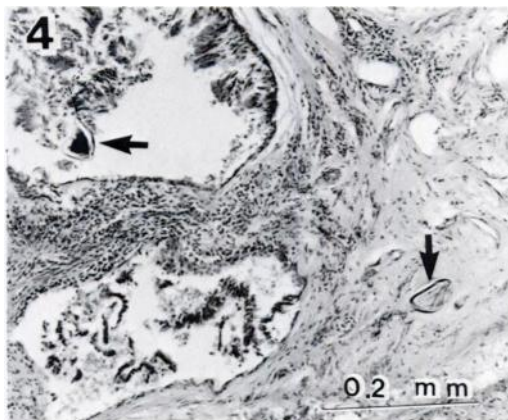


FIGURE 4. A high-power view of the oval window niche, where the eggs (arrows) were found.

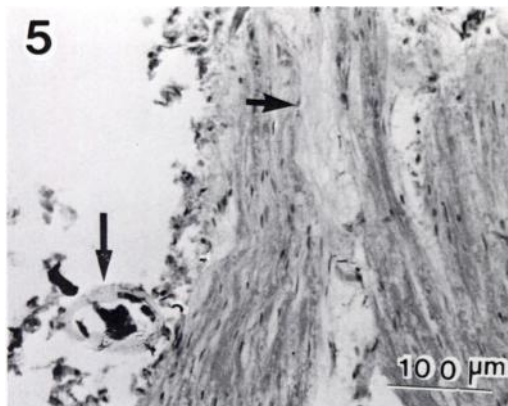


FIGURE 5. An egg found near the degenerated eighth cranial nerve; the large arrow indicates an egg and the small arrow indicates the severely degenerated area of the nerve. H&E.

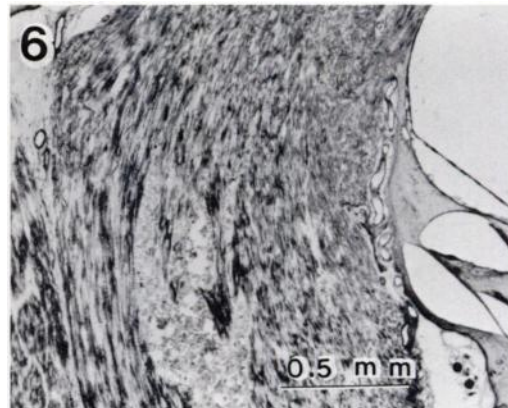


FIGURE 6. A high-power view of the eighth cranial nerve fiber in the modiolus showing nerve sheath degeneration. Klüver-Barrera's stain.

and the internal meatus showed severe degeneration in all animals, although the facial nerve and the stapedial muscle appeared more normal (Fig. 3). In three animals, trematode eggs were observed in the mucous membrane fold or in the submucous layer of the oval window (Fig. 4). There was a leukocytic infiltration around these eggs. In section, eggs were found near the degenerated eighth cranial nerve (Fig. 5). In the other two animals, eggs were not observed because the soft tissue around the periotic bone was stripped off completely before decalcification. The cranial nerve fiber stained with Klüver-Barrera's method showed patchy degeneration in the modiolis (Fig. 6). The spiral ganglion cells associated with degenerated nerve fibers were degenerated and decreased in number. Although the organ of Corti could not be found except for a few cells because of postmortem autolysis, there was no sign of labyrinthitis in the cochlea or the vestibulum. From the above results, we concluded that parasitogenic eighth cranial neuropathy was the cause of these two mass strandings of Odontoceti.

DISCUSSION

Certain previous studies support the theory that parasitism is responsible for single and/or mass strandings in the Odontoceti

(Ridgway and Dailey, 1972; Dailey and Walker, 1978). Alternatively, other reports (Neiland et al., 1970; Geraci, 1978; Walker and Cowan, 1981) propose other causes for single or mass strandings in these animals. However, there is no single unanimous explanation for single or mass strandings in these marine mammals.

In 1982, we studied a single female dolphin that had died during a mass stranding, and proposed parasitogenic eighth cranial neuropathy as a possible cause for mass stranding in the Odontoceti (Morimitsu et al., 1986). Because the histological study involved only one animal, there remained an objection to the universality of our new theory on the cause of mass strandings. Therefore, in the 1983 and 1986 strandings reported herein, we attempted to clarify whether or not the parasitogenic eighth cranial neuropathy was a common finding in stranded animals. In animals from 1983 and 1986 strandings, many parasites were found in the tympanic cavity and very close to the eighth cranial nerve. In the 1986 stranding, trematode eggs were found near the degenerated nerve. These findings indicate that adult helminths infected the eighth cranial nerve and deposited their eggs. Histological examination revealed degeneration of the eighth

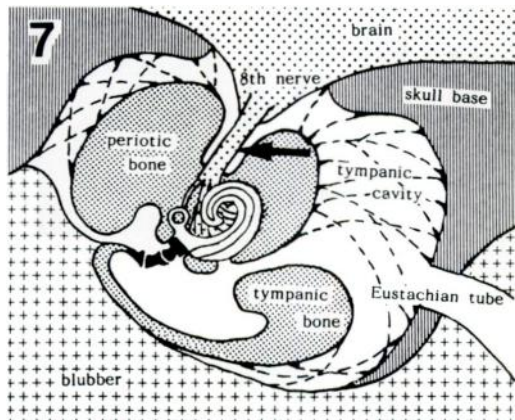


FIGURE 7. Anatomical characteristics of the hearing organ of the Odontoceti; the arrow indicates the location where the trematodes can infect the eighth cranial nerve (modified from Fleischer, 1982).

cranial nerve in the cochlea of all animals examined in this study.

Fleischer (1982) reported that one of the anatomical characteristics of the ear of the Odontoceti is complete separation of the tympano-periotic bone from the skull base. Apparently, this helps the animal to avoid the influence of the strong ultrasonic sound which is used for echolocation. As shown in Figure 7, the eighth cranial nerve extends from the brain stem to the labyrinth without an osseous cover in the tympanic cavity allowing easy access by the trematodes, and resulting in the subsequent pathology to the eighth cranial nerve. For the precise echolocation, the bilateral hearing organs must fulfill their function equally. If one ear completely or partially loses its function, the animal cannot detect the location of a sound source precisely and quickly. In our study of 1986 stranding, bilateral cochleas of three animals and unilateral cochleas of two animals were examined. There were varying degrees of eighth cranial nerve damage in all these animals resulting from infection with *N. gondo*. Therefore, we believe that our study is sufficient to demonstrate a parasitogenic-induced echolocative dysfunction in this mass stranding of 1986. Odontoceti that have lost their echolocative

function cannot catch food and are compelled to strand because of hunger and exhaustion. In addition, the loss of vestibular function may cause them to enter the calm bays and shallow water.

Results of our previous study (Morimitsu et al., 1986) and the present study on three mass strandings involving three species of the Odontoceti indicate that parasitogenic eighth cranial neuropathy is a common occurrence in these marine mammals. We believe that the resulting echolocation dysfunction is a major cause of mass stranding in these animals.

ACKNOWLEDGMENTS

We thank the staff of the Miyazaki Prefectural Fishery Institute and T. Sumiyoshi of the Ishida Fishermen's Union for assistance in obtaining specimens. Appreciation is extended also to G. Fleischer of the Giessen University, James G. Mead of the Division of Mammals at the Smithsonian Institution, and Daniel K. Odell of the Rosensteil School of Marine and Atmospheric Sciences, University of Miami.

LITERATURE CITED

- DAILEY, M. D., AND W. A. WALKER. 1978. Parasitism as a factor(?) in single strandings of southern California cetaceans. *The Journal of Parasitology* 64: 593-596.
- FLEISCHER, G. 1982. Hörmechanismus bei Delphinen und Walen. *Hals, Nasen, Ohren* 30: 123-130.
- GERACI, J. R. 1978. The enigma of marine mammal stranding. *Oceanus* 21: 38-47.
- MORIMITSU, T., T. NAGAI, M. IDE, A. ISHII, AND M. KOONO. 1986. Parasitogenic octavus neuropathy as a cause of mass stranding of Odontoceti. *The Journal of Parasitology* 72: 469-472.
- NEILAND, K. A., D. W. RICE, AND B. L. HOLDEN. 1970. Helminths of marine mammals. 1. The genus *Nasitrema*, air sinus flukes of delphinid Cetacea. *The Journal of Parasitology* 56: 305-316.
- RIDGWAY, S. H., AND M. D. DAILEY. 1972. Cerebral and cerebellar involvement of trematode parasites in dolphins and their possible role in stranding. *Journal of Wildlife Diseases* 8: 33-34.
- WALKER, W. A., AND D. F. COWAN. 1981. Air sinus parasitism and pathology in free ranging common dolphins (*Delphinus delphis*) in the eastern tropical Pacific. National Marine Fisheries Service, Southwest Fisheries Center Administrative Report Number LJ-81-23C, National Oceanic and Atmospheric Administration, Washington, D.C.

Received for publication 17 November 1986.