

## **Vibrio damsela Infection in a Stranded Leatherback Turtle (*Dermochelys coriacea*)**

Authors: Obendorf, D. L., Carson, J., and McManus, T. J.

Source: Journal of Wildlife Diseases, 23(4) : 666-668

Published By: Wildlife Disease Association

URL: <https://doi.org/10.7589/0090-3558-23.4.666>

---

BioOne Complete ([complete.BioOne.org](https://complete.BioOne.org)) is a full-text database of 200 subscribed and open-access titles in the biological, ecological, and environmental sciences published by nonprofit societies, associations, museums, institutions, and presses.

Your use of this PDF, the BioOne Complete website, and all posted and associated content indicates your acceptance of BioOne's Terms of Use, available at [www.bioone.org/terms-of-use](https://www.bioone.org/terms-of-use).

Usage of BioOne Complete content is strictly limited to personal, educational, and non - commercial use. Commercial inquiries or rights and permissions requests should be directed to the individual publisher as copyright holder.

---

BioOne sees sustainable scholarly publishing as an inherently collaborative enterprise connecting authors, nonprofit publishers, academic institutions, research libraries, and research funders in the common goal of maximizing access to critical research.

## ***Vibrio damsela* Infection in a Stranded Leatherback Turtle (*Dermochelys coriacea*)**

D. L. Obendorf,<sup>1</sup> J. Carson,<sup>1,2</sup> and T. J. McManus,<sup>1</sup> <sup>1</sup> Tasmanian Department of Agriculture, Mt. Pleasant Laboratories, P.O. Box 46, Launceston South, 7249, Tasmania, Australia. <sup>2</sup> Author to whom correspondence should be addressed

**ABSTRACT:** Necropsy of a stranded adult leatherback turtle (*Dermochelys coriacea*) determined that the animal died as a result of valvular endocarditis and septicemia. *Vibrio damsela* was isolated from the endocardial thrombus. The route of entry for infection probably was through the gastrointestinal tract.

**Key words:** Leatherback turtle, *Dermochelys coriacea*, *Vibrio damsela* infection, case report.

Marine bacteria of the genus *Vibrio* are incriminated frequently in mortality of crustaceans, teleost fish and shellfish, particularly when adverse environmental conditions, nutritional deprivations or overcrowding are experienced (Ghittino et al., 1984). Apart from opportunistic wound infections in captive-reared green turtles (*Chelonia mydas*) in northern Queensland (Glazebrook et al., 1981), we are not aware of records of *Vibrio* sp. infection in marine chelonians. In this case report we present the history and necropsy findings of a stranded leatherback turtle infected with *Vibrio damsela*.

A female leatherback turtle 1.86 m in length was found dead, stranded in shallow water at the mouth of the Scamander River on the eastern coast of Tasmania (148°16'E and 41°27'S) on the morning of 25 February 1986. The turtle had been observed drifting on its back in the river mouth the previous afternoon. The body was sent directly to Mt. Pleasant Laboratories (Launceston, Tasmania, Australia) for necropsy examination.

External measurements were recorded and the identification of the turtle confirmed at the Queen Victoria Museum (Launceston, Tasmania, Australia). Tissue specimens for histological examination were placed in neutral buffered 10% for-

mol-saline, embedded in paraffin and stained with hematoxylin and eosin. Barnacles present on the carapace, head and flippers were removed, fixed in 10% formal-saline, and sent to the School of Biological Sciences at the University of Sydney (New South Wales, Australia) for identification. Intestinal helminths were preserved similarly and sent to the University of Canterbury (Christchurch, New Zealand) for identification.

Heart blood, liver, an endocardial valve lesion and intestines were cultured on sheep blood agar (0.5% NaCl), nutrient agar (1% NaCl) and TCBS agar (Oxoid Ltd., Basingstoke, Hampshire, United Kingdom) and incubated aerobically at 20 C and 37 C. Cultures were examined at 24 and 48 hr. Intestinal lesions were also cultured on Sabouraud dextrose agar at 25 C.

Three species of barnacles were identified: *Platylepas coriacea*, a species specific to this turtle host and *Conchoderma virigatum* and *Lepas anatifera*, two species commonly found on a wide range of marine animals and objects.

The body cavity contained approximately 1 liter of blood-tinged fluid and the viscera was congested with dilated blood vessels over the intestinal mesentery. Numerous firm caseous to calcareous nodules ranging from 3 to 20 mm in diameter were present in the lung parenchyma. The lungs were congested, edematous and heavy. The tracheal mucosa was uniformly reddened with numerous focal hemorrhages. The liver was very congested with a roughened serosal surface. The esophagus and stomach contained large numbers of tunicate coelomates or salps (*Pyrosoma* sp.). In the distal third of the small intestine, diph-

theritic plaques were noted on the luminal edges of the reticulate or honey-combed mucosa. The tissue underlying the plaques appeared ulcerated and erythematous. The content in this section of small intestine was blood-tinged and fluid. Several undigested salps were present in the intestines. In the terminal small intestine and proximal part of the large intestine approximately 70 *Astrorhynchus renicapite* (Trematoda: Digenea) were found. These trematodes were not associated with the diphtheritic enteric lesions. The ovaries contained numerous yellow ovules in various stages of development and degeneration; the oviducts contained no ova. The heart contained a large yellow vegetative thrombus attached to the left atrioventricular valve and the interventricular wall (Fig. 1).

Histopathological examination was limited by the extent of autolysis. However, microscopic examination confirmed the diphtheritic enteritis with underlying mucosal ulceration, extensive bacterial colonization, fibrin exudation and infiltration of heterophil inflammatory cells into the submucosal tissues. Bacterial aggregates contained within thrombi were present in the submucosal blood vessels. The liver showed focal necrosis and inflammatory cell infiltrates around the periportal areas. A perihepatitis characterized by aggregates of bacteria in association with fibrin and inflammatory cells was present also. The large thrombus on the atrioventricular valve and endocardial wall also contained clusters of bacteria interspersed through the fibrin and cellular debris. The lung nodules consisted of fibrous encapsulated abscesses with caseous or mineralized central cores. A pyogenic membrane was present on the inner surface of the fibrous capsule. The etiology of these lung lesions was not determined.

*Vibrio damsela* was isolated from the heart blood, endocardial thrombus, liver and diphtheritic small intestinal lesions. Two colony types were recovered, a hemolytic form that grew at 37 C and a non-

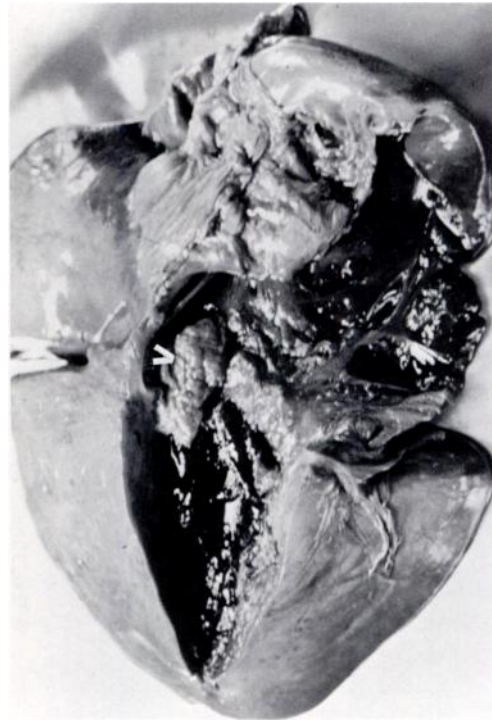


FIGURE 1. Heart of a leatherback turtle depicting the site of the large thrombus on the atrio-ventricular valve and endocardial wall (arrow).

hemolytic form that only grew at 30 C. No other pathogenic bacteria or fungi were isolated.

We concluded that this turtle died by drowning as a result of a pre-existing valvular endocarditis and septicemia. The extent of autolytic changes in the carcass and the report of the turtle floating on its dorsal carapace the afternoon prior to recovery suggested that the animal had been dead for at least 20–24 hr. The isolated bacteria, *V. damsela*, is a recognized pathogen of fish (Love et al., 1981), sharks (Grimes et al., 1984) and a wound pathogen in humans (Love et al., 1981; Morris et al., 1982). Other isolates of *V. damsela* from Africa and North America were derived from sewage, oysters and a skin wound in a raccoon (Farmer et al., 1985). In damselfish (*Chromis punctinnis*) the organism was isolated from ulcerated skin lesions (Love et al., 1981). In a brown shark (*Carcharhi-*

*nus plumbens*) which died in captivity, *V. damsela* was cultured from systemic sites, the major focus of which was the kidney (Grimes et al., 1984). *Vibrio damsela* is a highly virulent organism capable of producing large amounts of cytolytic toxin in vitro. Bacteriologically sterile preparations of partially purified toxin are known to be lethal to experimental mice after parenteral administration (Kreger, 1984).

The route of *V. damsela* infection in this stranded turtle may have been through the intestinal lesions with hematogenous spread to liver and heart. The vegetative endocarditis was sufficiently large to impede both valvular and myocardial function and thereby compromise the animal's cardiovascular system. The presence of large quantities of salps in the stomach and intestines suggested that the turtle had been feeding not long before death.

The importance of vibriosis as a mortality factor of the leatherback turtles is unknown. In the past 30 years there have been 10 sightings and strandings of leatherback turtles in Tasmania (Green, 1971). All sightings were in the summer and autumn months (December to May) from Tasmania's east and north coast. In these seasons the eastern Australian current commonly flows down into Tasmanian waters. The leatherback turtles occasionally follow this warm current, feeding predominantly on drifting jellyfish and Portuguese man-of-war (*Physalia physalis*).

We acknowledge the assistance of D. T. Anderson, School of Biological Sciences, the University of Sydney, New South Wales, Australia for his identification of the turtle barnacles; D. Blair, Zoology Department, University of Canterbury, Christchurch, New Zealand for identifying the intestinal trematodes; and Sandra

Smith, Sir Geroge Fisher Centre for Tropical Marine Studies, James Cook University, Townsville, Queensland, Australia for confirmation of the *Vibrio* isolates.

#### LITERATURE CITED

- FARMER, J. J. III, F. W. HICKMAN-BRENNER, AND M. T. KELLY. 1985. *Vibrio*. In Manual of clinical microbiology, 4th ed., E. H. Lennette, A. Balows, W. J. Hausler, Jr., and H. Jean Shadomy (eds.). American Society for Microbiology, Washington, D.C., pp. 282-301.
- GHITTINO, F., H. SCHWEDLER, AND P. DE KINKELIN. 1984. The principal infectious diseases of fish and their general control measures. In Symposium on fish vaccination, P. De Kinkelin (ed.). Publication Office Internationale des Epizootics, Paris, France, pp. 5-38.
- GLAZEBROOK, J. S., R. S. F. CAMPBELL, AND R. H. JOHNSON. 1981. Traumatic ulcerative dermatitis: A disease of captive sea turtles *Chelonia mydas* (L) in north-east Australia. In Wildlife diseases of the Pacific basin and other countries, M. E. Fowler (ed.). Fruitridge Printing, Sacramento, California, p. 160.
- GREEN, R. H. 1971. Sea turtles round Tasmania. Published by the Queen Victoria Museum, Launceston, Tasmania. [Records of the Queen Victoria Museum, No. 38.]
- GRIMES, D. J., J. STEMMLER, H. HADA, E. B. MAY, D. MANEUAL, F. M. HETRICK, R. T. JONES, M. STOSKOFF, AND R. R. COLWELL. 1984. *Vibrio* species associated with mortality of sharks held in captivity. Microbial Ecology 10: 271-282.
- KREGER, A. S. 1984. Cytolytic activity and virulence of *Vibrio damsela*. Infection and Immunity 44: 326-331.
- LOVE, M., D. TEEBKEN-FISHER, J. E. HOSE, J. J. FARMER III, F. W. HICKMAN, AND G. R. FANNING. 1981. *Vibrio damsela*, a marine bacterium, cause skin lesions on the damsel fish *Chromis punctipinnis*. Science 214: 1139-1140.
- MORRIS, J. G., JR., R. WILSON, D. G. HOLLIS, R. E. WEAVER, H. G. MILLER, C. O. TACKET, F. W. HICKMAN, AND P. A. BLAKE. 1982. Illness caused by *Vibrio damsela* and *Vibrio hollisae*. Lancet i: 1294-1297.

Received for publication 17 November 1986.