

Isolation of *Erysipelothrix rhusiopathiae* from a Red-tailed Hawk (*Buteo jamaicensis*) with a Concurrent Pox Virus Infection

Authors: L W. Pace, M. M. Chengappa, S. Greer, and C. Alderson

Source: Journal of Wildlife Diseases, 23(4) : 671-673

Published By: Wildlife Disease Association

URL: <https://doi.org/10.7589/0090-3558-23.4.671>

BioOne Complete (complete.BioOne.org) is a full-text database of 200 subscribed and open-access titles in the biological, ecological, and environmental sciences published by nonprofit societies, associations, museums, institutions, and presses.

Your use of this PDF, the BioOne Complete website, and all posted and associated content indicates your acceptance of BioOne's Terms of Use, available at www.bioone.org/terms-o-use.

Usage of BioOne Complete content is strictly limited to personal, educational, and non - commercial use. Commercial inquiries or rights and permissions requests should be directed to the individual publisher as copyright holder.

BioOne sees sustainable scholarly publishing as an inherently collaborative enterprise connecting authors, nonprofit publishers, academic institutions, research libraries, and research funders in the common goal of maximizing access to critical research.

Isolation of *Erysipelothrix rhusiopathiae* from a Red-tailed Hawk (*Buteo jamaicensis*) with a Concurrent Pox Virus Infection

L. W. Pace,¹ M. M. Chengappa,² S. Greer,² and C. Alderson,² ¹ Department of Pathology; and ² Department of Microbiology, Murray State University Breathitt Veterinary Center, P.O. Box 2000, Hopkinsville, Kentucky 42240, USA

ABSTRACT: *Erysipelothrix rhusiopathiae* was isolated from the spleen, liver, lung, heart, kidney, and skin of a red-tailed hawk (*Buteo jamaicensis*) which had a concurrent avian pox virus infection. The hawk had been housed on a farm with domestic turkeys, providing a possible source of the *E. rhusiopathiae*.

Key words: *Erysipelothrix rhusiopathiae*, pox virus, *Buteo jamaicensis*, red-tailed hawk, isolation, clinical case history.

A juvenile, male red-tailed hawk (*Buteo jamaicensis*) was submitted for necropsy to the Murray State University Breathitt Veterinary Center (Hopkinsville, Kentucky 42240, USA) on 13 October 1986. The hawk was presented to Kentucky Department of Fish and Wildlife Resources officials 3 days previously. Wildlife officials referred the bird to raptor rehabilitation personnel. At that time the bird was in an extremely emaciated condition with a severe external parasitic infection and numerous black, crusty, wart-like lesions on the feet and head. There was no visible evidence of trauma at the time of presentation. The hawk died 2 days later.

At necropsy numerous unidentified mites and lice were present on the carcass which was markedly emaciated, weighing 0.69 kg. The skin of both feet was thickened by multiple, multilobulated, dark brown to black, crusty masses ranging in size from a few mm to 2.0 cm in diameter (Fig. 1). Lesions were most prominent on the dorsal surfaces of the feet; however, they did extend between the toes and onto the plantar surfaces in some areas. The masses were covered with superficial, friable crusts which were easily removed and revealed underlying necrotic tissue. Similar lesions were present on the head, par-

ticularly at mucocutaneous junctions (Fig. 1). The left nostril was occluded totally by the lesions and the right nostril almost was occluded.

There were multiple, slightly raised, yellow-tan, 2 to 4 mm foci on the epicardium and on cut surfaces of the myocardium. Gross lesions were not observed in other tissues.

Samples of spleen, liver, kidney, lung, intestines, heart, and skin were submitted for bacteriological culture and were processed according to standard methods (Carter, 1984). Representative samples of skin lesions were submitted for examination for viral particles by transmission electron microscopy. The tissue specimens were inoculated onto tryptose soy agar containing 5% sheep blood and incubated in 6-8% CO₂ at 37 C for 48 hr. *Erysipelothrix rhusiopathiae* was isolated from the spleen, liver, lung, heart, kidney, and skin specimens. In addition, *Proteus* sp. and *Staphylococcus* sp. were isolated from the liver, skin, and heart. The cultures from intestinal samples revealed a mixed flora of *Escherichia coli* and *Proteus* sp. All bacterial isolates were identified according to standard procedures as described by Carter (1984). Antimicrobial susceptibility testing of *E. rhusiopathiae* was conducted using a standard method (Barry et al., 1970). The test revealed that the isolate was susceptible to ampicillin, erythromycin, nitrofurantoin, clindamycin, penicillin G, spectinomycin, and tetracycline but was resistant to gentamycin, kanamycin, neomycin, polymyxin B, streptomycin, sulfachloropyridazine, and trimethoprim/sulfamethoxazole.

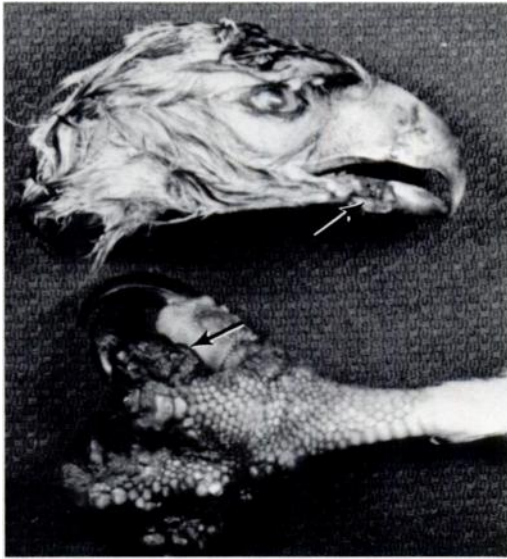


FIGURE 1. Raised, hyperkeratotic lesions of avian pox between toes and at mucocutaneous junction (arrows) of a red-tailed hawk.

The skin samples submitted for examination of viral particles by negative contrast electron microscopy revealed the presence of pox virus (Fig. 2). The skin samples for electron microscopy were prepared by a standard method (Alderson et al., 1986) and were examined on a 9S-2 Zeiss transmission electron microscope. Virus isolation was not attempted.

Histopathologic examination revealed multiple, discrete, randomly distributed foci of myocarditis characterized by separation and fragmentation of fibers, degeneration of fibers with loss of striation, and infiltration by heterophils and mononuclear inflammatory cells. In the atria the lesions sometimes extended through the entire thickness of the myocardium. In sections of liver and lung there were occasional small, discrete foci of necrosis with infiltration by heterophils and mononuclear inflammatory cells. Pulmonary lesions were usually adjacent to parabronchi. Similar necrotic and inflammatory foci were present multifocally in the lamina propria and submucosa of the proventriculus, small intestine and large intestine.

In sections of skin from the head and feet there was marked thickening of the epidermis caused by the proliferation of keratinocytes and swelling of individual cells. Many keratinocytes contained spherical, clear to eosinophilic, intracytoplasmic inclusions measuring 15 to 30 μm in diameter. The clear inclusions usually had a peripheral zone of eosinophilic staining. In many areas the epidermis was necrotic and was covered by serous exudate and cellular debris. The dermis and epidermis were multifocally infiltrated by heterophils, macrophages, and lymphocytes.

Erysipelothrix rhusiopathiae is a common pathogen of swine that causes acute septicemia, chronic proliferative and non-suppurative arthritis, or vegetative endocarditis (Wood, 1981). Erysipelas infection is reported in a variety of domestic fowl, game birds and other wild birds (Jensen and Cotter, 1976; Pettit et al., 1976; Whitman and Bickford, 1983; Rosenthal and Corstvet, 1984). To our knowledge, this report documents the first diagnosis of erysipelas in a red-tailed hawk (*Buteo jamaicensis*). This bird also had an avian pox virus infection. Avian pox is reported in numerous avian species (Tripathy and Cunningham, 1984).

The pathogenesis of the two diseases (pox and erysipelas) in this bird was intriguing.

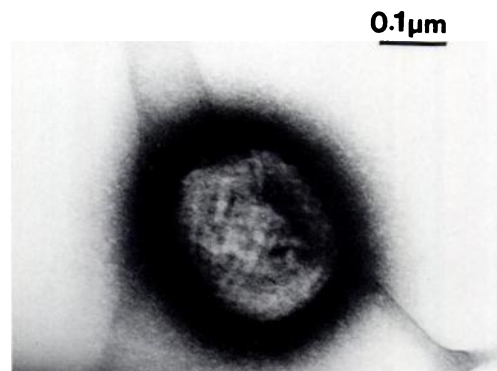


FIGURE 2. Negatively stained pox virus with randomly distributed surface tubules.

The complete history on this case was unattainable; however, the available history revealed that the hawk had been held in captivity and in close proximity to domestic turkeys. Improper feeding while in captivity is a possible cause of the poor body condition of the hawk. The source of the external parasites and the pox virus are unknown. Possible sources of exposure to the *E. rhusiopathiae* include the ingestion of infected porcine flesh as a scavenger, ingestion of infected wild rodents, or exposure from soil via the skin lesions caused by the pox virus infection. Although there was no history of disease caused by *E. rhusiopathiae* at the farm, we believe that the turkeys might have harbored the bacteria and transmitted the organisms to the hawk directly.

The authors wish to thank Doug Atkins and J. H. Davie for submission of this case.

LITERATURE CITED

- ALDERSON, C., H. K. WHITAKER, AND F. BYERS. 1986. Use of negative contrast electron microscopy on animal tissues in the diagnosis of animal diseases. *American Association of Veterinary Laboratory Diagnosticians, 29th Annual Proceedings*, pp. 317-334.
- BARRY, A. L., F. GARCIA, AND L. D. THRUPP. 1970. An improved single disk method for testing the antimicrobial susceptibility of rapidly growing pathogens. *American Journal of Clinical Pathology* 53: 149-158.
- CARTER, G. R. 1984. *Diagnostic procedures in veterinary bacteriology and mycology*, 4th ed. Charles C Thomas Books, Springfield, Illinois, 198 pp.
- JENSEN, W. I., AND S. E. COTTER. 1976. An outbreak of erysipelas in eared grebes (*Podiceps nigricollis*). *Journal of Wildlife Diseases* 12: 583-586.
- PETTIT, J. R., A. W. GOUGH, AND R. B. TRUSCOTT. 1976. *Erysipelothrix rhusiopathiae* infection in chukar partridge (*Alectoris graeca*). *Journal of Wildlife Diseases* 12: 254-255.
- ROSENTHAL, A. S., AND R. E. CORSTVET. 1984. Erysipelas. *In Diseases of poultry*, 8th ed., M. S. Hofstad (ed.). Iowa State University Press, Ames, Iowa, pp. 232-241.
- TRIPATHY, D. N., AND C. H. CUNNINGHAM. 1984. Avian pox. *In Diseases of poultry*, 8th ed., M. S. Hofstad (ed.). Iowa State University Press, Ames, Iowa, pp. 524-534.
- WHITEMAN, C. E., AND A. A. BICKFORD. 1983. Avian disease manual, 2nd ed. The American Association of Avian Pathologists, University of Pennsylvania, Kennett Square, Pennsylvania, pp. 83-85.
- WOOD, R. L. 1981. Erysipelas. *In Diseases of swine*, 5th ed., A. D. Leman, R. P. Glock, W. L. Mengeling, R. H. C. Penny, E. Scholl, and B. Straw (eds.). Iowa State University Press, Ames, Iowa, pp. 457-470.

Received for publication 24 February 1987.