

Severed Intestine in Channel Catfish

Authors: Robert M. Durborow, and Larry Hanson

Source: Journal of Wildlife Diseases, 24(1) : 146-149

Published By: Wildlife Disease Association

URL: <https://doi.org/10.7589/0090-3558-24.1.146>

BioOne Complete (complete.BioOne.org) is a full-text database of 200 subscribed and open-access titles in the biological, ecological, and environmental sciences published by nonprofit societies, associations, museums, institutions, and presses.

Your use of this PDF, the BioOne Complete website, and all posted and associated content indicates your acceptance of BioOne's Terms of Use, available at www.bioone.org/terms-o-use.

Usage of BioOne Complete content is strictly limited to personal, educational, and non - commercial use. Commercial inquiries or rights and permissions requests should be directed to the individual publisher as copyright holder.

BioOne sees sustainable scholarly publishing as an inherently collaborative enterprise connecting authors, nonprofit publishers, academic institutions, research libraries, and research funders in the common goal of maximizing access to critical research.

Severed Intestine in Channel Catfish

Robert M. Durborow¹ and Larry Hanson,^{2,3} ¹ Department of Wildlife and Fisheries, Mississippi Cooperative Extension Service, P.O. Box 142, Stoneville, Mississippi 38776, USA; ² Alabama Fish Farming Center, Greensboro, Alabama 36744, USA. ³ Present address: Department of Veterinary Microbiology, Louisiana State University, Baton Rouge, Louisiana 70803, USA

ABSTRACT: Six cases of severed intestines in farm-raised channel catfish were examined at fish disease diagnostic laboratories in Mississippi and Alabama. This condition has not been reported previously in fish. Affected fish had a 4–7-cm-long intestinal section (hyperemic where it was severed) attached to the stomach. The remainder of the intestine was completely missing in all six cases except for a 1–1.5-cm section of intestine prolapsed from the anus in fish from three of the cases. Ischemia, autodigestion following intussusception, or intestinal epithelium degradation are suggested as possible etiologies for this condition.

Key words: Severed intestine, prolapsed intestine, intussusception, channel catfish, *Ictalurus punctatus*, fish farming, case report.

Reports of severed intestines in vertebrates are rare, and they are non-existent for fish. Intestinal rupture was reported in a sambar deer (*Cervus unicolor*) by Bhattacharjee and Franzmann (1986). Perforated intestines have been observed in human fetuses (Tibboel et al., 1986).

In the present case report, severed intestines are described in farm-raised channel catfish. Four cases involving channel catfish (*Ictalurus punctatus*) with severed intestines were submitted to the Mississippi Cooperative Extension Service Fish Disease Diagnostic Laboratory (Delta Branch Experiment Station, Stoneville, Mississippi 38776, USA) and two cases were submitted to the diagnostic facility at the Alabama Fish Farming Center (Greensboro, Alabama 36744, USA) (Table 1). Fish from five of these cases were captured alive. Fish in all six cases had severed intestines with only a short section of intestine (approximately 4–7 cm long and hyperemic at the point of severing) attached to the stomach (Fig. 1). The remainder of the intestine was completely missing in all six cases except for a 1–1.5-cm section of in-

testine prolapsed from the anus in fish from three of the cases (Table 1).

The clinical presentations for each case are in Table 1. All mortality estimates were made by fish farmers submitting the diseased fish. The diseased fish were from ponds (4.5–8 ha in size) stocked with 39,000–180,000 fish. Sample size ranged from one to six fish. From a sample of six moribund fish examined in one case, only one had a severed intestine. In two other cases the only fish examined had severed intestines, and in another case both of two fish had the condition. More ponds would have to be sampled in order to establish the prevalence of this condition within an affected pond. Severed intestines occur infrequently; between June 1984 and November 1986, only four such cases were recorded from 3,508 cases examined at Stoneville, Mississippi.

All six cases occurred in cool to cold weather (between 12 and 19 C) (Table 1). Dissolved oxygen, unionized ammonia, and nitrite were at safe concentrations in all cases.

Aeromonas spp. were isolated from the organs of fish in all six cases. These bacteria are stress-related fish pathogens capable of causing large mortalities, but are considered also part of the normal intestinal flora of channel catfish (MacMillan, 1985). Their relationship to severed intestines is unknown.

The intestinal rupture disease in sambar deer (Bhattacharjee and Franzmann, 1986) was similar to the severed intestine condition in catfish; the edges of the rupture were hyperemic, peritonitis was present, and the rupture occurred 10 cm from the pylorus. In severe necrotizing enteropathy in larval Pacific herring (*Clupea harengus*

TABLE 1. Summary of severed intestine cases in channel catfish from Mississippi and Alabama.

	Mississippi cases						Alabama cases	
	30 November 1984	17 December 1984	11 March 1986	3 November 1986	18 November 1984	14 December 1984		
Water temperature (C)	12	17	16	19	17	17		
Clinical signs	intestine pro-lapsed out of anus peritoneal hemorrhage clear ascites in body cavity	no anal prolapse no hemorrhage body cavity normal	no anal prolapse musculature hemorrhage blood in body cavity	intestine pro-lapsed out of anus no hemorrhage body cavity normal	intestine pro-lapsed out of anus peritoneal hemorrhage blood in body cavity	no anal prolapse no hemorrhage blood in body cavity		
Fish size (cm)	46	33-46	46	33-46	33-46	NA*		
Bacteria isolated	<i>Aeromonas hydrophila</i> <i>Pseudomonas putrefactans</i>	<i>Aeromonas hydrophila</i>	<i>Aeromonas hydrophila</i>	<i>Aeromonas sobria</i> <i>Flexibacter columnaris</i>	<i>Aeromonas hydrophila</i>	<i>Aeromonas sobria</i>		
Average daily mortality	10	100	10	30	6	15		
Total mortality	100	6,000	NA*	500	12	250		
Total number of fish	85,000	180,000	NA*	100,000	39,000	NA*		

* Data not recorded.

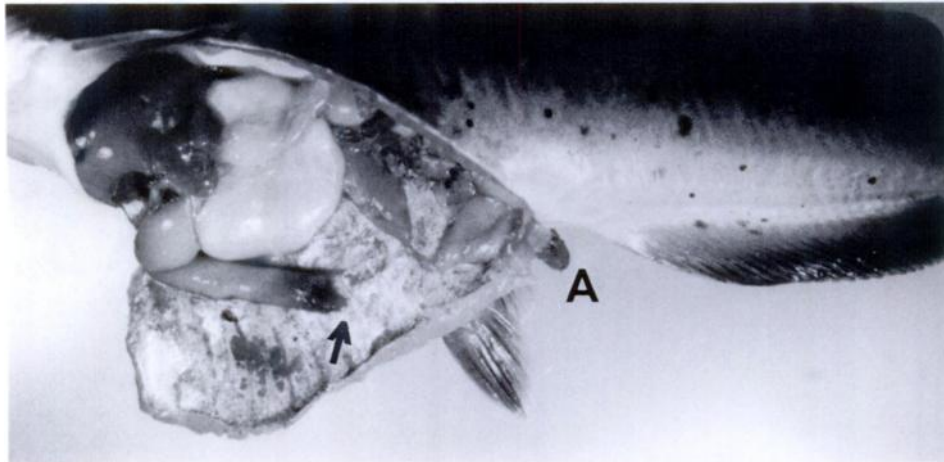


FIGURE 1. Channel catfish with a severed intestine attached to the stomach (arrow) and a section of intestine prolapsed from the anus (A).

pallasi) the disease never progressed into the stomach (Elston and Pearson, 1986), which was the case with the described catfish intestinal disorder. In the enteropathy of the herring, the disease appeared to start at the anus and progress anteriorly. This may have occurred in the catfish enteropathy since either no intestine remained in the anal area or only a small section remained and no other part of the intestine was present except for a 4–7-cm section attached to the stomach.

The etiology of channel catfish severed intestine disease cannot be determined from these preliminary observations, but several possible etiologies of similar intestinal diseases are hypothesized. Bhattacharjee and Franzmann (1986) listed possible causes for intestinal rupture including ulceration, infection, contusion (external source), parasitic inflammation, foreign body penetration, abscess, intussusception, and herniation. Tibboel et al. (1986) emphasized that fetal bowel perforation usually results from obstruction, but in cases where obstruction is absent they suggest that mesenteric ischemia is the cause. Bounous (1986) reported also that enteropathy is associated with an ischemic condition. Additionally he showed that pancreatic proteases are involved in auto-

digestion of the intestinal mucosa during ischemia, and that trypsin activates xanthine dehydrogenase in the intestine into free radicals with these free radicals damaging the mucosa after the ischemic condition terminates. Based on the occurrence of this condition in channel catfish in cool or cold weather, it is possible that cold temperature caused reduced blood flow to the intestine of catfish, subsequently predisposing the fish to mucosal damage and autodigestion. Intestinal autodigestion may have resulted also from intussusception as evidenced by the prolapsed intestine found in three of these cases.

It is possible that this condition is related to another cold weather disease of channel catfish, "winter kill." In fish with "winter kill" the external epithelium and mucus layers degenerate, leaving the fish susceptible to facultative pathogens. A similar degeneration of intestinal epithelium could leave the intestine susceptible to digestive enzymes resulting in autodigestion.

LITERATURE CITED

- BHATTACHARJEE, K. K., AND A. W. FRANZMANN. 1986. Intestinal rupture in a free-living sambar deer (*Cervus unicolor*) in India. *Journal of Wildlife Diseases* 22: 136.
- BOUNOUS, G. 1986. Pancreatic proteases and oxy-

- gen-derived free radicals in acute ischemic enteropathy. *Surgery* 99: 92-94.
- ELSTON, R. A., AND W. H. PEARSON. 1986. Idiopathic enteropathy in the larval Pacific herring, *Clupea harengus pallasii* (Valenciennes). *Journal of Wildlife Diseases* 22: 140-143.
- MACMILLAN, J. R. 1985. Infectious diseases. In *Channel catfish culture*, C. S. Tucker (ed.). Elsevier, New York, New York, pp. 405-496.
- TIBBOEL, D., J. L. J. GAILLARD, AND J. C. MOLENAAR. 1986. The importance of mesenteric vascular insufficiency in meconium peritonitis. *Human Pathology* 17: 411-416.

Received for publication 13 March 1987.