

Herpesvirus-like Infection in Black-footed Penguins (Spheniscus demersus)

Authors: Kincaid, A. L., Bunton, T. E., and Cranfield, M.

Source: Journal of Wildlife Diseases, 24(1) : 173-175

Published By: Wildlife Disease Association

URL: <https://doi.org/10.7589/0090-3558-24.1.173>

BioOne Complete (complete.BioOne.org) is a full-text database of 200 subscribed and open-access titles in the biological, ecological, and environmental sciences published by nonprofit societies, associations, museums, institutions, and presses.

Your use of this PDF, the BioOne Complete website, and all posted and associated content indicates your acceptance of BioOne's Terms of Use, available at www.bioone.org/terms-of-use.

Usage of BioOne Complete content is strictly limited to personal, educational, and non - commercial use. Commercial inquiries or rights and permissions requests should be directed to the individual publisher as copyright holder.

BioOne sees sustainable scholarly publishing as an inherently collaborative enterprise connecting authors, nonprofit publishers, academic institutions, research libraries, and research funders in the common goal of maximizing access to critical research.

Herpesvirus-like Infection in Black-footed Penguins (*Spheniscus demersus*)

A. L. Kincaid,¹ T. E. Bunton,^{1,3} and M. Cranfield,² ¹ Division of Comparative Medicine and Department of Pathology, The Johns Hopkins University School of Medicine, Baltimore, Maryland 21205, USA; ² The Baltimore Zoo, Druid Hill Park, Baltimore, Maryland 21217, USA. ³ Author to whom reprint requests should be addressed

ABSTRACT: A herpesvirus-like infection is described in the black-footed penguin (*Spheniscus demersus*). Clinically, the infection was characterized by debilitation and respiratory distress. Histopathological lesions were confined to the respiratory tract and consisted of inflammation and syncytial cell formation with Type A intranuclear inclusions in sinuses, trachea, and mainstem bronchi. Electron microscopy demonstrated polyhedral viral particles 80–140 nm in size consistent with Herpetoviridae. The lesions resembled those seen in infectious laryngotracheitis.

Key words: *Spheniscus demersus*, black-footed penguin, herpesvirus, laryngotracheitis, case report, electron microscopy.

There have been few reports of viral infections in aquatic marine birds and these infections were primarily in populations of wild birds (Stoskopf and Kennedy-Stoskopf, 1986). Although described in many species of birds including poultry, waterfowl, gamebirds, pigeons, psittacines, raptors, and wading birds (Cornwell et al.,

1967; Potgieter et al., 1979; Docherty and Henning, 1980; Biggs, 1982; Crawshaw and Boycott, 1982), herpesvirus infection has been reported only once in a marine bird, a cormorant (Biggs, 1982). This report describes a herpesvirus-like infection in two black-footed penguins (*Spheniscus demersus*) and a suspected herpesvirus infection in a third penguin.

A 9-yr-old female penguin from the Baltimore Zoo (Druid Hill Park, Baltimore, Maryland 21217, USA) was submitted for necropsy. She was 6 mo postquarantine and after laying two eggs seemed weak, pale and had a decreased appetite. The penguin was placed on prophylactic malarial treatment (Chloroquine, Biocraft Laboratories, Inc., Elmwood Park, New Jersey 07407, USA; Primaquine, Winthrop Laboratories, New York, New York 10016 USA) (Stoskopf and Beier, 1979) and antibiotics (Tribrissen, Diamond Laborato-

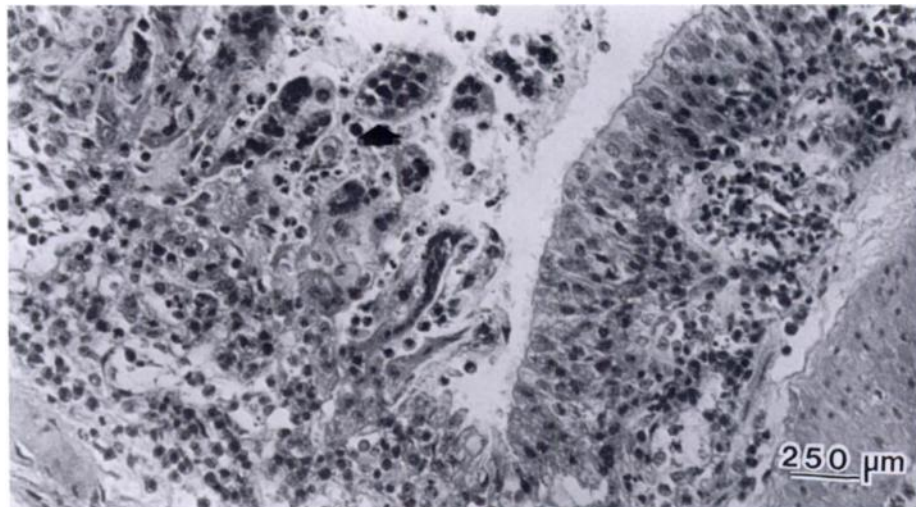


FIGURE 1. Bronchial epithelium with budding syncytial cells (arrow) in a black-footed penguin; mixed leukocyte infiltrates are seen in the submucosa and mucosa. H&E.

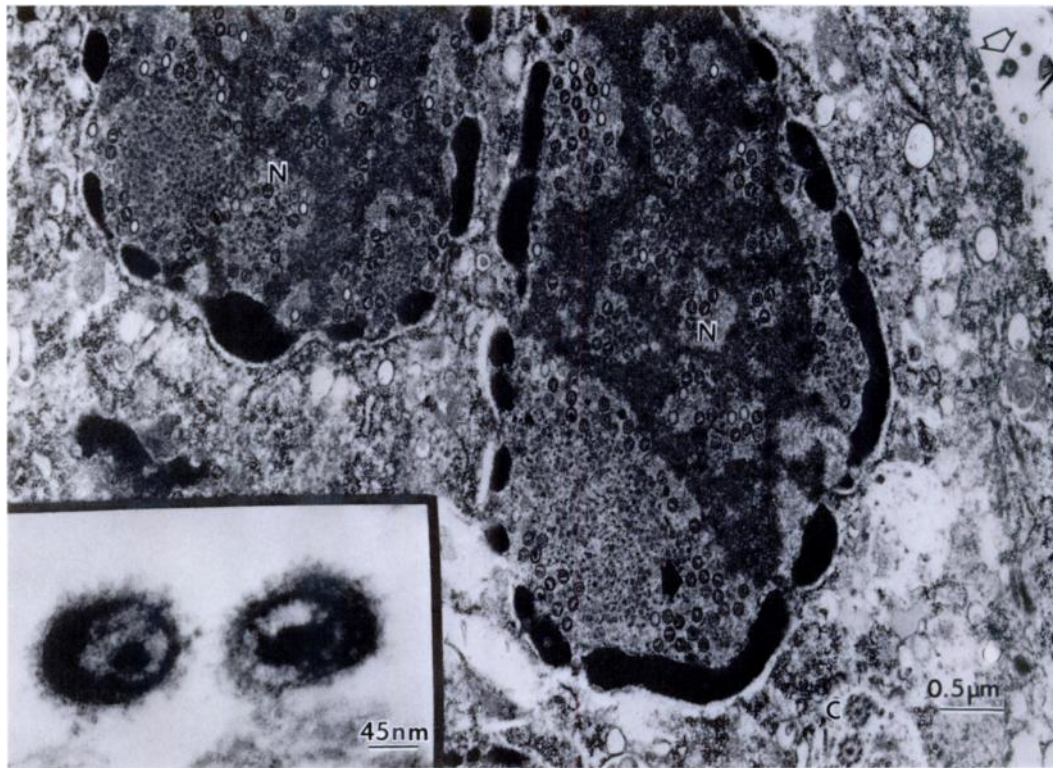


FIGURE 2. Epithelial cell nuclei (N) with intranuclear viral particles (closed arrowhead) and enveloped virions in the extracellular space (open arrowhead from a black-footed penguin); insert depicts enveloped virions.

ries, Des Moines, Iowa 50317, USA; Gentocin, Schering Corporation, Kenilworth, New Jersey 07033, USA) and placed in intensive care with oxygen. The bird refused to eat and regurgitated fish when hand fed and died 2 days after treatment began.

A 1½-mo-old male penguin was necropsied following a 9-day history of dyspnea unresponsive to antibiotics (Tribrissen and Gentocin) and antifungal agents (Amphotericin B, Squibb and Sons, Princeton, New Jersey 08540, USA). An additional 2-mo-old penguin (sex undetermined), hatched at the zoo, was submitted for necropsy prior to the female. It had a 2-day history of respiratory distress and died despite therapy.

At necropsy, the only gross findings in the older bird were a thick, tenacious, white exudate patchily distributed over the tho-

racic air sacs and diffusely reddened tracheal mucosa. Cytologically, the exudate contained mixed leukocytes and bacteria; *Streptococcus faecalis* was cultured. Impression smears of the liver, spleen and lung were negative for malarial parasites. The male chick had concretions in both lung lobes measuring 1 cm in diameter. On cut section, the concretions had a laminated appearance with multiple spiny projections from the outer surface. The mass in the right lobe had ruptured through the lung wall and caused a massive hemorrhage into the right side of the thorax. Air sacs on the left side of the thorax were cloudy with a purulent exudate. Clotted blood was present in the trachea and esophagus. Multiple bacteria were isolated from the lung including *Pasteurella multocida* and *Pseudomonas* sp. The 2-mo-old penguin had cloudy white air sacs and

very swollen pale tan kidneys. Tissues were fixed in 10% buffered formalin and preserved for histologic examination.

Microscopically, all three birds had a marked mixed cellular infiltrate consisting of granulocytes, macrophages, lymphocytes, and plasma cells in the submucosa and mucosa of the respiratory tract extending from the turbinates to the mainstem bronchi (Fig. 1). Multiple foci of necrosis and squamous metaplasia of the respiratory epithelium were seen. Syncytial giant cells in the epithelium of the adult female and male chick contained eosinophilic Type A intranuclear inclusions characteristic of herpesvirus infection (Fig. 1). Although syncytial cells were present in the air sacs and bronchi of the 2-mo-old penguin, inclusion bodies were not seen. Other lesions included tophi in the kidneys of the adult female and 2-mo-old chick, severe mycotic (*Aspergillus flavus*) granulomatous pneumonia in the 1½-mo-old male, and moderate lymphocytic and plasmacytic infiltrates in the liver, pancreas, and intestinal tract of the adult. Inclusion bodies in other organs were not seen.

Small blocks of lung tissue from two birds were routinely dehydrated, infiltrated and embedded in Araldite (Polysciences, Inc., Warrington, Pennsylvania 18976, USA), and sectioned for electron microscopy. By electron microscopy (JEOL 100S electron microscope, JEOL Limited, Tokyo, Japan), viral particles were seen in the nuclei of the respiratory syncytial and epithelial cells of the adult penguin (Fig. 2). Enveloped virions were present in the intercellular spaces. Polyhedral viral particles measured 80 nm and enveloped particles were 140 nm (Fig. 2, inset). The morphology and measurements were consistent with those of the herpetoviridae. Viral particles were not seen in cells from the 2-mo-old penguin.

The lesions in these penguins closely resembled those of infectious laryngotracheitis (LT) in poultry and other birds. This infection is characterized by a severe necrotizing laryngotracheitis and formation of a tracheal pseudomembrane. Sinusitis, bronchopneumonia and air sacculitis are seen also in LT (Russell, 1983). Penguins at the Baltimore Zoo are kept in an open air exhibit and are exposed to free-flying birds, but the exact source of the infection has not yet been determined.

This study was supported in part by NIH grants CA09393 and RR00130 and by funds from the Baltimore Zoological Society.

LITERATURE CITED

- BIGGS, P. M. 1982. The epidemiology of avian herpesvirus in veterinary medicine. *Developments in Biological and Standardization* 52: 3-11.
- CORNWELL, J. H. C., A. R. WEIR, AND E. A. C. FOLLETT. 1967. A herpes virus infection of pigeons. *Veterinary Record* 81: 267-268.
- CRAWSHAW, G. J., AND B. R. BOYCOTT. 1982. Infectious laryngotracheitis in a peafowl and pheasants. *Avian Diseases* 26: 397-401.
- DOCHERTY, D. E., AND D. J. HENNING. 1980. The isolation of a herpesvirus from captive cranes with an inclusion body disease. *Avian Diseases* 24: 278-283.
- POTGIETER, L. N. D., A. A. KOCAN, AND K. M. KOCAN. 1979. Isolation of a herpesvirus from an American kestrel with inclusion body disease. *Journal of Wildlife Diseases* 15: 143-149.
- RUSSELL, R. G. 1983. Respiratory tract lesions from infectious laryngotracheitis virus of low virulence. *Veterinary Pathology* 20: 360-369.
- STOSKOPF, M. K., AND J. BEIER. 1979. Avian malaria in African blackfooted penguins. *Journal of the American Veterinary Medical Association* 175: 944-947.
- , AND S. KENNEDY-STOSKOPF. 1986. Aquatic birds. In *Zoo and wild animal medicine*, 2nd ed., M. E. Fowler (ed.). W. B. Saunders, Philadelphia, Pennsylvania, pp. 294-313.

Received for publication 28 April 1987.