

PERIODONTAL DISEASE IN FERAL PIGS (SUS SCROFA) FROM QUEENSLAND, AUSTRALIA

Authors: Samuel, Janeen L., and Woodall, Peter F.

Source: Journal of Wildlife Diseases, 24(2) : 201-206

Published By: Wildlife Disease Association

URL: <https://doi.org/10.7589/0090-3558-24.2.201>

BioOne Complete (complete.BioOne.org) is a full-text database of 200 subscribed and open-access titles in the biological, ecological, and environmental sciences published by nonprofit societies, associations, museums, institutions, and presses.

Your use of this PDF, the BioOne Complete website, and all posted and associated content indicates your acceptance of BioOne's Terms of Use, available at www.bioone.org/terms-of-use.

Usage of BioOne Complete content is strictly limited to personal, educational, and non - commercial use. Commercial inquiries or rights and permissions requests should be directed to the individual publisher as copyright holder.

BioOne sees sustainable scholarly publishing as an inherently collaborative enterprise connecting authors, nonprofit publishers, academic institutions, research libraries, and research funders in the common goal of maximizing access to critical research.

PERIODONTAL DISEASE IN FERAL PIGS (*SUS SCROFA*) FROM QUEENSLAND, AUSTRALIA

Janeen L. Samuel¹ and Peter F. Woodall²

¹ Department of Veterinary Pathology and Public Health, University of Queensland, St. Lucia, Queensland, Australia 4067

² Department of Anatomy, University of Queensland, St. Lucia, Queensland, Australia 4067

ABSTRACT: Periodontal lesions were present in 26 of 107 feral pigs (*Sus scrofa*) that were shot in southern Queensland. The severity of the lesions varied from gingivitis to extensive destruction of the alveolus and its contents. Examination of slaughtered domestic pigs revealed a similar prevalence of lesions (12 of 52). Only cheek teeth were affected, and molars were affected more frequently than premolars. In both feral and domestic pigs, prevalence of periodontal disease affecting bone increased with age. Although periodontal disease is recognized as a common and often serious problem in many mammalian species, both domestic and wild, it has rarely been recorded in the pig. It is considered that the most severe lesions would have interfered with mastication but that the contribution of the disease to mortality of feral pigs in Australia is probably not great.

Key words: Feral pigs, *Sus scrofa*, periodontal disease, dental abnormalities, survey.

INTRODUCTION

Feral pigs (*Sus scrofa*), descended from European and possibly Asian domestic pigs, are numerous and widespread in Australia. They number well over one million, the greatest concentration being in Queensland and New South Wales, and cause considerable damage to the pastoral and agricultural industries and to native flora and fauna (Tisdell, 1982). Most of the published information on the disease status of feral pigs in Australia comes from surveys that have been directed towards their potential role in transmission of disease to domestic livestock or humans. For example, pigs have frequently been found to have lesions due to mycobacteria (Corner et al., 1981), and serological surveys have shown antibodies to arboviruses (Doherty, 1972), brucellae (Norton and Thomas, 1976), leptospires and *Coxiella burnetii* (Keast et al., 1963). Several parasitic infections have also been recorded, including sparganosis (*Spirometra erinacei*) (Gordon et al., 1954), lice (*Haematopinus suis*), ticks, sarcoptic mange (*Sarcoptes scabiei*) and kidney worms (*Stephanurus dentatus*) (Pullar, 1950; Letts, 1964). However, there are no published reports of dental or periodontal disease. Therefore, when we noticed apparently patho-

logical changes in the teeth or surrounding bone of feral pigs' skulls, we decided to conduct a survey on the prevalence of these changes. For comparative purposes we examined also the teeth of some domestic pigs, since little information was available on the dental health of these animals.

MATERIALS AND METHODS

Ninety-six heads of freshly killed pigs were obtained from abattoirs. Seventy-six heads, selected at random, were collected on a single day from an abattoir which processed game meat; these pigs were feral animals that had been shot in the field in the area around Goondiwindi (300 km southwest of Brisbane; 28°32'S, 150°18'E) and brought to Brisbane for processing. Twenty heads of domestic pigs were collected, in groups of four to six, on four different occasions from two Brisbane abattoirs. On each occasion these heads were taken from among the oldest animals in the day's kill. After an examination to assess the stage of dentition and the condition of the teeth and periodontal tissues, the heads were trimmed of flesh and cleaned in 1% sodium perborate solution. The dried skulls and mandibles were then re-examined for stage of dentition, irregularities in wear or position of teeth, and state of alveolar bone.

An additional 63 pigs' heads were examined after being cleaned and dried only, and not while fleshed. Of these, 32 were from domestic pigs slaughtered at a Brisbane abattoir and 31 were collected in a Toowoomba abattoir from feral animals which had been shot in the regions

of Goondiwindi or Mount Morgan (500 km northwest of Brisbane; 23°23'S, 150°30'E). All these heads were selected at random.

Ages of all animals were estimated from the dried skulls according to the stages of tooth eruption and replacement, using the method of Matschke (1967) for feral pigs and of St. Clair (1975) for domestic pigs. Differences in the age categories used in Table 2 occur because domestic pigs show earlier eruption of teeth, particularly of the third molars, than do feral pigs (Matschke, 1967).

Lesions were scored, according to severity, on a scale from one to three. A grading of one, which could only be assigned in the case of the 96 fresh heads, meant that lesions were confined to the soft tissues: local or generalized gingivitis characterised by discoloration and swelling, recession of the gingiva, and/or formation of pockets beside or between teeth. Reddening of the gums without other alteration was not classed as disease. Grades two and three included changes in bone, as judged from the cleaned skulls and mandibles. Recession of alveolar crests, with or without mild localized exostosis, was classed as a Grade two change (Figs. 2, 3) while Grade three applied to the more severe changes involving distortion or destruction of alveoli with exposure of tooth roots or loss of teeth (Figs. 2, 4). The presence of supragingival plaque or tartar, or the impaction of fiber between teeth, without other alteration, were not recorded as pathological changes; neither were the bony changes and gingival inflammation associated with eruption of teeth.

For comparison of the prevalence of disease in different ages and populations of pigs or at different sites along the jaws, each head or site was assigned a grading equal to that of its most severe lesion. The chi-square test was used to test significance of differences.

RESULTS

Periodontal lesions were observed in many of the heads: 26 of 107 feral pigs (24%) and 12 of 52 domestic pigs (23%). In feral pigs, most of the lesions involved bone, with 14% of animals having Grade two lesions and 8% Grade three, whereas in domestic pigs these figures were 8% and 6%, respectively. All the lesions involved cheek teeth; the incisors and canine teeth appeared normal.

Table 1 shows the distribution and severity of the lesions according to their site in the jaw, counting the most severe lesion

per animal at each site. Overall, the most common site for bony changes was the first molar. However, not all animals had erupted second and third molars. When this was taken into account there was no significant difference between the three molars in prevalence of bony lesions, but the molars were affected significantly more frequently than the premolars ($P < 0.01$). A similar distribution was seen if lesions in each jaw were counted separately instead of counting only the most severe lesion per animal. There was no difference in distribution between upper and lower jaws. The first molar was the tooth that most frequently showed signs of wear (Fig. 1). In many cases of Grade three lesions the first molar was broken, the crown having been worn away and the roots undermined (Fig. 2). In one such case there was enlargement of the body of the mandible at the level of the affected tooth. The cavities formed by erosion around the roots were usually packed with plant fiber and debris (Fig. 4). The most common site for accumulation of fiber was between the last premolar and the first molar. This was not invariably accompanied by pathological changes; however, in many cases the inflammation and recession had occurred around teeth which bore plaque or tartar, and periodontal pockets were typically filled with bacterial plaque, with or without food debris.

Table 2 shows the age distribution of the two groups of pigs, feral and domestic, and the prevalence of the various grades of periodontal lesions in the different age groups. The two groups of domestic pigs differed in their age distribution: all of those from which only dried heads were examined were under 12 mo old, whereas 19 of the 20 from which fresh heads were collected were older than 12 mo. Both groups of feral pigs included a wide distribution of ages. The prevalence of bony changes (Grades two and three) increased with age for both feral and domestic pigs, and the differences between the three age classes were significant ($P < 0.001$) for the

TABLE 1. Prevalence of periodontal lesions at different sites in feral and domestic pigs.

Most severe lesion ^a	Number of pigs examined ^b	Percentage of animals with lesions at each site ^c						
		Premolars				Molars		
		1	2	3	4	1	2	3
Feral								
Grade one	76 (60, 13)	1	0	1	4	3	0	0
Grade two	107 (85, 19)	6	7	6	9	12	12	5
Grade three	107 (85, 19)	2	2	3	4	8	5	5
Domestic								
Grade one	20 (19, 8)	5	20	30	20	10	16	13
Grade two	52 (19, 8)	4	6	4	6	10	16	25
Grade three	52 (19, 8)	0	0	2	2	6	16	13
Total								
Grade one	96 (79, 21)	2	4	7	7	4	4	5
Grade two	159 (104, 27)	5	6	5	8	11	13	11
Grade three	159 (104, 27)	1	1	3	3	8	7	7

^a Graded by severity, one to three; see text for details. Note that not all pigs were examined for soft tissue lesions (Grade one).

^b Numbers in parentheses represent numbers of pigs with erupted second and third molars, respectively; percentages affected are calculated from these figures.

^c See text for description of site of collection: "Premolar 1" indicates first premolar, etc.

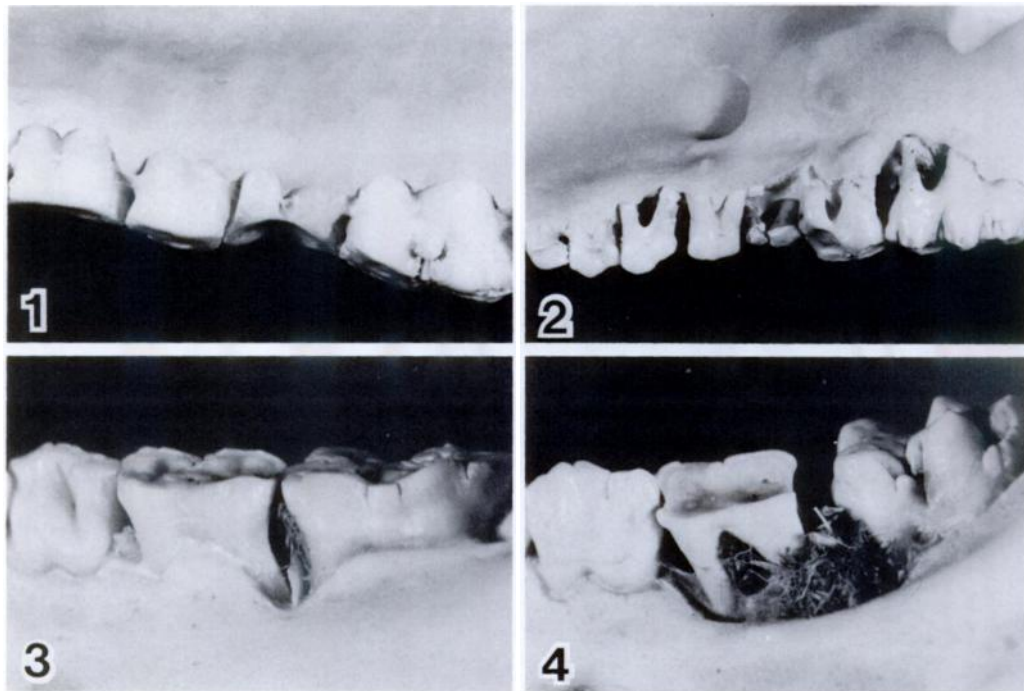
two groups of pigs combined (Table 2). There were no significant differences ($P > 0.05$) between feral and domestic pigs in prevalence of bony lesions; nor were there differences in prevalence between the two separately collected groups of feral pigs. Because soft tissue damage had not been assessed in the younger group of domestic pigs, prevalence of Grade one lesions was considered separately: in animals >12 mo old, prevalence of Grade one lesions was higher in domestic than in feral pigs, but significance could not be tested due to the small sample sizes.

DISCUSSION

Inflammatory and degenerative diseases of the periodontal tissues are common in domestic (Harvey, 1985) and in captive wild mammals (Colyer, 1936; Robinson, 1979; Amand and Tinkelman, 1985). Among free-living wild animals severe periodontal disease has been reported several times in primates (Colyer, 1936; Robinson, 1979), in marsupials of the family Macropodidae (Arundel et al., 1977; Horton and Samuel, 1978) and perhaps most frequently in ruminants including Cervi-

dae (Wobeser et al., 1975; Allen, 1979; Doerr and Dieterich, 1979) and Bovidae (Glaze et al., 1982; Vigal and Machordom, 1987). It has been reported also in feral ruminants, including reindeer (*Rangifer tarandus*) from South Georgia Island (Leader-Williams, 1982), and goats (*Capra hircus*) (Rudge, 1970), chamois (*Rupicapra rupicapra*) and several species of deer (Pekelharing, 1974) from New Zealand. However, an animal in which periodontal disease has seldom been recorded is the pig. Colyer (1936), in his comprehensive survey of dental abnormalities in animals, found few cases of disease in the Suidae of which only one, in a domestic pig, involved the periodontal tissues. Anthony (1950) considered domestic pigs to be "remarkably free" from dental diseases.

Therefore, it was a surprise to find periodontal lesions in over 20% of the pigs we examined, both feral and domestic. It was surprising also to find so little difference between the two groups of pigs, since their diets had probably been very different. Most domestic pigs in Queensland are fed commercially prepared feeds, whereas feral pigs eat a varied diet including roots,



FIGURES 1-4. 1. A worn first molar in a 18- to 20-mo-old domestic pig with no evidence of periodontal disease. 2. Periodontal disease affecting the entire upper row of cheek teeth in a 20-mo-old domestic pig. The first and second premolars show Grade two lesions and all other teeth have Grade three lesions. The crown of the first molar has been worn away. 3. Grade two lesions and some accumulation of fiber between the first and second molars of a 18- to 20-mo-old feral pig. 4. Grade three lesions at the first molar with extensive fiber accumulation in a 14- to 18-mo-old feral pig.

herbs, grasses and grain, invertebrates, small vertebrates and carrion (Tisdell, 1982). Many authors have referred to a higher prevalence of periodontal disease in captive than in wild animals, attributing this to the differing nature of the diets (Colyer, 1936; Amand and Tinkelman, 1985). Early workers believed that the disease was initiated by mechanical damage due to sharp or harsh foods (Colyer, 1936). More recent work, conducted mainly in primates, dogs and rodents, has suggested that periodontal disease is caused by the accumulation of bacterial plaque on the teeth provoking destructive responses in adjacent tissues (Page and Schroeder, 1982). Lodging of food under the gingiva, while it may exacerbate the disease, is seen as secondary to the formation of gingival pockets, and harsh food may help to pro-

tect against the disease by its abrasive action and by stimulating vigorous chewing (Amand and Tinkelman, 1985). Therefore, it might have been expected that a more varied and coarser diet in feral pigs would be conducive to greater periodontal health than that of domestic pigs, yet the only difference we found between the two groups was in prevalence of soft tissue lesions. Even here, the difference may not have been as great as it seemed; because feral pigs were slaughtered in the field and transported to Brisbane, post mortem changes sometimes made it more difficult to detect gingival lesions in these than in domestic pigs. The first molar, which is the first of the permanent cheek teeth to erupt, showed the most frequent and severe signs of wear. In a few cases involving both feral and domestic pigs, this tooth was

worn down to expose the pulp cavity and it seemed possible that infection entering by this route had initiated destruction of the alveolus and its contents. Again, it was surprising that evidence of wear was no greater in feral than in domestic pigs.

It is uncertain whether the Grade one or Grade two lesions caused the animals significant discomfort. The disease in human beings generally progresses with time unless treated; thus prevalence of severe disease increases with age (Page and Schroeder, 1982). Such a correlation with age was found in our study, and has been observed also in several species of wild ruminants (Allen, 1979; Doerr and Dieterich, 1979; Glaze et al., 1982; Vigal and Machordom, 1987). Most domestic pigs are slaughtered when young, which may explain their apparent freedom from periodontal problems. Grade three lesions may have caused considerable pain during mastication. Several animals had such lesions in all four jaws, probably interfering to some extent with their feeding. Whether this affects the animals' nutritional status would depend on the type and quantity of food available. Feral pigs were eviscerated in the field and thus it was not possible to examine the stomach contents. The presence of mandibular lesions in feral reindeer was correlated with debility and death, and Leader-Williams (1982) considered that the disease could be a significant factor in mortality of these populations. However, it is possible that such lesions have less effect on mastication in an omnivore than in a grazing animal. None of the lesions we found were sufficiently extensive to have caused illness or death other than by their effect on mastication. In some species, periodontal lesions are important because they often progress to extensive and destructive infections of the jaws and head, rapidly leading to death; the organism most frequently implicated is *Fusobacterium necrophorum*. Such disease is particularly common in macropodid marsupials (Arundel et al.,

TABLE 2. Age distribution of periodontal lesions in feral and domestic pigs.

Age class	Total sample ^a	% Prevalence of each disease grade ^b		
		1	2	3
Feral pigs				
<12 mo	22 (16)	6	0	0
12–22 mo	66 (47)	4	14	3
>22 mo	19 (13)	0	26	37
Total	107 (76)	4	13	8
Domestic pigs				
<12 mo	33 (1)	0	0	0
12–22 mo	11 (11)	27	9	0
>22 mo	8 (8)	25	38	38
Total	52 (20)	25	8	6

^a Note that in some cases sample sizes for Grade one were smaller than the total sample and these are given in parentheses.

^b Disease graded by severity from one to three. See text for details.

1977; Horton and Samuel, 1978), and has been observed often in wild cervids (Wobeser et al., 1975). Colyer (1936) reported one case of infection, with fistulation, of the body of the mandible of a domestic pig and Anthony (1950) stated that deep-seated abscesses could occur. However, it appears that such extensive lesions are rare.

Primary factors affecting mortality in feral pigs in Australia are the dingo (*Canis familiaris dingo*), drought and man (Woodall, 1983). Based on present evidence, disease seems to be only a minor factor, since Australia is free of most of the great scourges of hoofed mammals. Our findings do not indicate that periodontal disease is a major factor in mortality. Nevertheless, since the disease appears to progress with age, the pig that escapes predation may well succumb eventually to the debilitating effects of failing dental health.

ACKNOWLEDGMENTS

We wish to thank the management and staff of the abattoirs that supplied us with material: J. C. Hutton Pty. Ltd., K. R. Darling Downs; Toowoomba Municipal; Tusker (Australia) Pty. Ltd. G. Mills and G. Godbold helped with prep-

aration of the skulls and R. Williams photographed the lesions.

LITERATURE CITED

- ALLEN, D. L. 1979. Wolves of Minong. Houghton Mifflin Company, Boston, Massachusetts, 499 pp.
- AMAND, W. B., AND C. L. TINKELMAN. 1985. Oral disease in captive wild animals. In Veterinary dentistry, C. E. Harvey (ed.). W. B. Saunders Company, Philadelphia, Pennsylvania, pp. 289–311.
- ANTHONY, D. J. 1950. Diseases of the pig and its husbandry, 3rd ed. Balliere, Tindall and Cox, London, England, 309 pp.
- ARUNDEL, J. H., I. K. BARKER, AND I. BEVERIDGE. 1977. Diseases of marsupials. In The biology of marsupials, B. Stonehouse and D. Gilmore (eds.). University Park Press, Baltimore, Maryland, pp. 141–154.
- COLYER, F. 1936. Variations and diseases of the teeth of animals. John Bale, Sons and Danielsson Ltd., London, England, 750 pp.
- CORNER, L. A., R. H. BARRETT, A. W. D. LEPPER, V. LEWIS, AND C. W. PEARSON. 1981. A survey of mycobacteriosis of feral pigs in the Northern Territory. Australian Veterinary Journal 57: 537–542.
- DOERR, J. G., AND R. A. DIETERICH. 1979. Mandibular lesions in the Western Arctic caribou herd of Alaska. Journal of Wildlife Diseases 15: 309–318.
- DOHERTY, R. L. 1972. Arboviruses of Australia. Australian Veterinary Journal 8: 172–180.
- GLAZE, R. L., M. HOEFS, AND T. D. BUNCH. 1982. Aberrations of the tooth arcade and mandible in Dall's sheep from southwestern Yukon. Journal of Wildlife Diseases 18: 305–309.
- GORDON, H. MCL., B. A. FORSYTH, AND M. ROBINSON. 1954. Sparganosis in feral pigs in New South Wales. Australian Veterinary Journal 30: 135–138.
- HARVEY, C. E. (editor). 1985. Veterinary dentistry. W. B. Saunders Company, Philadelphia, Pennsylvania, 322 pp.
- HORTON, D. R., AND J. SAMUEL. 1978. Palaeopathology of a fossil macropod population. Australian Journal of Zoology 26: 279–292.
- KEAST, J. C., I. R. LITTLEJOHNS, L. C. ROWAN, AND J. S. WANNAN. 1963. The role of the feral pig as a disease reservoir. Australian Veterinary Journal 39: 99.
- LEADER-WILLIAMS, N. 1982. Relationship between a disease, host density and mortality in a free-living deer population (*Rangifer tarandus*). Journal of Animal Ecology 51: 235–240.
- LETTS, G. A. 1964. Feral animals in the Northern Territory. Australian Veterinary Journal 40: 84–88.
- MATSCHKE, G. H. 1967. Aging European wild hogs by dentition. The Journal of Wildlife Management 31: 109–113.
- NORTON, J. H., AND A. D. THOMAS. 1976. *Brucella suis* in feral pigs. Australian Veterinary Journal 52: 293–294.
- PAGE, R. C., AND H. E. SCHROEDER. 1982. Periodontitis in man and other animals: A comparative review. Karger, Basel, Switzerland, 330 pp.
- PEKELHARING, C. J. 1974. Paradental disease as a cause of tooth loss in a population of chamois (*Rupicapra rupicapra* L.) in New Zealand. Zeitschrift für Säugetierkunde 39: 250–255.
- PULLAR, E. M. 1950. The wild (feral) pigs of Australia and their role in the spread of infectious diseases. Australian Veterinary Journal 26: 99–100.
- ROBINSON, P. T. 1979. A literature review of dental pathology and aging by dental means in non-domestic animals. Journal of Zoo Animal Medicine 10: 57–65, 81–90.
- RUDGE, M. R. 1970. Dental and periodontal abnormalities in two populations of feral goats (*Capra hircus* L.) in New Zealand. New Zealand Journal of Science 13: 260–267.
- ST. CLAIR, L. E. 1975. Teeth—Porcine digestive system. In Sisson and Grossman's the anatomy of the domestic animals, 5th ed., R. Getty (ed.). W. B. Saunders and Company, Philadelphia, Pennsylvania, pp. 1268–1272.
- TISDELL, C. A. 1982. Wild pigs: Environmental pest or economic resource? Pergamon Press (Australia) Pty. Ltd., Rushcutters Bay, New South Wales, Australia, 445 pp.
- VIGAL, C. R., AND A. MACHORDOM. 1987. Dental and skull anomalies in the Spanish wild goat *Capra pyrenaica* Schinz, 1838. Zeitschrift für Säugetierkunde 52: 38–50.
- WOBESER, G., W. RUNGE, AND D. NOBLE. 1975. Necrobacillosis in deer and pronghorn antelope in Saskatchewan. Canadian Veterinary Journal 16: 3–9.
- WOODALL, P. F. 1983. Distribution and population dynamics of dingoes (*Canis familiaris*) and feral pigs (*Sus scrofa*) in Queensland, 1945–1976. Journal of Applied Ecology 20: 85–95.

Received for publication 6 August 1987.