

Larval Nematodes (*Ascarops* sp., Spirurida, Spirocercidae) in Liver Granulomata of the Western Fence Lizard, *Sceloporus occidentalis* (Iguanidae)

Authors: Stephen R. Goldberg, and Charles R. Bursey

Source: Journal of Wildlife Diseases, 24(3) : 568-571

Published By: Wildlife Disease Association

URL: <https://doi.org/10.7589/0090-3558-24.3.568>

BioOne Complete (complete.BioOne.org) is a full-text database of 200 subscribed and open-access titles in the biological, ecological, and environmental sciences published by nonprofit societies, associations, museums, institutions, and presses.

Your use of this PDF, the BioOne Complete website, and all posted and associated content indicates your acceptance of BioOne's Terms of Use, available at www.bioone.org/terms-of-use.

Usage of BioOne Complete content is strictly limited to personal, educational, and non-commercial use. Commercial inquiries or rights and permissions requests should be directed to the individual publisher as copyright holder.

BioOne sees sustainable scholarly publishing as an inherently collaborative enterprise connecting authors, nonprofit publishers, academic institutions, research libraries, and research funders in the common goal of maximizing access to critical research.

Larval Nematodes (*Ascarops* sp., Spirurida, Spirocercidae) in Liver Granulomata of the Western Fence Lizard, *Sceloporus occidentalis* (Iguanidae)

Stephen R. Goldberg¹ and Charles R. Bursey,² ¹ Department of Biology, Whittier College, Whittier, California 90608, USA; ² Department of Biology, Pennsylvania State University, Shenango Valley Campus, Sharon, Pennsylvania 16146, USA

ABSTRACT: Prevalence of larval nematodes (*Ascarops* sp., Spirurida, Spirocercidae) and associated granulomata are reported from livers of wild populations of the western fence lizard, *Sceloporus occidentalis*. Granulomata were circumscribed by layers of fibrocytes. The encysted nematode was surrounded by masses of histiocytes, cellular debris and cells with pyknotic nuclei.

Key words: Larval nematode, *Ascarops* sp., *Sceloporus occidentalis*, granuloma, pathology.

The helminth fauna of lizards from the western United States has been studied in some detail (Grundmann, 1959; Waitz, 1961; Babero and Kay, 1967; Babero and Matthias, 1967; Telford, 1970; Pearce and Tanner, 1973; Benes, 1985; Lyon, 1986; McAllister et al., 1986). Much of the information in these papers is limited to discussion of prevalence with only occasional mention of pathology. The present study was undertaken in an effort to understand the pathology resulting from chronic nematode infections in natural populations of the western fence lizard (*Sceloporus occidentalis*). We describe the occurrence and histopathology of granulomata in the livers of western fence lizards as caused by larval nematodes (*Ascarops* sp., Spirurida, Spirocercidae).

Adult western fence lizards were collected by noosing during April and May of 1986 and 1987. Juveniles were collected only in May of 1986. Two populations were studied: one was located in the San Gabriel Mountains near the junction of California highway 39 and the road to Crystal Lake, Los Angeles County, California (34°18'N, 117°50'W; elevation 1,584 m) and the second was in the Puente Hills, Whittier, Los Angeles County, California (34°01'N, 117°57'W; elevation 150 m). The habitat

of the San Gabriel Mountain population of western fence lizards consisted primarily of pine forest with a predominance of chaparral on southern exposures which is typical of the mountains of southern California. The Whittier population occupied woodpiles or canyon bottoms.

At necropsy, granulomata containing encysted nematode larvae were grossly visible as whitish nodules embedded in the liver parenchyma. Pieces of infected liver were removed and fixed in neutral buffered 10% formalin. Tissues were embedded in paraffin, sectioned at 6 μm and stained with Harris' hematoxylin and eosin. Individual nematode larvae were dissected from formalin fixed granulomata and mounted in Hoyer's solution for taxonomic identification. One specimen was deposited in the U.S. National Parasite Collection (Beltsville, Maryland 20705, USA; accession number 79821).

The granulomata were spherical structures, approximately 330 μm in diameter (range 268–395 μm). Histologically (Fig. 1), the granulomata were circumscribed by several layers of fibrocytes. There was a slight lymphocytic infiltration. This area typically contained small blood vessels in which eosinophils were sometimes present. The granulomata contained an encapsulated nematode larva. Cellular debris, cells with pyknotic nuclei and masses of histiocytes with foamy cytoplasm were frequently noted adjacent to the larva. Occasionally, two larval nematodes were noted in a granuloma.

The spirurid larva (Fig. 2) in the granulomata was third stage *Acarops* sp. Larvae were approximately 1.9 mm long by 80 μm wide. The distinguishing differen-

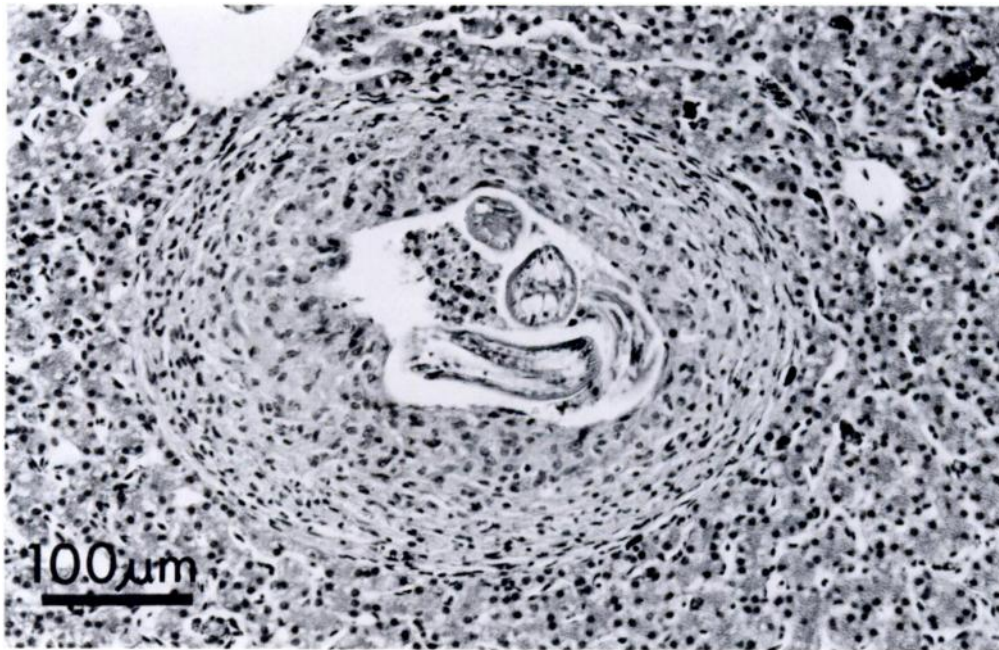


FIGURE 1. Granuloma in the liver of a western fence lizard with a larval nematode (*Ascarops* sp.) in the lumen.

tial features of the third stage larva of *Ascarops* sp. are (1) the right and left anterolateral body wall is prolonged into dorsoventral liplike projections and (2) the tip of the tail possesses a smooth knoblike process (Fig. 2). The only difference between these larvae and those of the very closely related *Physocephalus sexalatus*, is that the third stage larvae of *P. sexalatus* have a tail knob with several digitiform processes (Alicata, 1935). We have only seen smooth knobs in the nematodes taken from the liver granulomata described herein and conclude that they were consistent with *Ascarops* sp. Fourth stage or mature worms were not found.

Reproductive cycles and onset of sexual maturity of the two populations of western fence lizards examined in this study have been investigated previously (Goldberg, 1974). For adult western fence lizards from the San Gabriel Mountains (male >68 mm snout-vent length [SVL], female >66 mm SVL) the prevalence of infection was 33% in 1986 and 25% in 1987 (Table 1). Mean intensity of infection (number of granu-

lomata per animal) was 2.0 (range 1 to 5) in 1986 and 2.25 (range 1 to 5) in 1987. For adult lizards from Whittier (male >55 mm SVL, female >59 mm SVL), the prevalence was 2% in 1986 (one granuloma in one lizard) and 0% in 1987 (Table 1). The preponderance of males is due to collection of samples during the early part of the breeding season (April and May) when males defend territories and are much more aggressive and conspicuous than are females (Goldberg, 1974). In addition to the adults listed in Table 1, 25 juveniles captured in 1986 (born the previous summer) from the San Gabriel Mountains also were examined. This sample revealed a prevalence of 9% (3/35); one granuloma in each of three lizards.

The presence of the nematodes apparently did not produce illness in the infected lizards; externally, lizards with granulomata could not be distinguished from those without the lesions. All specimens appeared healthy and gross examination of gonads suggested that all adults were reproductively active.

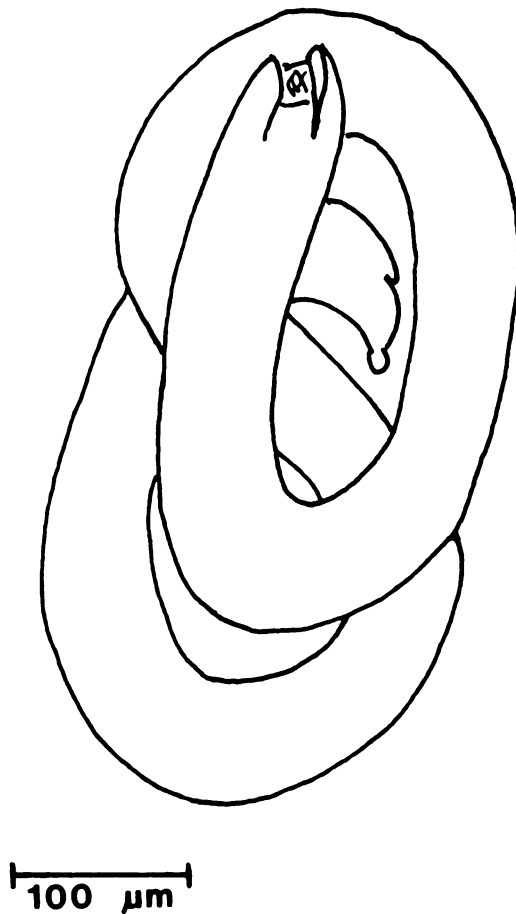


FIGURE 2. Line drawing of a recovered larval *Ascarops* sp. illustrating the cephalic projections and smooth tail knob.

Nematodes of the family Spirocercidae require two hosts. They occur as adults in the stomach of swine, rats and mice, in the esophagus of ruminants and in the crop of chickens (Olsen, 1974). Embryonated eggs containing first stage larvae are passed in the feces of the host. The eggs hatch when eaten by intermediate hosts, typically Coleoptera and Odonata (Alicata, 1935). Indeed, some 21 species from 16 genera of beetles have been identified as intermediate hosts (Porter, 1939; Fincher et al., 1969). The European dung beetle (*Aphodius fimetarius*) is a species in one of these genera and is widely distributed throughout California wherever animals are grazed (Powell and Hogue, 1979). Within the in-

TABLE 1. Prevalence of liver infection with *Ascarops* sp. in the western fence lizard.

| Popu- lation | Prevalence | | |
|------------------------------|-------------|------------|-------------|
| | Male | Female | Total |
| San Gabriel Mountains | | | |
| 1986 | 37% (19/52) | 20% (3/15) | 33% (22/67) |
| 1987 | 27% (8/30) | 0 (0/2) | 25% (8/32) |
| Whittier | | | |
| 1986 | 3% (1/38) | 0 (0/7) | 2% (1/45) |
| 1987 | 0 (0/6) | 0 (0/12) | 0 (0/81) |

termediate host, first stage larvae are enclosed in thin-wall cysts and all development to third stage larvae occurs within the cyst. Subsequent development is dependent upon the larvae reaching a suitable host. Numerous vertebrates are paratenic hosts, particularly those that habitually feed upon insects: rodents, shrews, armadillos, birds and lizards.

Since western fence lizards consume large numbers of insects (Stebbins, 1985), they presumably acquire *Ascarops* sp. through their diet. Upon digestion, a freed third stage larva migrates through the intestinal wall and re-encysts, apparently favoring liver tissue in the western fence lizard. There is no further development, although normal development could resume should a lizard be eaten by a suitable definitive host (Olsen, 1974). Western fence lizards are frequently eaten (Stebbins, 1985) by the California whipsnake, *Masticophis lateralis*. However, development of larval *Ascarops* sp. would not occur and the whipsnake would become another paratenic host. Larvae have been found to survive as long as 1 yr in mice (Olsen, 1974), but survival time in the western fence lizard has not been established.

An interesting and unexpected finding of this study was the significant difference ($\chi^2 = 114, 7 \text{ df}, P < 0.001$) in the prevalence at the two locations, with much higher prevalences occurring in the San Gabriel Mountains. These differences may be reflective of occurrences and ingestion of suitable insect intermediate hosts in the two habitats. An understanding of this

phenomenon will require investigation of the diets of the two lizard populations.

We thank J. R. Lichtenfels (Biosystematic Parasitology Laboratory, Animal Parasitology Institute) for assistance in taxonomic identification and J. O. Britt and H. J. Holshuh (Comparative Medical and Veterinary Services, County of Los Angeles) for discussions on histopathology. T. A. Bienz assisted with field work and S. Belkin helped with illustrations.

LITERATURE CITED

- ALICATA, J. E. 1935. Early developmental stages of nematodes occurring in swine. U.S. Department of Agriculture Technical Bulletin No. 489, Washington, D.C., 96 pp.
- BABERO, B. B., AND F. R. KAY. 1967. Parasites of horned toads (*Phrynosoma* spp.), with records from Nevada. *The Journal of Parasitology* 53: 168-175.
- , AND D. MATTHIAS. 1967. *Thubunaea cnemidophorus* n. sp., and other helminths from lizards, *Cnemidophorus tigris*, in Nevada and Arizona. *Transactions of the American Microscopical Society* 86: 173-177.
- BENES, E. S. 1985. Helminth parasitism in some central Arizona lizards. *Southwestern Naturalist* 30: 467-473.
- FINCHER, G. T., T. B. STEWART, AND R. DAVIS. 1969. Beetle intermediate hosts for swine spirurids in southern Georgia. *The Journal of Parasitology* 55: 355-358.
- GOLDBERG, S. R. 1974. Reproduction in mountain and lowland populations of the lizard *Sceloporus occidentalis*. *Copeia* 1974: 176-182.
- GRUNDMANN, A. W. 1959. Parasites recovered from six species of Utah lizards. *The Journal of Parasitology* 45:394.
- LYON, R. E. 1986. Helminth parasites of six lizard species from southern Idaho. *Proceedings of the Helminthological Society of Washington* 53: 291-293.
- MCALLISTER, C. T., S. E. TRAUTH, AND J. E. UBE-LAKER. 1986. Nematode parasites of the parthenogenetic whiptail lizard, *Cnemidophorus laredoensis* (Sauria: Teiidae) from south Texas. *Proceedings of the Helminthological Society of Washington* 53: 138-139.
- OLSEN, O. W. 1974. *Animal parasites: Their life cycles and ecology*. University Park Press, Baltimore, Maryland, 562 pp.
- PEARCE, R. C., AND W. W. TANNER. 1973. Helminths of *Sceloporus* lizards in the Great Basin and Upper Colorado Plateau of Utah. *Great Basin Naturalist* 33: 1-18.
- PORTER, D. A. 1939. Some new intermediate hosts of the swine stomach worms, *Ascarops strongylina* and *Physocephalus sexalatus*. *Proceedings of the Helminthological Society of Washington* 6: 79-80.
- POWELL, J. A., AND C. L. HOGUE. 1979. *California insects*. University of California Press, Berkeley, California, 388 pp.
- STEBBINS, R. C. 1985. *A field guide to western reptiles and amphibians*. Houghton-Mifflin Company, Boston, Massachusetts, 336 pp.
- TELFORD, S. R. 1970. A comparative study of endoparasitism among some southern California lizard populations. *American Midland Naturalist* 83: 516-554.
- WAITZ, J. A. 1961. Parasites of Idaho reptiles. *The Journal of Parasitology* 47: 51.

Received for publication 24 November 1987.